

# Recurrent Incisional Hernia Cases Operated with The Use of The Existing Integrated Prosthesis

Daniel Ioan Mihalache <sup>1\*</sup>, Nicolae Iordache <sup>2,3</sup>

<sup>1</sup>Department of General Surgery, Dr. Constantin Andreoiu County Emergency Hospital, Ploiesti, Romania.

<sup>2</sup>Department of General Surgery, St. Ioan Emergency Clinical Hospital, Vitan Barzesti 13 Street, 042122, Bucharest, Romania.

<sup>3</sup>Carol Davila University of Medicine and Pharmacy, Strada Dionisie Lupu 37, 020021, Bucharest, Romania.

**\*Corresponding Author:** Daniel Ioan Mihalache., Department of General Surgery, Dr. Constantin Andreoiu County Emergency Hospital, Ploiesti, Romania.

**Received date:** June 24, 2025; **Accepted date:** July 02, 2025; **Published date:** July 25, 2025

**Citation:** Daniel I. Mihalache, Nicolae Iordache, (2025), Recurrent Incisional Hernia Cases Operated with The Use of The Existing Integrated Prosthesis, *J Clinical Research and Reports*, 20(4); DOI:10.31579/2690-1919/551

**Copyright:** © 2025, Daniel Ioan Mihalache. This is an open access article distributed under the Creative Commons Attribution License, which permits unrestricted use, distribution, and reproduction in any medium, provided the original work is properly cited.

## Abstract

**Background:** Incisional hernias have a particular dynamic related both to the repair method and to the absence or presence of a prosthetic material. The incidence of incisional hernias is estimated at 9.8% after 21 months and increases to 18.7% after ten years. This study presents a surgical method for the repair of recurrent incisional hernias through open surgery and the use of existing mesh. The selection criteria for this method include: the prosthesis is well integrated, without granulomas, suppurations, or defects appearing on the same prosthetic abdominal area. The analyzed factors were the location of the incisional hernias, the duration of the operation, the duration of hospitalization, identified complications, and the size of the parietal defect.

**Material and Method:** The retrospective study focused on recurrences of incisional hernias from a group of 631 patients operated on for incisional hernias in a general surgery department of Dr. Constantin Andreoiu County Emergency Hospital, Ploiesti, Romania, during January 2018 - December 2022. Of the total 18.22% recurrences, 13.6% were relapsed eventrations after prosthetic procedures. Following the application of the selection criteria, 8 patients with recurrent eventrations were operated on using the open method with the existing mesh.

**Results:** In the case of recurrent incisional hernias, the average operation duration was 63.8 minutes, while the average hospitalization duration was 9.22 days, which is related to the fact that the activity is carried out mainly in acute medical emergencies. The monitoring of the group of patients operated on using the open method with the existing mesh was conducted over a period of up to one year, with no recurrences observed, and the disappearance of pain and swelling was noted.

**Conclusions:** In the case of recurrences after prosthetic procedures for incisional hernias, the recurrence can be resolved by open surgery using the existing well-integrated prosthesis, without tension, and with the absence of suppuration in the wound and the peritoneal cavity. For the presented case, the return to daily activities occurred after 22 hours of hospitalization.

**Keywords:** incisional hernia; recurrent eventration; existing prosthesis; selection criteria

## Abbreviations:

**IH:** Incisional Hernia

**PP:** polypropylene

## Introduction

The incisional hernia represents the externalization of a viscera covered by the parietal peritoneum, under the skin, through a muscle-aponeurotic defect. It occurs post-traumatically (rarely) or postoperatively (most frequently). Incisional hernia (IH) can be detected by clinical examination

and imaging methods. Various studies on the generation of IH have shown that there is a dynamic of the preponderance of its formation after performing abdominal surgery. The appearance of incisional hernias mainly manifests itself in the first 12 months after an operation. Over time, based on a statistical analysis of clinical data, the incidence of IH was estimated at 9.8% after 21 months, while after 10 years the incidence is 18.7%. The surgical repair of the incisional hernia has experienced a special dynamic. This was influenced on the one hand by the appearance of prosthetic materials with controlled biocompatibility, as well as

allograft fixation devices and wires. On the other hand, the advent of minimally invasive surgery (celioscopic and robotic) has expanded and refined abdominal wall repair techniques. The use of a certain operating technique in incisional hernia is a decision-making act of the specialist corroborated with the technical endowment at the time of the patient's presentation and with the data package resulting from the consultation and investigations. The state of the art in prosthetic materials has meant that most incisional hernia repairs include the use of surgical mesh. The positioning of the prosthesis about the anatomical elements of the abdominal wall added to the success of the long-term intervention and the reduction of complications (granulomas, suppurations, rejection of the mesh, fistulas of the cavity organs in contact with the mesh, etc.). The recurrence rate has decreased drastically by using prosthetic materials. Parietal defects are more common and larger after open versus minimally invasive surgery.

The objective of this study is to present the results of open surgical interventions to resolve recurrences in incisional hernia, based on the use of well-integrated surgical mesh, with good elasticity of the musculoaponeurotic tissue, and with dimensions of the parietal defect smaller than 10 cm in diameter.

## Materials and methods

The present study is a retrospective analysis conducted over a period of 5 years, from January 2018 to December 2022, within a single surgery department at the Ploiești County Emergency Hospital. Out of the total number of surgical interventions, 631 cases of incisional hernia were identified and analyzed, including recurrences of eventrations. The following inclusion and exclusion criteria were applied in this study.

### Inclusion criteria:

- The repair of the parietal defect was previously done with mesh.
- The use of the existing integrated prosthesis, with reduced parietal tension.

### Exclusion criteria:

- Cases were excluded if there was no parietal prosthesis in the patient's history or if the prosthesis was for a defect distant from the current one.

- Another exclusion criterion was the use of an additional prosthesis to cover the defect, alongside the existing one.

**Surgical technique:** Classical open surgery with the use of the existing, well-integrated mesh was employed to resolve eventration recurrences. After highlighting, opening, and dissecting the eventration sac, the parietal defect was evaluated. It was ensured that the parietal defect was in the area of the well-integrated mesh, with a mesh width of at least 5 cm contoured to the parietal defect. The edges of the defect were prepared. The tension created by approximating the edges of the defect, in the direction of the smallest diameter, was verified intraoperatively. If necessary, relaxation incisions were made. The defect was closed using well-integrated mesh with monofilament polypropylene threads. Suturing under tension is a major contraindication. The skin suture was performed with an intradermal thread.

**Post-operative monitoring:** Post-operative monitoring for all cases meeting the specific criteria of this study was challenging. It was considered that most patients return to the same hospital and service for immediate and late complications.

**Statistical analysis:** Data analysis was performed using the statistical analysis program MINITAB version 18. Continuous variables were presented as mean values accompanied by the standard deviation, while categorical variables were expressed as numbers.

## Results

### Recurrences:

In this study, based on the inclusion and exclusion criteria, 13.6% of recurrent herniations after prosthetic procedures and 4.6% after tissue procedures were identified from the studied group, resulting in a total of 18.22% recurrences (115 patients).

### Localization of Incisional Hernias:

The location of the incisional hernia operations for the 631 cases analyzed is shown in Table 1, indicating both the distribution by type of area and the ratio between men and women.

EHS Classification Zone	Number of Patients (n=631)	Percentage (%)	Men (n=165)	Women (n=466)
M1 - Epigastric	30	4.7%	8	22
M2 - Umbilical (Mesogastric)	309	48.9%	77	232
M3 - Hypogastric (Infraumbilical)	123	19.6%	36	87
M1-M3 (Combined Medial Zones)	77	12.2%	18	59
L1 - Subcostal (Hypochondrium)	15	2.4%	4	11
L2 - Flank (Lumbar)	15	2.4%	5	10
L3 - Iliac	31	4.9%	9	22
Diffuse (pangastric)	31	4.9%	8	23

**Table 1:** Location of incisional hernias according to EHS Classification

**Of this number of patients, 165 were men (26.15%) and 466 were women (73.85%), with an average age of 69 years for men and 66 years for women.**

### Duration of Operation:

From the analysis of the records regarding the duration of the operations to solve the cases, the minimum time was 20 minutes, while the maximum

time was 130 minutes. The average operating time was 63.8 minutes  $\pm$  31.16 minutes.

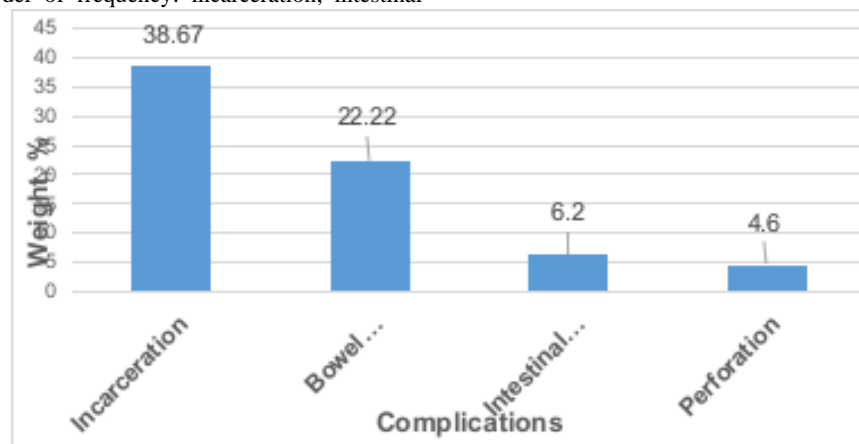
### Hospitalization Period:

The mean length of hospital stay was 9.22 days  $\pm$  3.95 days, with a minimum of 22 hours and a maximum of 24 days.

### Complications Identified:

Among the current acute complications diagnosed intraoperatively, the following were noted in order of frequency: incarceration, intestinal

occlusion, intestinal necrosis, and perforation. The proportions of these acute complications are graphically represented in Figure.1.



**Figure 1:** Weights of categories of current acute complications, identified by intraoperative diagnosis

### The size of the parietal defect:

The size of the parietal defect in incisional hernias (IH) where the presented method was used varied between 4 and 10 cm in the largest diameter, with an average value of  $6.53 \text{ cm} \pm 2.35 \text{ cm}$ . Most defects were within the range of 5-7 cm, accounting for 76% of the cases.

### Discussions

Hernia as a term indicates the presence of an abnormal protrusion of an organ or part of an organ outside the visceral cavity that contains it. The occurrence of incisional hernias negatively impacts the quality of life and socio-professional integration, leading to increased expenses in the public health system. The solution is surgical, except for contraindications. A study shows that annually more than 20 million hernias are operated worldwide. Given that the incidence of incisional hernias is on average 4.3%, while the prediction of occurrence over time using the Kaplan-Meier estimate was 9.8% for 21.1 months, the scale of this type of surgery and its social and economic impact can be identified. In another study of IH recurrence carried out for the period January 2012 - August 2022, the Kaplan-Meier analysis indicated a recurrence of 8% at 12 months in the presence of surgical mesh and 32.6% in the absence of surgical mesh, while at 2 years, recurrence was assessed at 19.7% for the group with surgical mesh and 52.4% for the group without surgical mesh. It is noteworthy that the use of prosthetic materials has become a standard procedure in both the repair of primary defects (hernias) and the repair of incisional hernias. Mesh hernia repair has thus replaced traditional defect closure techniques, contributing to an increase in the mechanical strength of the abdominal wall. The revolutionary approach of Lichtenstein et al. was the introduction of the concept of tension-free repair, impacting the surgical procedures used to repair an abdominal wall defect. Incisional hernia repair has benefited from these effective approaches, where the use of a biomaterial is almost mandatory today, leading to decreased recurrence rates.

In a recent study, it was highlighted that the two main surgical techniques, open and laparoscopic surgical repair, find their place of application in the complexity of surgical cases. In the conducted study, the evaluation of the resolution of recurrent eventration cases through open surgery using the existing mesh was aimed. In most cases of incisional hernia, the repair was done using surgical mesh. In rare cases, with parietal or

intraperitoneal suppurations, perforations, or intestinal necrosis with perforations in the sac or the peritoneal cavity, the mesh was not mounted.

In patients with recurrent herniation after a prosthetic procedure, the principle was as follows: if the prosthesis is well integrated, without granulomas or suppurations, another prosthesis was mounted in addition, or the existing prosthesis was used. Recurrence was considered when the defect appeared in the same abdominal area where the prosthesis was mounted. Thus, the following situations were considered as generative causes for relapse:

- the prosthesis was put under tension from the beginning,
- the prosthesis was fixed at the periphery in fixing points too far apart,
- net migration,
- breaking of the net.

In addition to the mentioned causes, we must also consider that some prostheses contract over time, the causes being the constructive nature of the net through the type of fabric, density, and size of the meshes, but they can also be caused by the fixing technique. Also, comorbidities that lead to increased intra-abdominal pressure contribute to such relapses, especially from the first postoperative days (chronic obstructive pulmonary disease, dysuria, constipation, etc.).

For the percentage of 13.6% of recurrent eventrations, meaning 86 patients, 9.3% of the cases were solved by using the existing prosthesis, according to the described surgical technique, with a male-to-female ratio of 1:3. The use of the existing prosthesis was done successfully, taking into account a series of criteria such as:

- absence of suppuration in the wound and the peritoneal cavity,
- the tension to which the wall and the net are subjected should not be high,
- the net must be well integrated.

For situations where the puncture occurs on the periphery of the prosthesis after the edges have been sharpened and the possible suture threads have been removed, the mesh is fixed to the wall again. The distance of at least 5 cm from the edge of the defect to the periphery of the net was respected.

The location of incisional hernias for the analyzed group of patients presents a wide spectrum, mainly in the mesogastric (48.9%) and hypogastric (19.6%) areas (see Table 1). The duration of the operation was calculated from the opening of the patient to the completion of the closure, with an average value of 63.8 minutes. The wide spectrum of duration between the limits of 20 minutes to 130 minutes is due to the specifics of the emergency hospital, where patients with acute and less often chronic complications are presented.

In the case of the parietal defect, the size of the largest diameter was located in the range of 4-10 cm, with an average value of  $6.53 \text{ cm} \pm 2.35 \text{ cm}$ . From the data analysis, a concentration of the largest diameter values was observed in the 5-7 cm range, accounting for 76%. An important role in the decision to use the existing prosthesis is the size of the defect. If the relapse occurs after a longer time, the musculoaponeurotic structures retract, not being held together, thus generating an enlargement of the defect over time.

From the perspective of age, it is found that the patients are from the older category, with the average age for men being 69 years while for women it is 66 years. In contrast, as a group dynamic by sex, the male-to-female ratio is 1:3. Monitoring for the entire group of patients was difficult to achieve, as the patients came as an emergency. For the case of recurrence of the eventration solved by the mentioned surgical technique, monitoring for 6 months to a year showed that the patients did not suffer recurrences, and the pain and swelling disappeared.

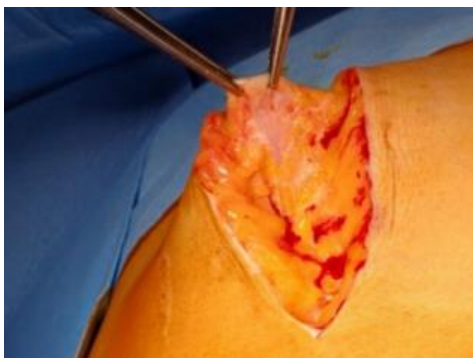### Case Study:

In what follows, a case is exemplified in which the recurrence occurred through the polypropylene mesh, at the level of the epigastrium. The defect most likely occurred by affecting the integrity and therefore the resistance of the net when it was mounted. This explains the 7 cm defect in the long axis, circumscribed all around by the well-integrated mesh. The 78-year-old patient from the countryside (physical effort) presented with painful epigastric swelling, partially reducible through taxis, through which a large hole in the musculoaponeurotic plane can be partially palpated. History of post-operative eventration: surgery with prosthesis 2 years ago (affirmative). The patient did not present the hospital discharge ticket from the previous surgical intervention.

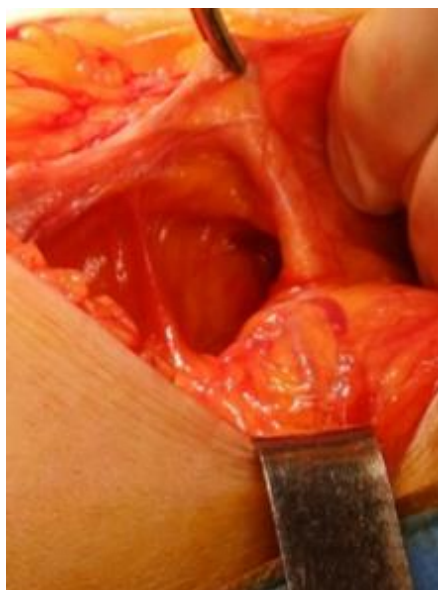Under general anesthesia with orotracheal intubation, the following procedures were performed:

- viscerolysis,
- preparation of the edges of the defect (the hole with a diameter of about 7 cm),
- suture with monofilament PP thread.

Next, figures 2-7 show the different stages of the open operation to solve the recurrence of eventration by using the existing mesh.

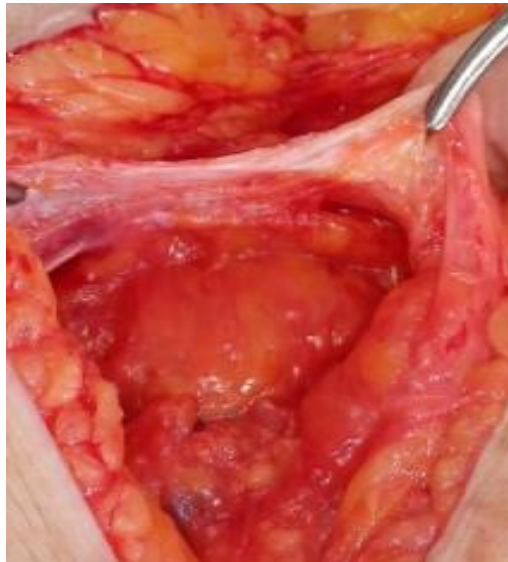

**Figure 2:** Highlighting, opening and dissection of the eventration sac

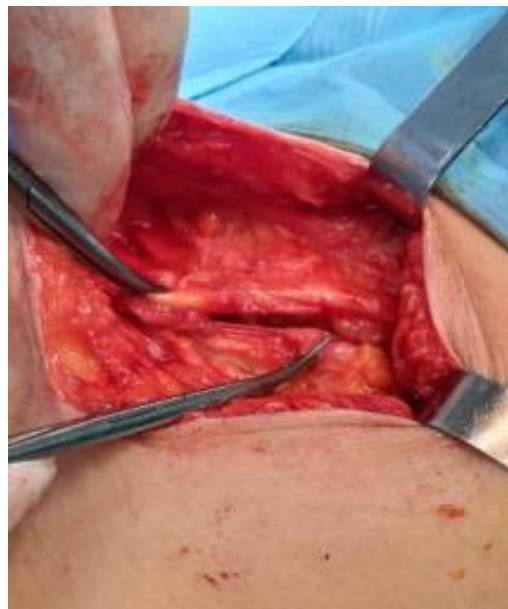

**Fig. 3:** The parietal defect formed in the area of the well-integrated mesh, with a maximum diameter of about 7 cm.

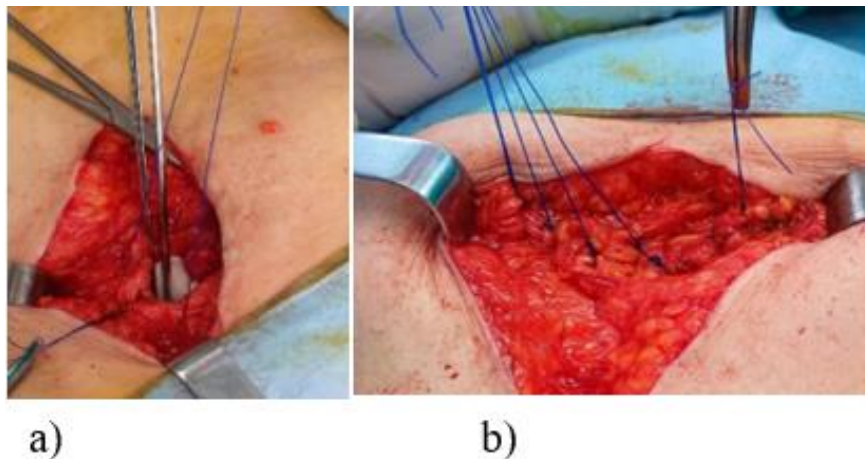




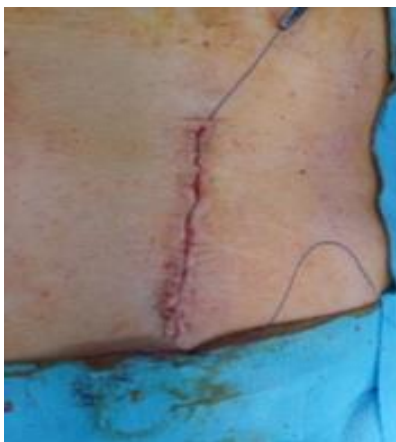**Figure 4:** Preparation of defect edges.



**Figure 5:** Intraoperative verification of the tension created by approaching the edges of the defect, on the smallest diameter.



**Figure 6:** Closure of the defect with monofilament PP threads: a) start, b) completion.



**Figure 7:** Integumentary suture with intradermal thread.

Before deciding to use the existing prosthesis, it was verified, as shown in Fig. 5, whether tension was created by closing the defect on the smallest dimension. The patient had a good recovery, being discharged 22 hours after the intervention. Postoperative monitoring for 6 months recorded the disappearance of pain and swelling.

### Conclusions

Over a five-year period from January 2018 to December 2022, an analysis of 631 incisional hernias revealed a recurrence rate of 18.22%, with 13.6% being recurrences after prosthetic procedures. Of these, 9.3% of relapses were successfully resolved through open surgery using the existing well-integrated prosthesis, without mechanical tension. Criteria for successful intervention in this type of surgery have been defined. Patients operated on using this method were monitored for 6 months to a year, showing no recurrences and a disappearance of pain and swelling.

### Author contributions

**Conceptualization:** DIM; **Software:** MFD; **Validation:** DIM, MFD; **Formal analysis:** DIM, NI; **Investigations:** DIM; **Resources:** DIM, MFD;

**Original draft:** DIM; **Writing – original draft:** DIM, MFD; **Review writing:** DIM, DMF.

All authors have read and agreed to the published version of the manuscript

**Conflict of interest:** all authors declare that there were no conflicts of interest

### References

1. Brown SR, Goodfellow PB. (2005). Transverse Verses Midline Incisions for Abdominal Surgery. *Cochrane Database Syst Rev* 2005(4):CD005199.
2. Bhaskaran A, Ambikavathy M. (2013). Incisional Hernia: A Review of Etiopathogenesis, Clinical Presentation, Complications and Management. *J Clin Biomed Sci*, 3(1):1-11.
3. Stabilini, C., Garcia-Urena, M., Berrevoet, F. et al. (2022). An evidence map and synthesis review with meta-analysis on the risk of incisional hernia in colorectal surgery with standard closure. *Hernia* 26, 411–436.s
4. Gustavo E. Muñoz Delgado\*, María A. Lastra Santiago, (2023). Review of Incisional Hernias, *International Surgery Journal* Delgado GEM et al. *Int Surg J*. 10(4):810-813
5. Heller L, Chike-Obi C, Xue AS. (2012). Abdominal wall reconstruction with mesh and components separation. *Semin Plast Surg*. 26(1):29-35.
6. Dietz UA, Menzel S, Lock J, Wiegner A., (2018). The treatment of incisional hernia. *Dtsch Arztebl Int* 115: 31–7.
7. Gábor Martis, Máté Rózsahégyi, János Deák, László Damjanovich,(2017). Incarcerated and eventrated abdominal wall hernia reconstruction with autologous double-layer dermal graft in the field of purulent peritonitis—A case report *International Journal of Surgery Case Reports* 30 126–312.
8. Howard R, Ehlers A, O'Neill S, Shao J, Englesbe M, et al. (2023). Mesh overlap for ventral hernia repair in current practice. *Surg Endosc*. 37(12):9476-9482.
9. López-Cano M, García-Alamino JM, Antoniou SA, Bennet D, Dietz UA, et al. (2018). EHS clinical guidelines on the management of the abdominal wall in the context of the open or burst abdomen. *Hernia*. 22(6):921-939.
10. Kingsnorth, A.; LeBlanc, K. Hernias., (2003). Inguinal and incisional. *Lancet* 362, 1561–1571.
11. Höer J, Lawong G, Klinge U, Schumpelick V. (2002). Einflussfaktoren der Narbenhernienentstehung. Retrospektive Untersuchung an 2.983 laparotomierten Patienten über einen Zeitraum von 10 Jahren [Factors influencing the development of incisional hernia. A retrospective study of 2,983 laparotomy patients over a period of 10 years]. *Chirurg*. 73(5):474-480.
12. Bhardwaj P, Huayllani MT, Olson MA, Janis JE. (2024). Year-Over-Year Ventral Hernia Recurrence Rates and Risk Factors. *JAMA Surg*.
13. The HerniaSurge Group. (2018). International guidelines for groin hernia management. *Hernia* 22, 1–165.
14. Lichtenstein, I.L.; Shulman, A.G. (1986). Ambulatory outpatient hernia surgery. Including a new concept, introducing tension-free repair. *Int. Surg*. 71, 1–4.
15. Lior Heller, Chuma Chike-Obi, Amy Shengnan Xue, (2012). Abdominal Wall Reconstruction with Mesh and Components Separation, *Seminars in Plastic Surgery* Vol. 26 No. 1/2012
16. Sanders, D.L.; Kingsnorth, A.N. (2011). From ancient to contemporary times: A concise history of incisional hernia repair. *Hernia* 16, 1–7.
17. Nadine van Veenendaal et al., (2023). The INCH trial: a multicenter randomized controlled trial comparing short and long term outcomes of open and laparoscopic surgery for incisional hernia repair, *Surgical Endoscopy* 37:9147–9158.

18. Lee D, Zimmern PE. (2015). Management of complications of mesh surgery. *Curr Opin Urol.* 25(4):284-291.
19. Sekmen U, Gurleyik G, Kayadibi H, Saglam A. (2009). The role of suture fixation on mesh contraction after abdominal hernia repair. *J Invest Surg.* 22(2):117-121.



This work is licensed under Creative Commons Attribution 4.0 License

To Submit Your Article Click Here: **Submit Manuscript**

DOI: [10.31579/2690-1919/551](https://doi.org/10.31579/2690-1919/551)

**Ready to submit your research? Choose Auctores and benefit from:**

- fast, convenient online submission
- rigorous peer review by experienced research in your field
- rapid publication on acceptance
- authors retain copyrights
- unique DOI for all articles
- immediate, unrestricted online access

At Auctores, research is always in progress.

Learn more <https://www.auctoresonline.org/journals/journal-of-clinical-research-and-reports>