

Generalized Tonic-Clonic Seizures in a Child Following Induction of Anaesthesia with Sevoflurane A Case Report

Vishnu Datt *, Priyanka Kaushik, Priyanka, Simran Yadav, Parth Gangwar, Utsav, Divya, Manu Gupta

Department of anaesthesiology and critical care (1) and Department of Dental sciences (2). SGT Medical college, Bhudera, Gurugram, Haryana, India.122505

***Corresponding Author:** Vishnu Datt, Professor & HOD Department of Anaesthesiology and critical care, SGT Medical College, Bhudera, Gurugram, Haryana.

Received date: May 26, 2025; **Accepted date:** May 30, 2025; **Published date:** June 05, 2025

Citation: Vishnu Datt, Priyanka Kaushik, Priyanka, Simran Yadav, Parth Gangwar, et al, (2025), Generalized Tonic-Clonic Seizures in a Child Following Induction of Anaesthesia with Sevoflurane A Case Report, *J New Medical Innovations and Research*, 6(6); DOI:10.31579/2767-7370/167

Copyright: © 2025, Vishnu Datt. This is an open access article distributed under the Creative Commons Attribution License, which permits unrestricted use, distribution, and reproduction in any medium, provided the original work is properly cited.

Abstract:

Seizures during general anaesthesia in children are rare, and most anaesthetics are considered safe. However, some general anaesthetics and drugs used during anaesthesia possess pro-convulsant properties that may trigger generalized tonic-clonic seizures (TCS) at induction or emergence from anaesthesia. Seizures have been described with sevoflurane, isoflurane, etomidate, local anaesthetics, opioids, propofol, as well as other anaesthetics and auxiliary drugs. Sevoflurane-induced seizures are most often caused by high concentrations of sevoflurane combined with alveolar hyperventilation during mask induction of anaesthesia, and certain factors can increase the risk, especially in children with a history of epilepsy or other neurological conditions. While seizures can occur, they are usually manageable. Early recognition and appropriate management of seizures are crucial to prevent adverse outcomes. We are here reporting a case of an apparently healthy 5-year-old male child posted for palatoplasty under general anaesthesia after obtaining informed consent from the parents, who developed generalized TCS during induction of anaesthesia with 8% sevoflurane. However, the postoperative course was normal without any neurological complications.

Keywords: cleft palate; general anaesthesia; midazolam; seizure; sevoflurane

Introduction

A tonic-clonic seizure (TCS) under anaesthesia is rare but can occur, particularly during or after the administration of certain anaesthetic agents. Seizures have been reported to be precipitated by several intravenous and inhalational anaesthetic agents like etomidate, ketamine, morphine, meperidine, fentanyl, sufentanil, and Sevoflurane and enflurane in the presence of hypoxapnia. [1,2]

In addition to anaesthetic agents, other factors can contribute to perioperative seizures such as metabolic imbalances, hyperpyrexia, electrolyte abnormalities, or underlying neurological conditions. Sevoflurane has been widely used in general anaesthesia but produces epileptiform EEG discharges during anaesthesia in children. Sevoflurane-induced seizures most often result from the use of high concentrations during mask induction of anaesthesia.[3,4,5] The early recognition and appropriate management of seizures are crucial to prevent adverse outcomes in these patients.[5] Perioperative seizures have been managed by deepening the level of anaesthesia, and administration of thiopentone, propofol, midazolam, phenytoin, and muscle relaxant.[5,6] We are here reporting a 5-year-old male child with a cleft palate, without any previous history of seizures posted for palatoplasty, who developed generalized Tonic-Clonic seizures during inhalational induction of anaesthesia with Sevoflurane (8%). There were symmetrical generalized Tonic Clonic seizure movements involving the upper and lower extremities for at least 45 seconds. Finally, the seizures ceased after the administration of

midazolam, propofol, fentanyl, atracurium and after switching off the sevoflurane. The palatoplasty was performed as planned, and there were no postoperative problems.

Case Presentation

A 5-year-old- male child, weighing 12.5kg, previously healthy presented with complete bilateral cleft palate scheduled for bardach's two- flap palatoplasty surgical repair. His birth history is suggestive of normal-term vaginal delivery, with an immediate cry, and all milestones were achieved on time. He has been fully immunized as he received all due vaccines as per the national immunization schedule within 1st year age of the child. He did not have any significant clinical history including convulsions, drug allergy, jaundice, or cyanosis. However, there is a history of cheiloplasty one year back under general anaesthesia, and the intraoperative and postoperative course was uneventful. The patient did not show any features of other congenital syndromes, known to be commonly associated with cleft palate. On examination his heart rate was 140bpm, blood pressure was 112/70mmHg. Oral cavity examination revealed a complete cleft palate and normal-appearing post-repair lips. [Figure 1]. Auscultation of the chest and heart revealed normal air entry and normal S1 and S2 heart sounds. His HB was 13.5gm/dl, total leucocyte count was 10160 cells/cumm and other haematological and biochemical values were also within normal limits. Chest X-ray revealed clear lung fields and normal cardiac size but noted a wide superior

mediastinum due to a large mediastinum shadow. ECG showed non-specific widespread T-wave abnormalities. 2-D echocardiography study was also normal with good biventricular functions. Detailed informed consent was obtained from the parents, along with permission for displaying the photographs of the child for teaching the students as well

as for publication. He was posted for the cleft palate repair under the smile train scheme; the world's largest cleft-focused organization, that provides **100%-free cleft surgery** and other comprehensive cleft care to children globally.

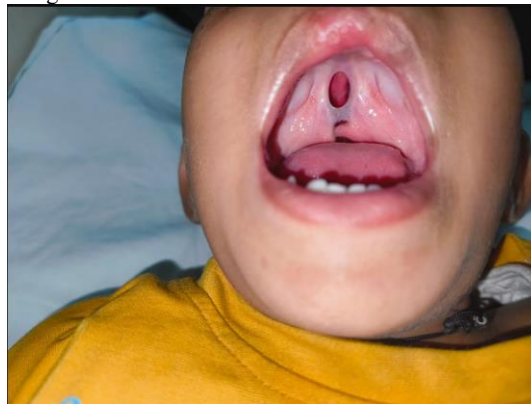

Figure 1: Preoperative photograph of the oral cavity confirms the diagnosis of a complete cleft palate defect.

In The OR, standard ASA monitoring (ECG, SPO₂, NIBP, capnography and temperature) was attached. The baseline SPO₂ -99%, HR- 144 bpm and BP- 112/74 mmHg were recorded. Inhalational induction of anaesthesia was initiated with sevoflurane (8%), however, the child developed generalized TCS approximately two minutes after starting the sevoflurane inhalation and persisted at least for 45 seconds, when he was hyperventilating. The intravenous line was secured with 22G cannula. The administration of intravenous midazolam (1 mg), propofol 10mg and atracurium(7mg) lead to abrupt control of the seizures.[6] The airway was secured with south-facing RAE, 4.5 mm. ID, endotracheal cuff tube, fixed at 14 cm mark and bilateral air entry was confirmed, and mechanical ventilation was started using volume control mode, tidal volume 100ml and rate 22 breaths per minute with an FIO₂ of 60% using oxygen in the air. Oropharynx was packed with wet roll gauze to prevent aspiration of blood or other debris and to keep the endotracheal tube in the center.

Anaesthesia was maintained with sevoflurane 1 MAC, fentanyl 20mcg, propofol, and intermittent atracurium, and intravenous paracetamol 20 mg/kg as part of a multimodal pain management strategy in cleft palate surgery. [2,7] Perioperative Arterial oxygen saturation was 99-100%, ETCO₂ was 30-35 mmHg, and BP was maintained between 90- 120/ 50- 60 mmHg. Palatoplasty was performed using the V-Y technique. [Figure 2] Total duration of surgery was 90min and total blood loss was 30-40 ml. Atracurium neuromuscular block was reversed with a mixture of neostigmine 0.75 mg and glycopyrrolate 0.2mg. [8] The throat pack was removed after confirmation of adequate haemostasis and smoothly extubated. The child made a smooth recovery and regained full consciousness, maintaining SPO₂ of 99-100% on room air in the right lateral position. The rest of the course was uneventful without any episode of seizures, and the child was discharged on the 2nd postoperative day with some advice to attend the OPD for the follow-up.

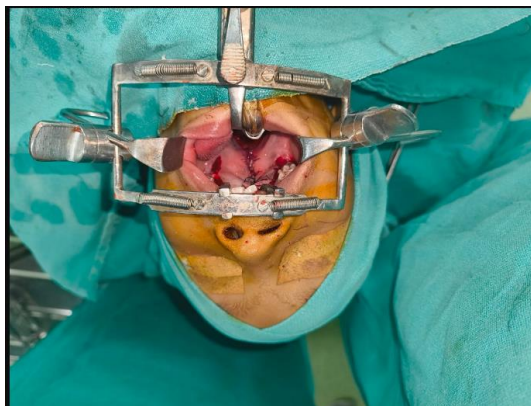


Figure 2: Intraoperative photograph of the oral cavity following V-Y repair of the cleft palate. Note that the patient is still having a south pole endotracheal tube in situ.

Discussion:

Generalized TCS under anaesthesia are rare but they have been reported, particularly during induction of anaesthesia, intraoperatively or even during emergence from the anaesthesia in patients with known epilepsy or even in the previously seizure-free.[5] The etiology of the seizures in children and adults is highly variable including hyperpyrexia above 38°C, hypercyanotic spells, hyperviscosity syndrome, hyponatremia, hypoglycaemia, thyroid storm, eclampsia and intracranial lesions.[9,10,11,12] Generalised seizures have been reported to be precipitated by several intravenous and inhalational anaesthetic agents

like etomidate, ketamine, morphine, meperidine, fentanyl, sufentanil and enflurane and, Sevoflurane in the presence of hypocapnia.[1,2] Propofol in small doses also causes epileptogenic changes in the EEG, but in anaesthetic doses, it suppresses EEG activity.[6]

Sevoflurane can sometimes trigger seizures, especially at higher concentrations. There are multiple case reports of sevoflurane-provoking seizure-like activity, particularly in children and when high concentrations are used in conjunction with hypocapnia as a result of alveolar hyperventilation during mask ventilation.[3,4,13,14,15,16] The incidence of epileptiform EEG events in children during sevoflurane

anaesthesia varied from 19.1%-59.2%.[17] The mechanism of sevoflurane-provoked seizures is via the γ -aminobutyric acid-mediated receptors induced interictal epileptiform discharges or seizures in children.[18] The presented child also developed generalized TCS during the induction of anaesthesia with higher doses of sevoflurane(8%). Jheng J and colleagues have reported seizure-like movements in a child with a history of epilepsy even due to residual sevoflurane inside an anaesthesia machine after pre-oxygenation during rapid sequence anaesthesia induction. However, the convulsions ceased spontaneously without treatment following the washout of the residual sevoflurane with the oxygen flow of 10L/min and the postoperative course was also normal.[19] Though our patient developed TCS during induction of anaesthesia with 8% sevoflurane, others have reported that even 1.75 surgical minimal alveolar concentration (MAC) of sevoflurane in 100% oxygen can precipitate major seizures.[20] Similar to our patient J Akeson and colleagues have also reported generalized TCS in two patients during induction of anaesthesia up to 6% of sevoflurane and they have suggested that administration of midazolam, thiopentone, and fentanyl attenuates the EEG seizure activity.[5] Whereas some authors have reported that the frequency of seizures is not influenced by the type of anaesthesia or procedure in patients with a history of seizure disorder.[21] Additionally, other factors such as hypoxia, hypercarbia, and ischemia can also contribute to seizures. Changes in antiepileptic drug therapy, missed doses, or the introduction of new medications can disrupt seizure control and increase the risk of perioperative seizures.

Use of the anaesthesia techniques that minimize seizure risk is imperative, particularly in patients previously seizure-free. One should be aware of the pro-convulsive effects of certain anaesthetic agents like sevoflurane, meperidine, fentanyl etc. General anaesthesia can precipitate the seizures or may be necessary to treat refractory status epilepticus. In the presented patient the use of midazolam(1mg), fentanyl (20 mcg), propofol 10mg and atracurium (7mg) resulted in the immediate control of the seizures, and the repeat episode was not witnessed either in intraoperative or during postoperative period.[2,7] Anaesthetic agents with epileptogenic potential (e.g. ketamine and alfentanil), and those with epileptogenic metabolites (e.g. meperidine), should be avoided.[2,22] Some authors have suggested that the addition of ketamine 0.25 mg/kg can decrease the incidence of emergence agitation in children after sevoflurane general anaesthesia.[23] The children, who develop sevoflurane-induced seizures don't require antiepileptic drugs, such as carbamazepine, phenytoin, phenobarbital, and primidone in the postoperative period. However, the use of sevoflurane in children, with its remarkable cardiovascular profile, should include several precautions and be more vigilant. Among them, the limitation of the concentration and depth of anaesthesia is most vital. If possible, the use of cerebral function monitoring like EEG may allow optimization of sevoflurane dose and avoidance of burst suppression and major epileptiform signs in potential subjects, notably the very young and the very old.[16] Analogous to our case, most previous reports of seizure-like activity during sevoflurane were characterized by symmetrical tonic-clonic motor activity, and no serious neurological adverse effects were found in the postoperative period. However, for uncontrolled seizures treatment with midazolam, thiopentone and propofol is accepted, and even ketamine has been found to be beneficial in the management of status epilepticus refractory to the other agents, whereas opioids should be avoided.[2]

Conclusion

Perioperative seizures can be a serious complication, but they are often treatable. Inhalational induction of Anaesthesia with a higher concentration of sevoflurane (8%) can precipitate the generalized TCS even in a previously seizure-free child. If a seizure occurs, prompt treatment with midazolam, thiopentone, propofol and muscle relaxant and mechanical ventilation is crucial and is sufficient to control the seizure, and additional antiepileptic therapy is not usually required in postoperative period. Sevoflurane-induced seizure activity does not

produce any residual effects and the child regains full spontaneous recovery following reversal of neuromuscular block like any child of palatoplasty.

Declaration of patient consent

The authors certify that they have obtained informed consent from the parents including the agreement with the use of details of the child for teaching and publication, but without the name and identification of the child.

Conflicts of interest

There are no conflicts of interest.

References

1. Larkin CM, O'Brien DF, Maheshwari D. (2019). Anaesthesia for epilepsy surgery. *BJA Educ.* 19(12):383-389
2. A. Perks1*, S. Cheema3 and R. Mohanraj2. (2012). Anaesthesia and epilepsy. *British Journal of Anaesthesia*, Volume 108, Issue 4, 562-571.
3. Smith DA, Bath J. (2016). Epileptiform activity during induction of anaesthesia with sevoflurane prior to elective carotid endarterectomy. *Vascular.* 24:96-99
4. Cornelissen L, Donado C, Lee JM, et al. (2018). Clinical signs and electroencephalographic patterns of emergence from sevoflurane anaesthesia in children: an observational study. *Eur J Anaesthesiol.* 35:49-59
5. Akeson J, Didriksson I. (2004). Convulsions on anaesthetic induction with sevoflurane in young children. *Acta Anaesthesiol Scand.* Apr;48(4):405-407
6. Ahmed R. Barakat, Su Mallory. (2011). Anaesthesia and childhood epilepsy, *Continuing Education in Anaesthesia Critical Care & Pain.* June, Volume 11, Issue 3, Pages 93-98
7. Suleiman NN, Luedi MM, Joshi G, Dewinter G, et al. (2024) PROSPECT Working Group. Perioperative pain management for cleft palate surgery: a systematic review and procedure-specific postoperative pain management (PROSPECT) recommendations. *Reg Anesth Pain Med.* Sep 2;49(9):635-641
8. Hunter JM. (2020). Reversal of neuromuscular block. *BJA Education*, Volume 20, Issue 8, 259-265
9. Nardone R, Brigo F, Trinko E. (2016). Acute Symptomatic Seizures Caused by Electrolyte Disturbances. *J Clin Neurol.* Jan;12(1):21-33.
10. Lee HG, Bae HB, Choi JI, Pyeon T, Kim S, Kim J. (2019). Febrile convulsions during recovery after anaesthesia in an infant with history of MMR vaccination: A case report. *Medicine (Baltimore).* Aug;98(35):17047
11. Brickner ME, Hillis LD, Lange RA. (2000). Congenital heart disease in adults. Second of two parts. *N Engl J Med.* Feb 03;342(5):334-342
12. O'Brien P, Marshall AC. (2014). Cardiology patient page. Tetralogy of Fallot. *Circulation.* Jul 22;130(4):26-29
13. Constant I, Seeman R, Murat I. (2005). Sevoflurane and epileptiform EEG changes. *Paediatr Anaesth.* Apr;15(4):266-274
14. Mohanram A, Kumar V, Iqbal Z, Markan S, et al. (2007). Repetitive generalized seizure-like activity during emergence from sevoflurane anaesthesia. *Can J Anaesth.* Aug;54(8):657-661
15. Orihara A, Hara K, Hara S, et al. (2020). Effects of sevoflurane anaesthesia on intraoperative high-frequency oscillations in patients with temporal lobe epilepsy. *Seizure.* 82:44-49.
16. de Heer IJ, Bouman SJM, Weber F, et al. (2019). (EEG) density spectral array monitoring in children during sevoflurane anaesthesia: a prospective observational study. *Anaesthesia.* 74:45-50.

17. Mengrong Miao a 1, Yaqian Han a 1, Ying Zhang b, Yuehua Xu a, et al. (2022). Seizures are more common in infants under one year. Epileptiform EEG discharges during sevoflurane anaesthesia in children: A meta-analysis. Clinical Neurophysiology. Volume 143, November 2, Pages 48-55
18. Chao JY, Legatt AD, Yozawitz EG, et al. (2020). Electroencephalographic findings and clinical behavior during induction of anaesthesia with sevoflurane in human infants: a prospective observational study. Anesth Analg.130:161-164
19. Zheng J, Du L, Zhang L. (2021). Seizure-like movements caused by residual sevoflurane inside the anaesthesia machine: A case report. Medicine (Baltimore). Jan 29;100(4):e24495
20. Gibert S, Sabourdin N, Louvet N, et al. (2012) Epileptogenic effect of sevoflurane: determination of the minimal alveolar concentration of sevoflurane associated with major epileptoid signs in children. Anesthesiology.117:1253-1261.
21. Niesen AD, Jacob AK, Aho LE, Botten EJ,et al. (2010). Nase KE, Nelson JM, Kopp SL. Perioperative seizures in patients with a history of a seizure disorder. Anesth Analg. Sep;111(3):729-735
22. Alix Zuleta-Alarcon, Karina Castellon-Larios, Kenneth R Moran, Suren Soghomonyan et al. (2014). Anaesthesia Related Perioperative Seizures: pathophysiology, Predisposing Factors and Practical Recommendations. Journal of Anaesthesia and Analgesia. 2(4):1026-1034
23. Ibrahim Abu-Shahwan, Chowdary. (2007). Ketamine is effective in decreasing the incidence of emergence agitation in children undergoing dental repair under sevoflurane general anaesthesia. Pediatric Anaesthesia. October 17(9):846-850



This work is licensed under Creative Commons Attribution 4.0 License

To Submit Your Article Click Here:

Submit Manuscript

DOI:10.31579/2767-7370/167

Ready to submit your research? Choose Auctores and benefit from:

- fast, convenient online submission
- rigorous peer review by experienced research in your field
- rapid publication on acceptance
- authors retain copyrights
- unique DOI for all articles
- immediate, unrestricted online access

At Auctores, research is always in progress.

Learn more at: <https://auctoresonline.org/journals/new-medical-innovations-and-research>