

# Rheumatic Mineralization of Heart Valves and Its Therapeutics

Ramachandran Muthiah

President of all nations Morning star hospital, Enayam Thoppu, Kanyakumari District, Tamil nadu state, India.

**\*Corresponding Author:** Ramachandran Muthiah., President of all nations Morning star hospital, Enayam Thoppu, Kanyakumari District, Tamil nadu state, India.

**Received Date:** May 05, 2024; **Accepted Date:** May 16, 2024; **Published Date:** May 28, 2024

**Citation:** Ramachandran Muthiah, (2025), Rheumatic Mineralization of Heart Valves and Its Therapeutics, *Clinical Medical Reviews and Reports*, 7(3); DOI:10.31579/2690-8794/286

**Copyright:** © 2025, Ramachandran Muthiah. This is an open access article distributed under the Creative Commons Attribution License, which permits unrestricted use, distribution, and reproduction in any medium, provided the original work is properly cited.

## Abstract

**Aim:** To present the heterotopic ossification of left-sided heart valves due to rheumatic inflammation and biomineralization. Introduction: Calcification in the region of mitral-aortic continuity is significant at its origin and etiopathogenesis. The etiology of valvular calcification may be divided into 3 groups, namely, inflammation, degeneration and metabolic disturbances. Calcification of cardiac valve leaflets is most often due to rheumatic etiology in tropical nations.

**Case Report:** A 52-year-old male developed sudden onset of light-headedness and palpitations due to atrial fibrillation. Transthoracic 2D echocardiography revealed calcification of anterior mitral leaflet and aortic valve which resembles a bone-like structure and the patient was advised double valve replacement.

**Conclusion:** It was known that the cellular mechanisms play an important role in its genesis and therapeutic strategies are targeted to reverse this process by understanding its biological mediators.

**Keywords:** rheumatic mineralization; mitral-aortic “j-shaped” calcification; “mushroom shaped” calcified bicuspid aortic valve; hutchinson-gilford progeria syndrome; therapeutic strategies

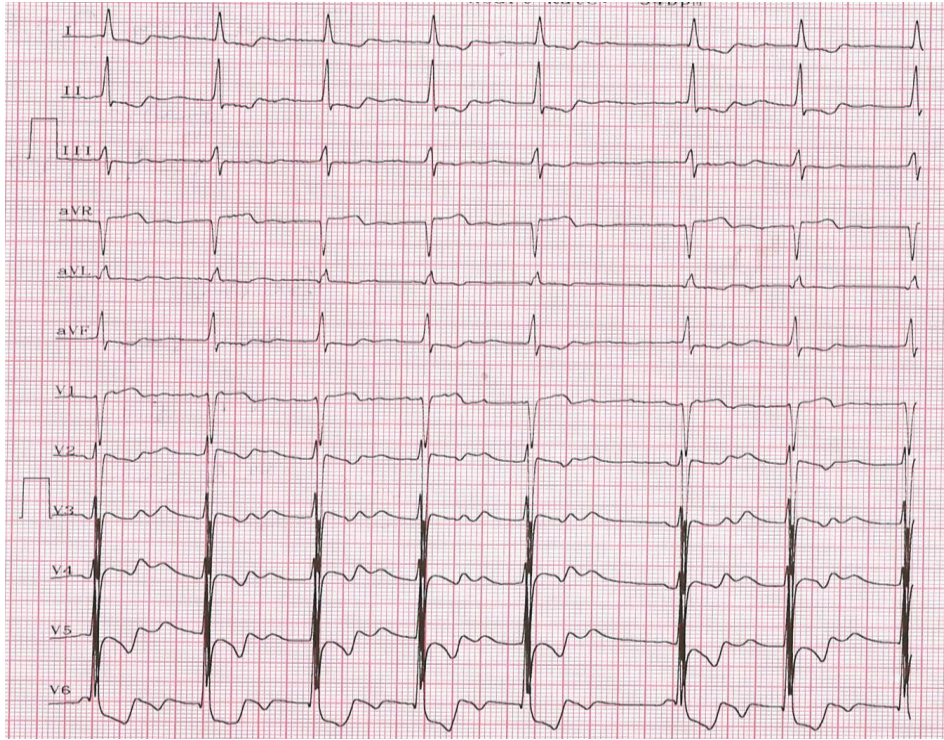
## 1. Introduction

A calcified valve is the hardening of the valve due to the deposition of calcium salts at the site of wear-and-tear and damage. It is important to remember that any valve can become calcified. However, calcification is more likely to affect the valves on the left side of the heart (mitral and aortic valves) since they experience greater pressure, more wear-and-tear damage with increased risk of deposition of calcium phosphate salts, known as dystrophic calcification. This senile valve calcification occurs on the mitral valve at the age of 50-70 years and on the aortic valve at 70-90 years of age. Calcification can occur earlier in life when associated with rheumatic heart disease and heavy calcification was seen in severely damaged valves by the rheumatic process. Since the disease process is complex and involves several different cell types, it is important to understand the cellular and matrix architecture of a normal heart valve. The valve endothelial cells (VECs) line the outer surface of the valve and maintain homeostasis by regulating permeability, paracrine signaling and function as a barrier to limit inflammatory cell infiltration and lipid accumulation. The valve interstitial cells (VICs) are the predominant cell type within the fibrosa, spongiosa and ventricularis layers of the valve and secrete extracellular matrix, including collagen, elastin, and glycosaminoglycan. The fibrosa consists of fibroblasts, circumferentially arranged fibrillar collagen fibers (type I and type III) and serves a load-bearing function. The spongiosa is predominantly found at the

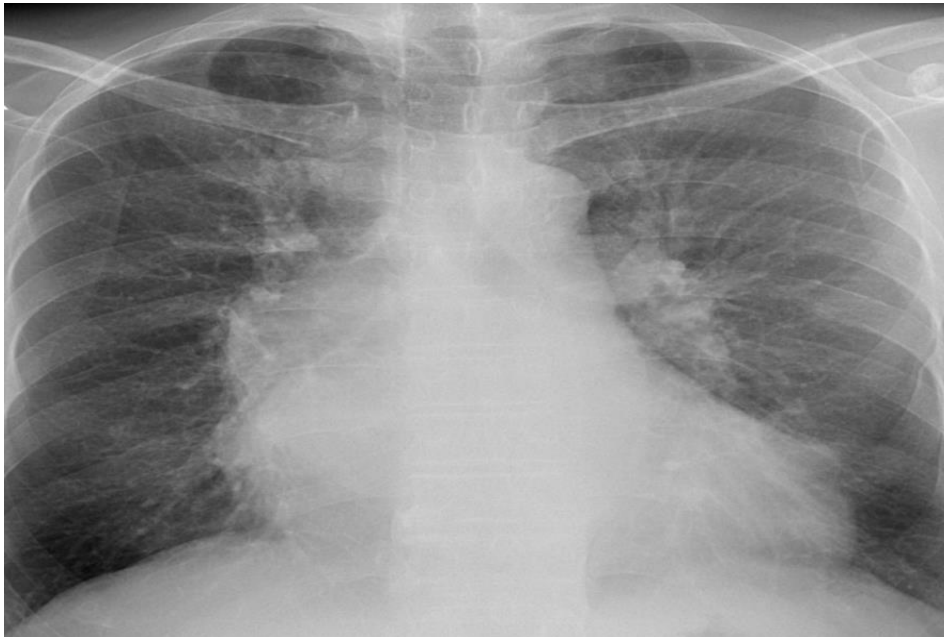base of the leaflet and it is a layer of loose connective tissue containing mesenchymal cells, fibroblasts, mucopolysaccharides and it resist the compressive forces within the cusps. Ventricularis contain elastin fibers, oriented perpendicularly to the collagen and it reduces the radial strain. The normal aortic valve is made up of 3 cusps and its arrangement results in even distribution of mechanical stress to the valve ring and the aorta [1]. At their base, the valve leaflets are attached to a dense collagenous network, called the annulus, which facilitate their attachment to the aortic root and the dissipation of mechanical force. The anterior mitral leaflet is in direct continuity with left half of non-coronary cusp and the adjacent third of left coronary cusp. The mitral-aortic intervalvular fibrosa is the junctional tissue between the elements of mitral and aortic valves, called as mitral-aortic membrane or curtain. It is relatively avascular and offers little resistance to infection [2]. Historically, calcification of valves has been attributed to prolonged ‘wear and tear’ and age-related valvular degeneration, and recent evidence suggests that it is the result of active inflammatory process [3] leading to osteogenesis by involving biochemical, humoral and genetic factors. The mechanism of valvular calcification is similar to skeletal bone formation and it is the most common manifestation of rheumatic heart disease. The anterior mitral leaflet - aortic cusp continuity region was

particularly affected by this mineralization process and so this case had been reported.

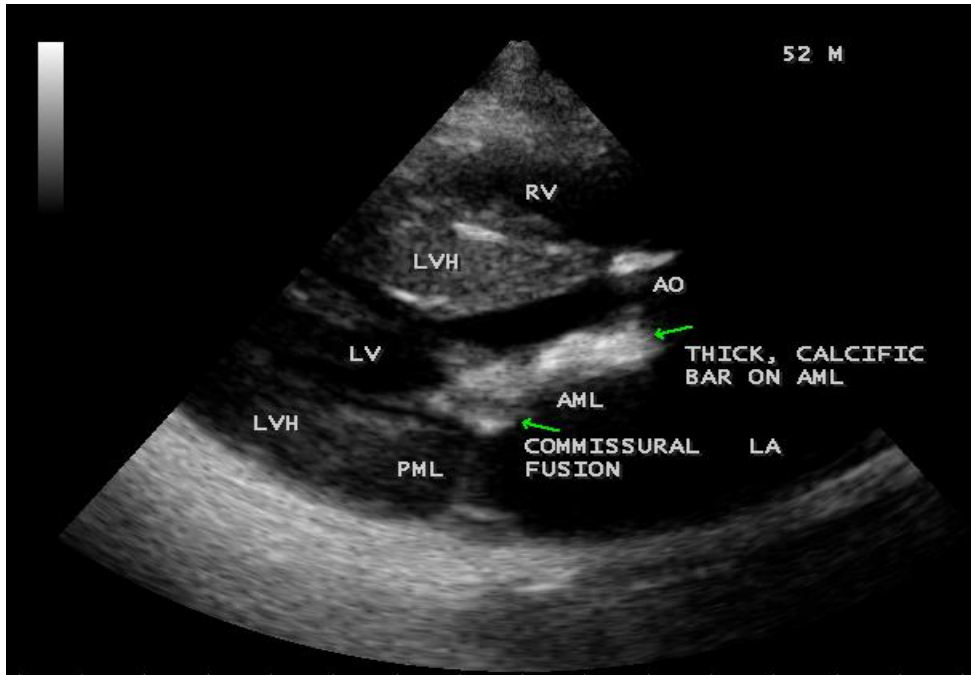
## 2. Case Report



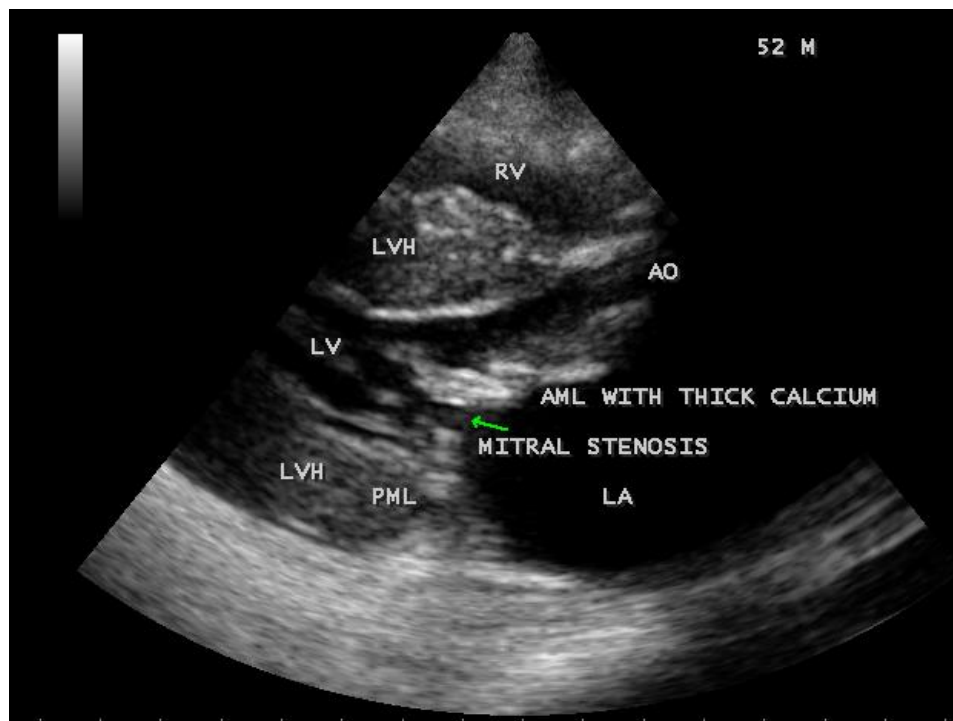
**Figure 1:** ECG showing the 'atrial fibrillation' with LVH (left ventricular hypertrophy).



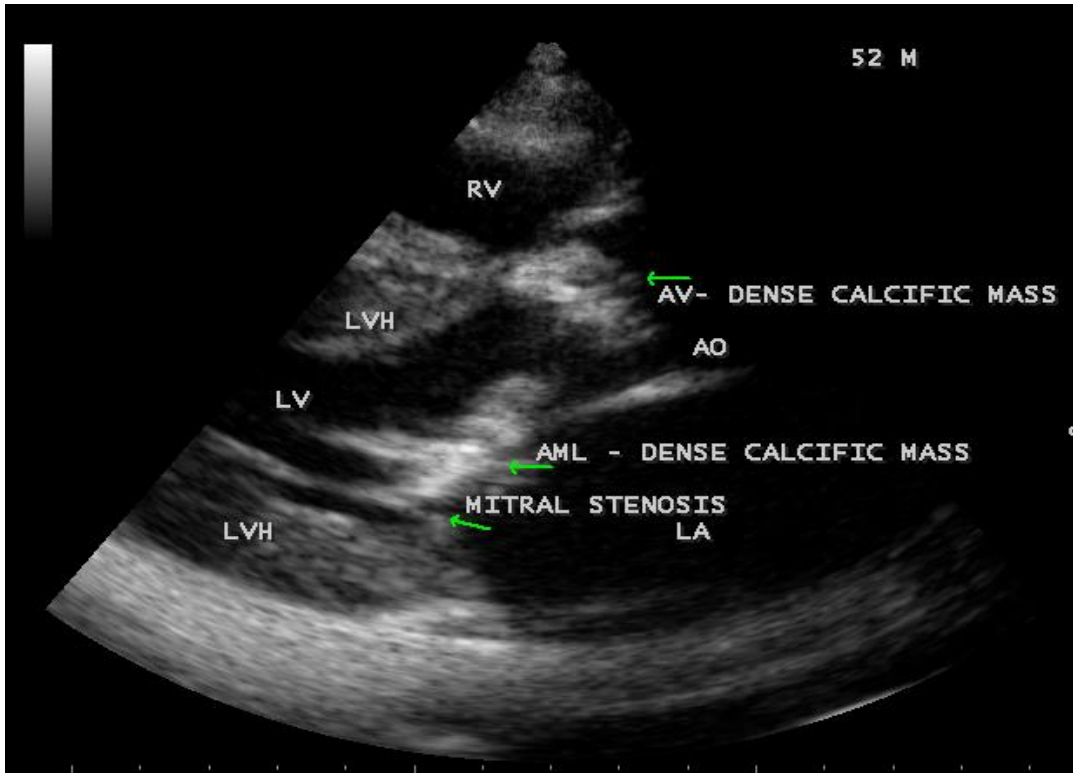
**Figure 2:** X-ray chest PA (postero-anterior) view showing concentric LVH (left ventricular hypertrophy) and dilated ascending aorta.



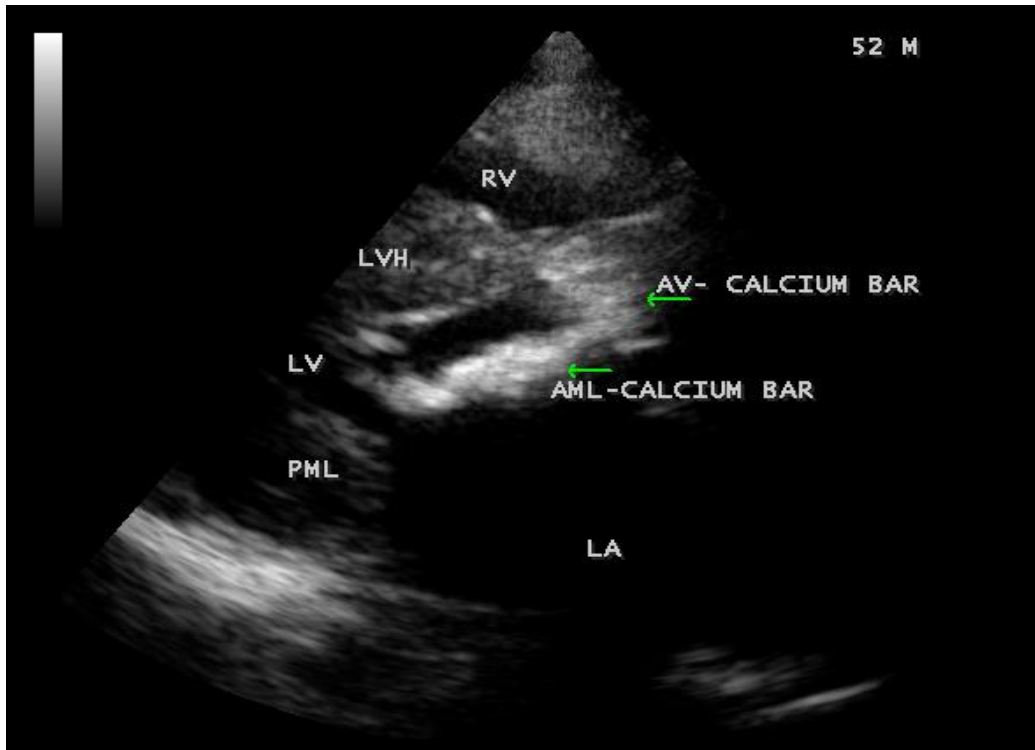
**Figure 3:** Parasternal long axis view showing the dense calcification of anterior mitral leaflet (AML) with commissural fusion in a 52-year old male.



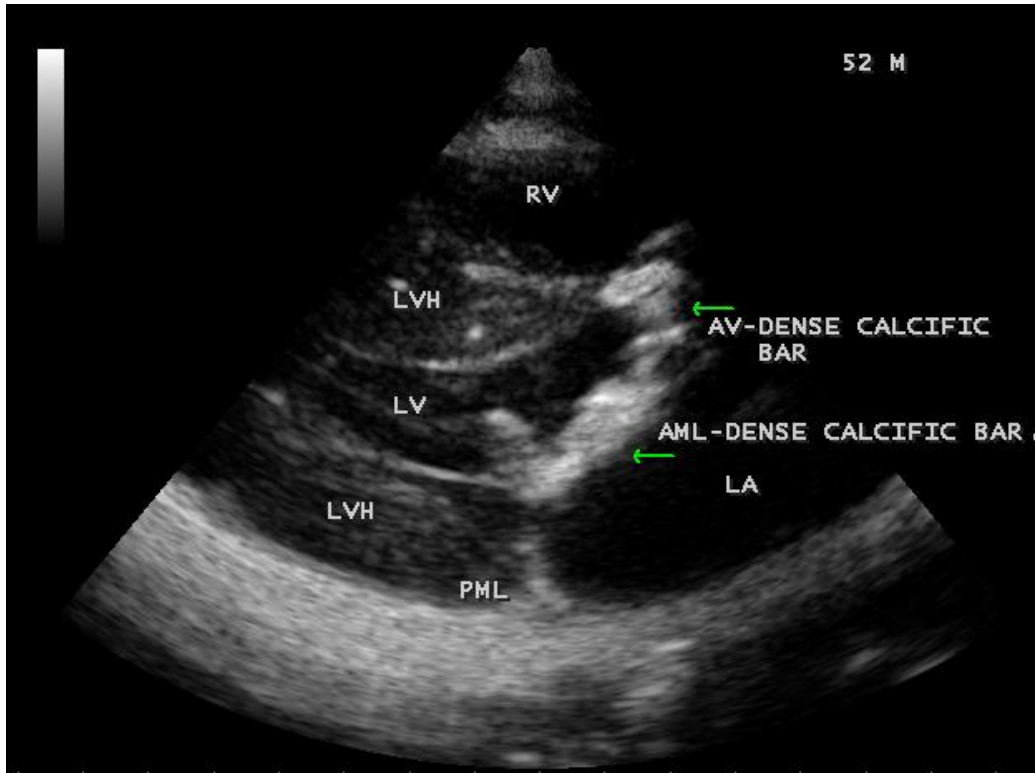
**Figure 4:** Parasternal long axis view showing the anterior mitral leaflet as a dense calcific bar with opening of the stenotic mitral valve in a 52-year old male.



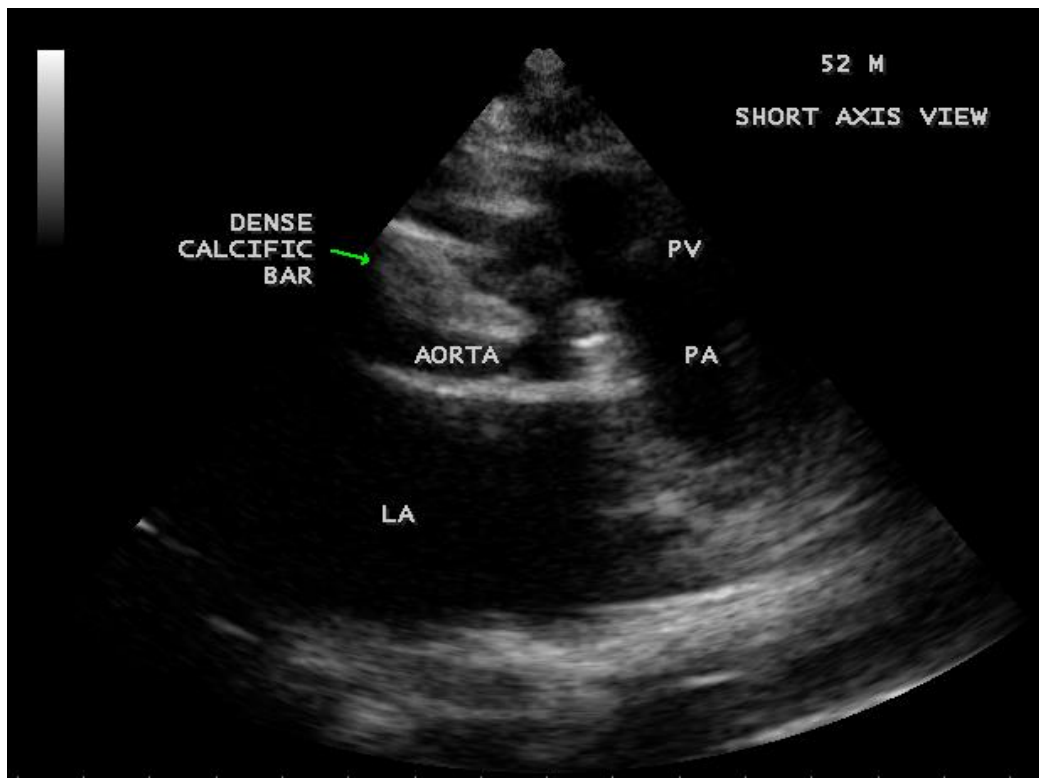
**Figure 5:** Parasternal long axis view showing the calcific bar of anterior mitral leaflet and aortic valve in a 52-year old male.



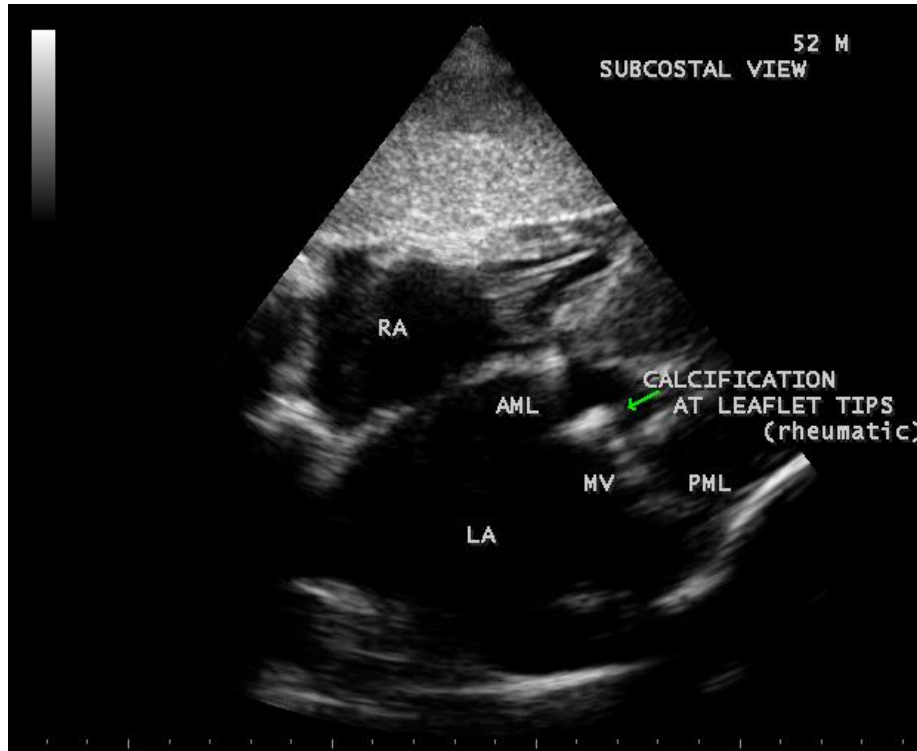
**Figure 6:** Parasternal long axis view showing the calcific extension of aortic valve to anterior mitral leaflet in a 52-year old male



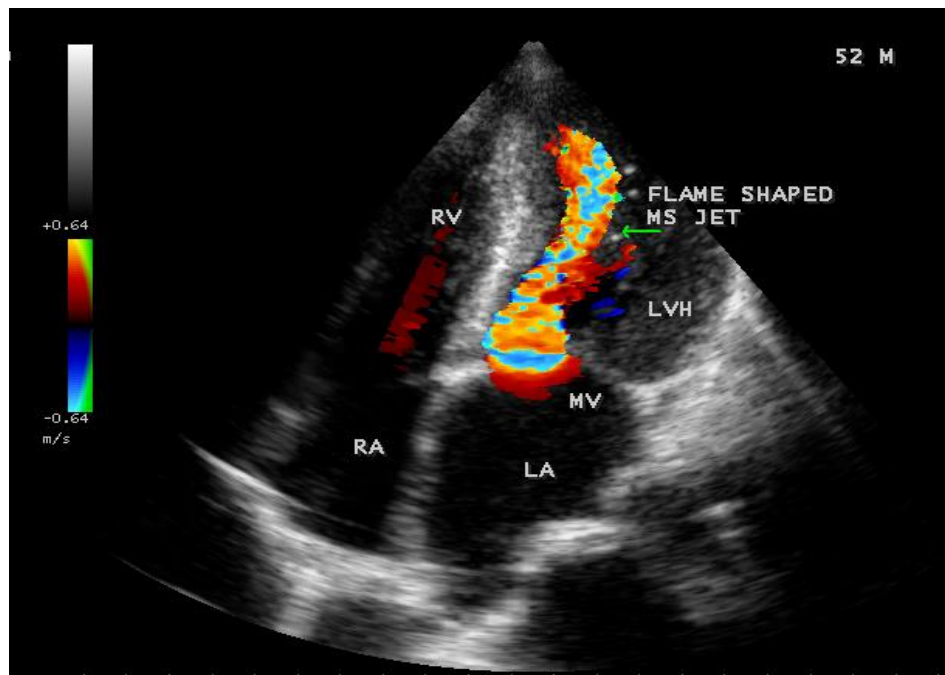
**Figure 7:** Parasternal long axis view showing the J-shaped appearance of mitral-aortic calcification in a 52-year old male.



**Figure 8:** Short axis view showing the dense calcific bar in the aortic valve visible as calcium stone in a 52-year old male.



**Figure 9:** Subcostal view showing the rheumatic thickening of mitral valve and LA Dilatation.



**Figure 10:** Apical view showing the 'flame-shaped' mitral stenosis jet in a 52-year old male.

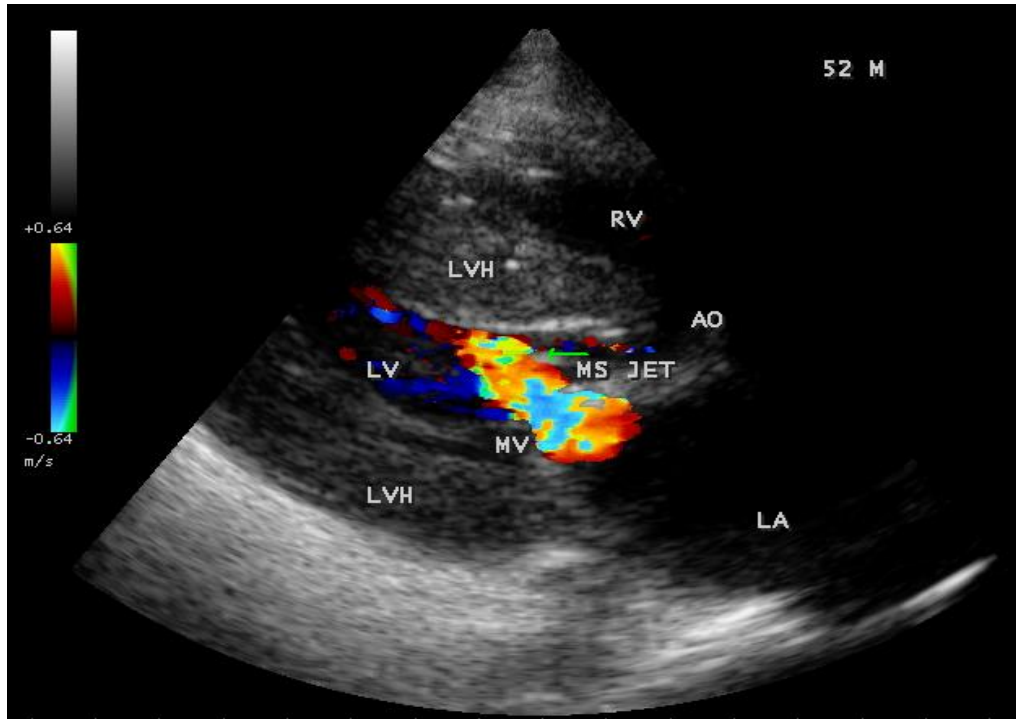


Figure 11: Subcostal view showing the mitral stenosis jet.

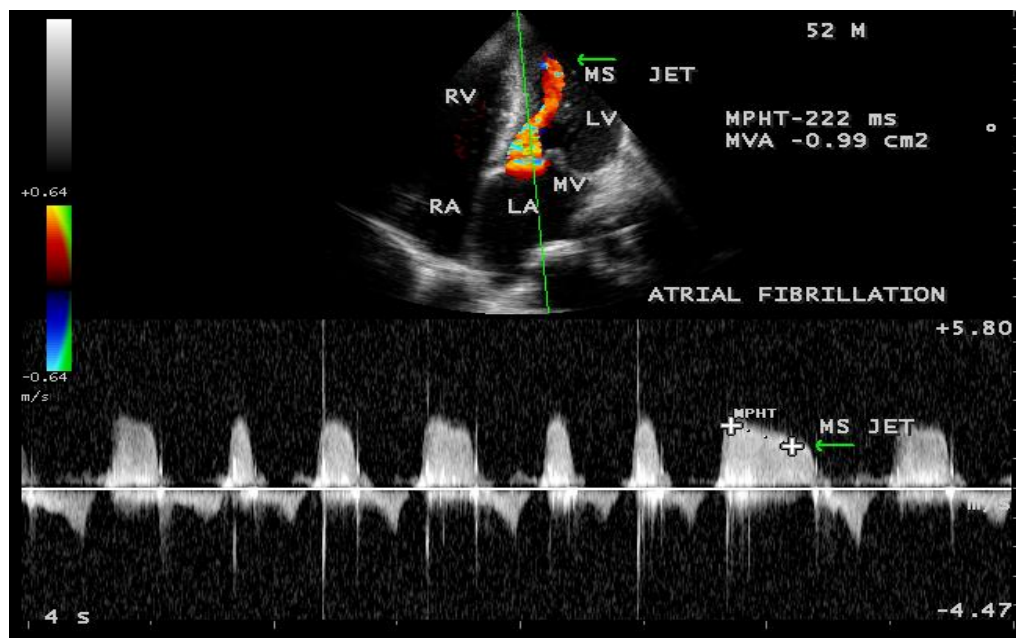


Figure 12: CW (continuous wave) Doppler showing the severe mitral stenosis.

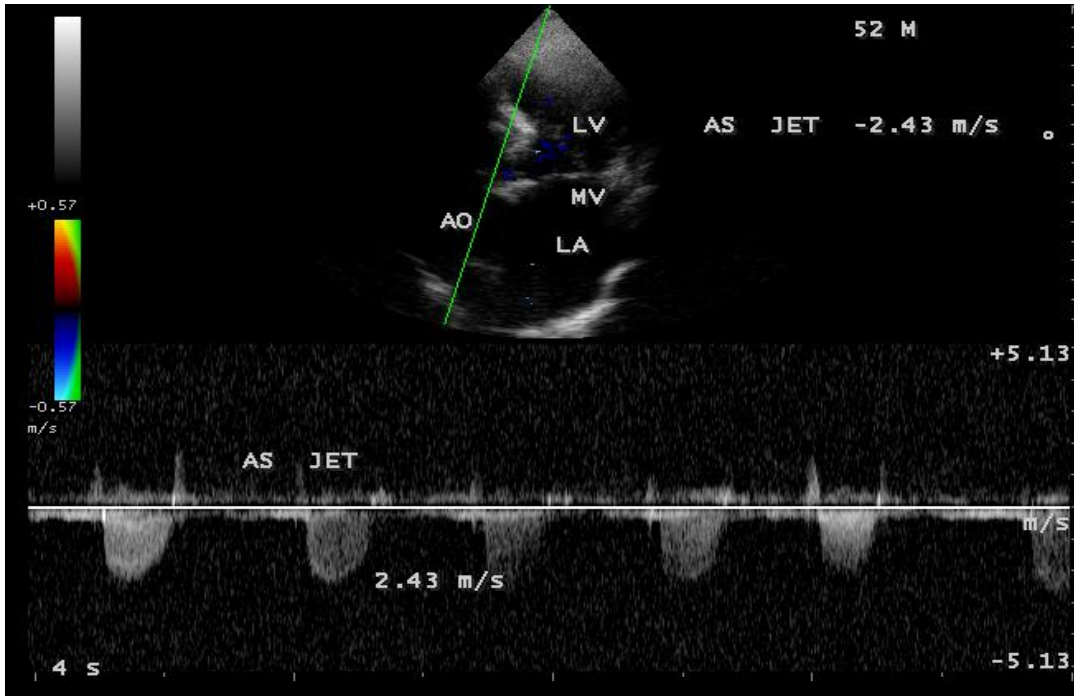


Figure 13: CW (continuous wave) Doppler showing the aortic stenosis jet in a 52-year-old male.

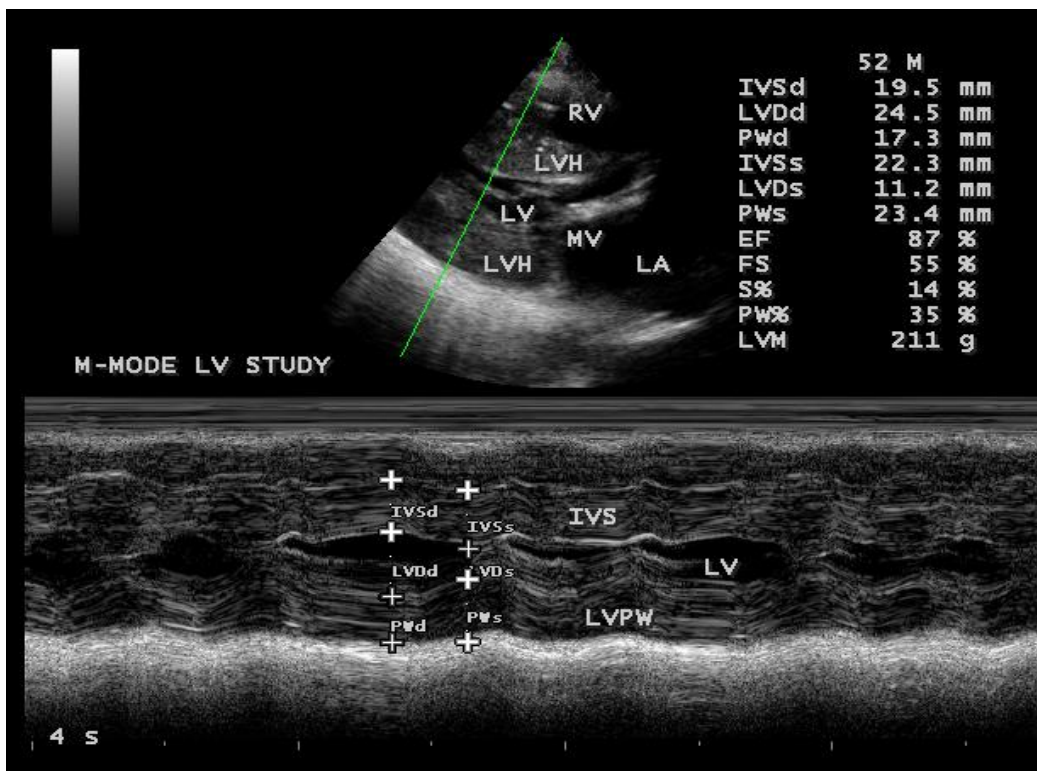


Figure 14: M-mode LV study showing the high ejection fraction (87%).



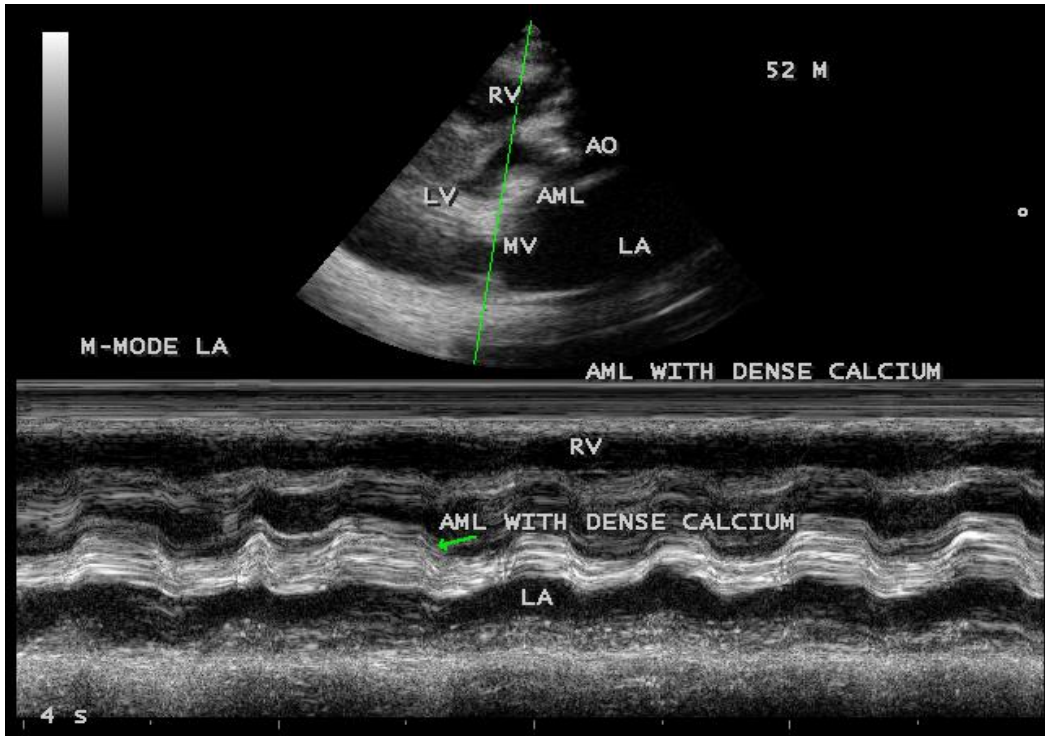


Figure 15: M-mode at AML showing the dense calcium in a 52-year old male.

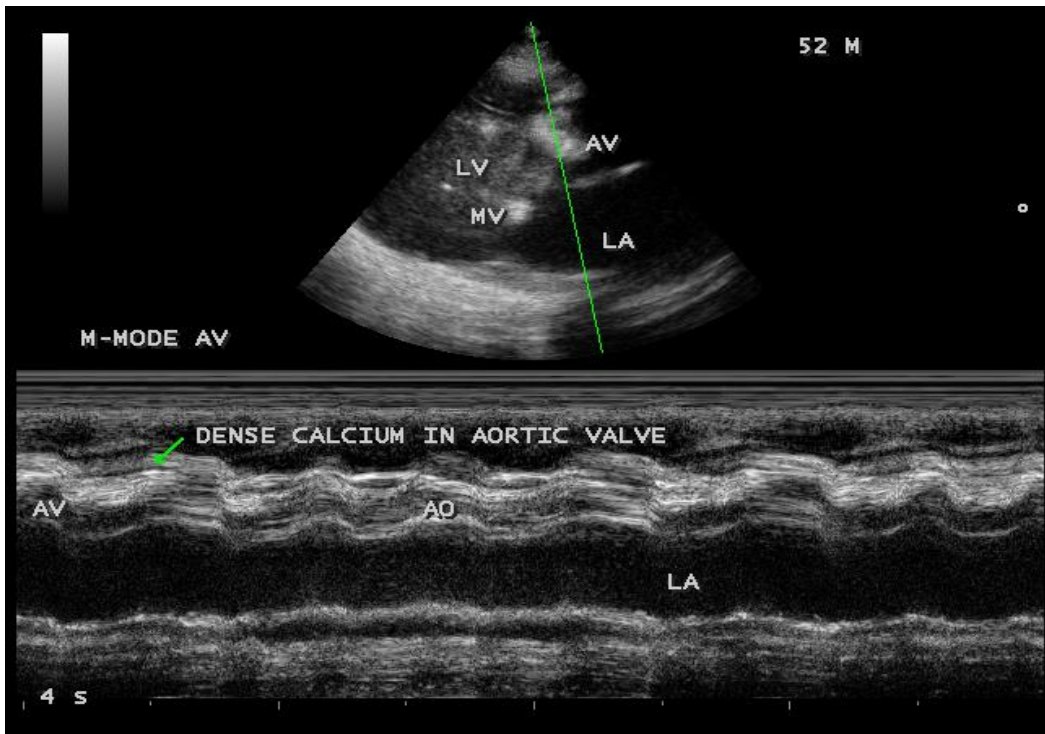


Figure 16: M-mode at aortic valve showing the dense calcium in a 52-year old male.

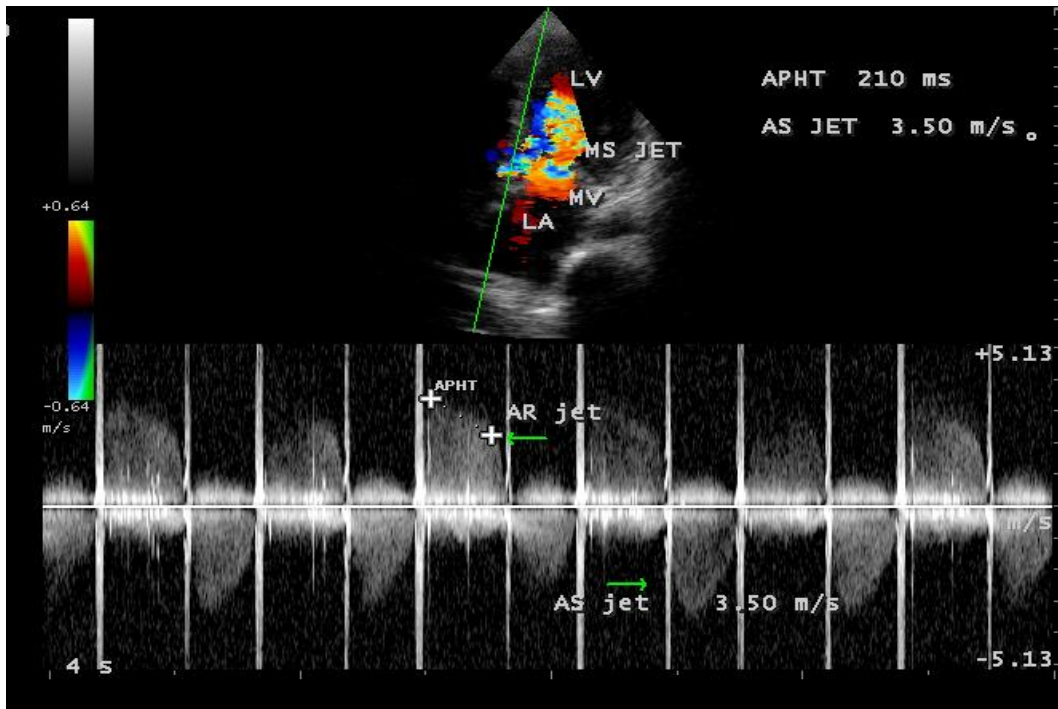


Figure 17: CW (continuous wave) Doppler showing the jets of aortic stenosis and regurgitation in a 34-year old male.

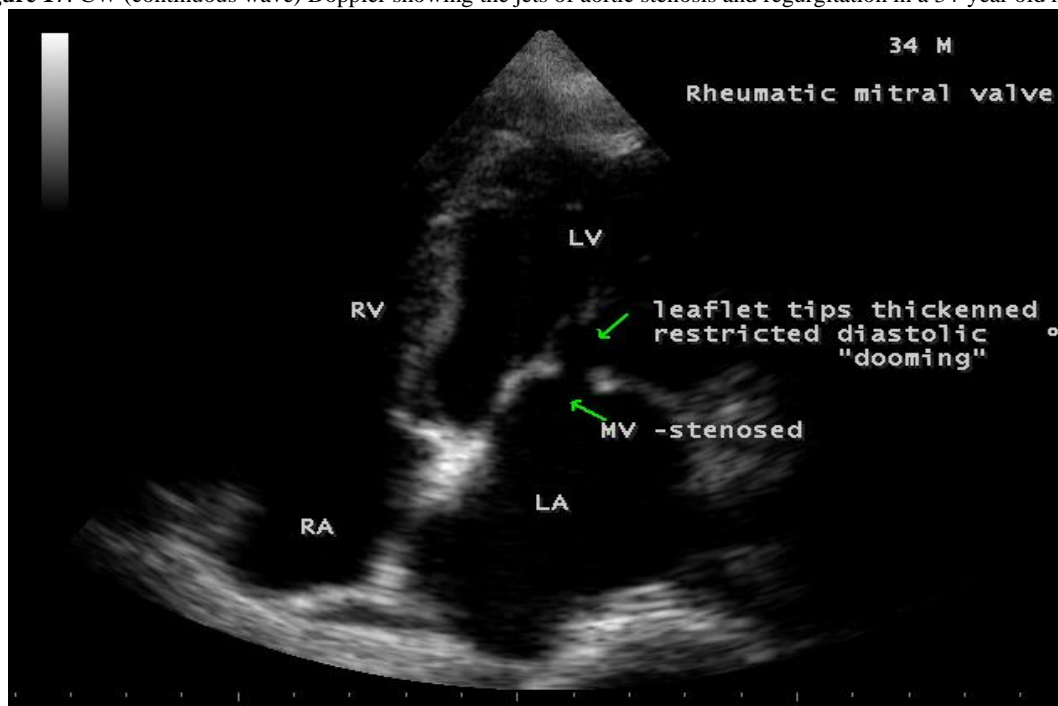


Figure 18: Apical view showing the rheumatic mitral valve in a 34-year old male (Rheumatic mitral stenosis).

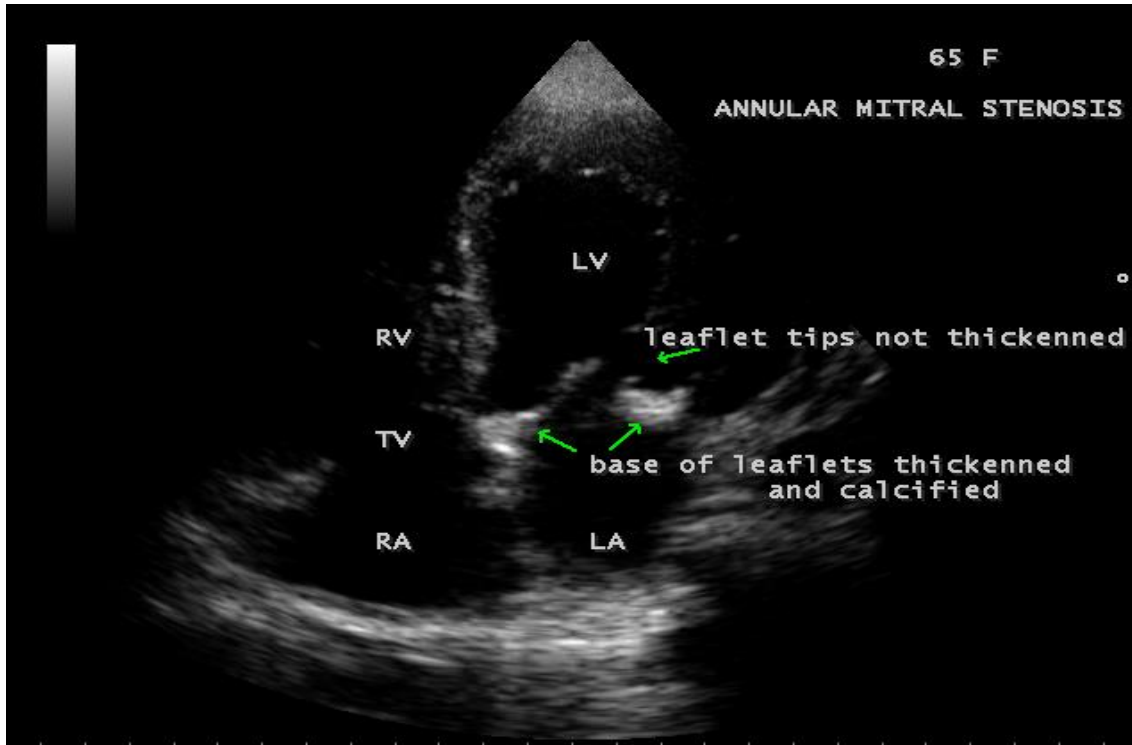


Figure 19: Apical view showing the annular mitral stenosis with basal leaflet calcification in a 65-year old female.

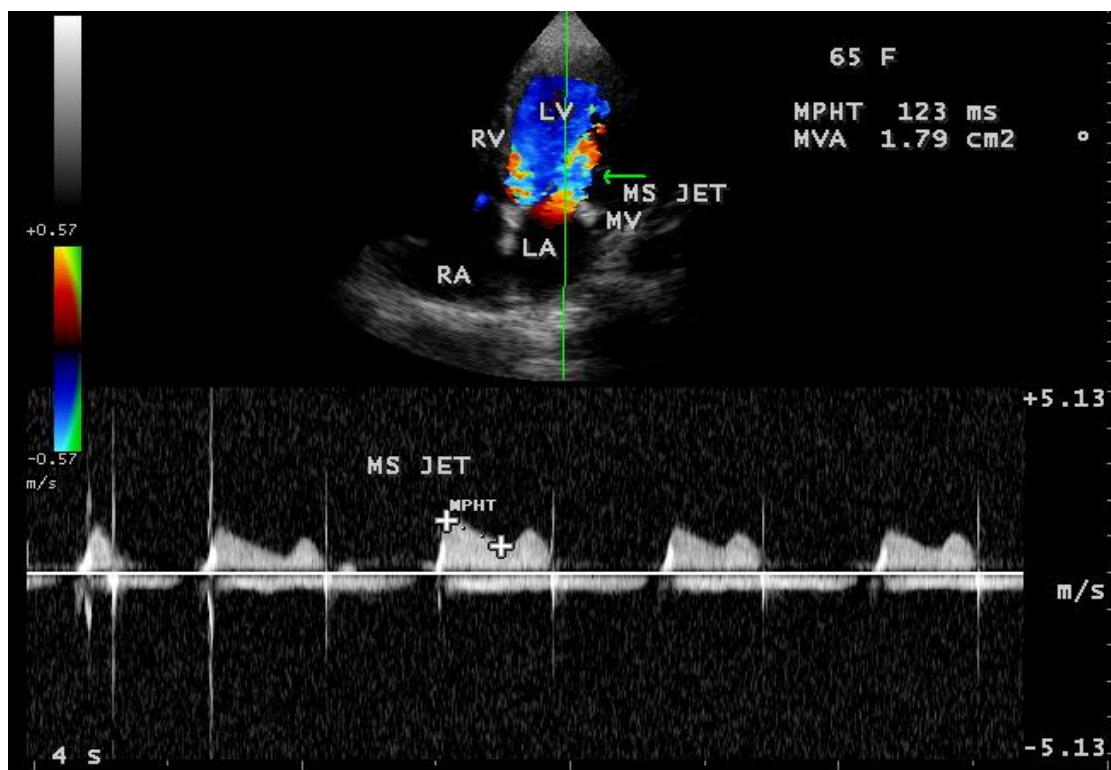
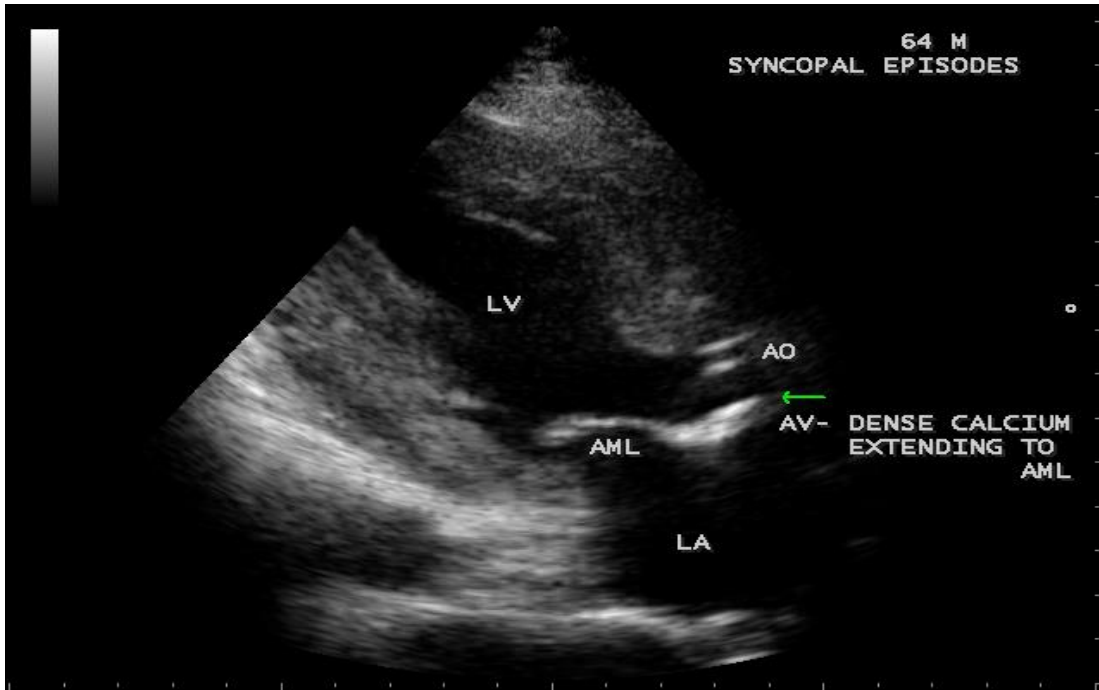
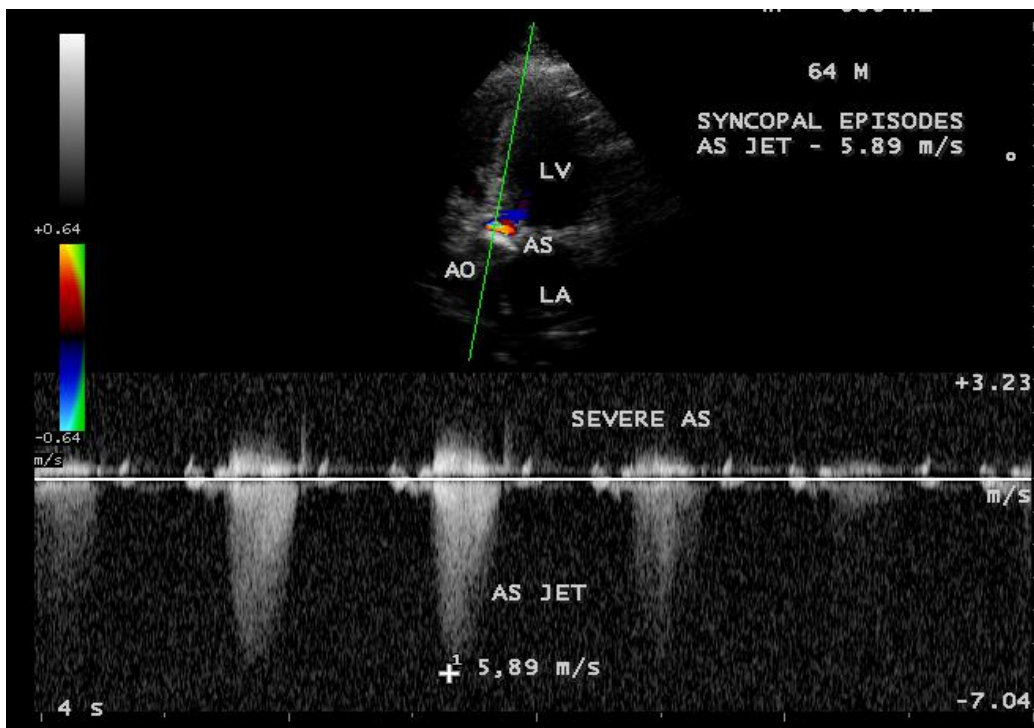


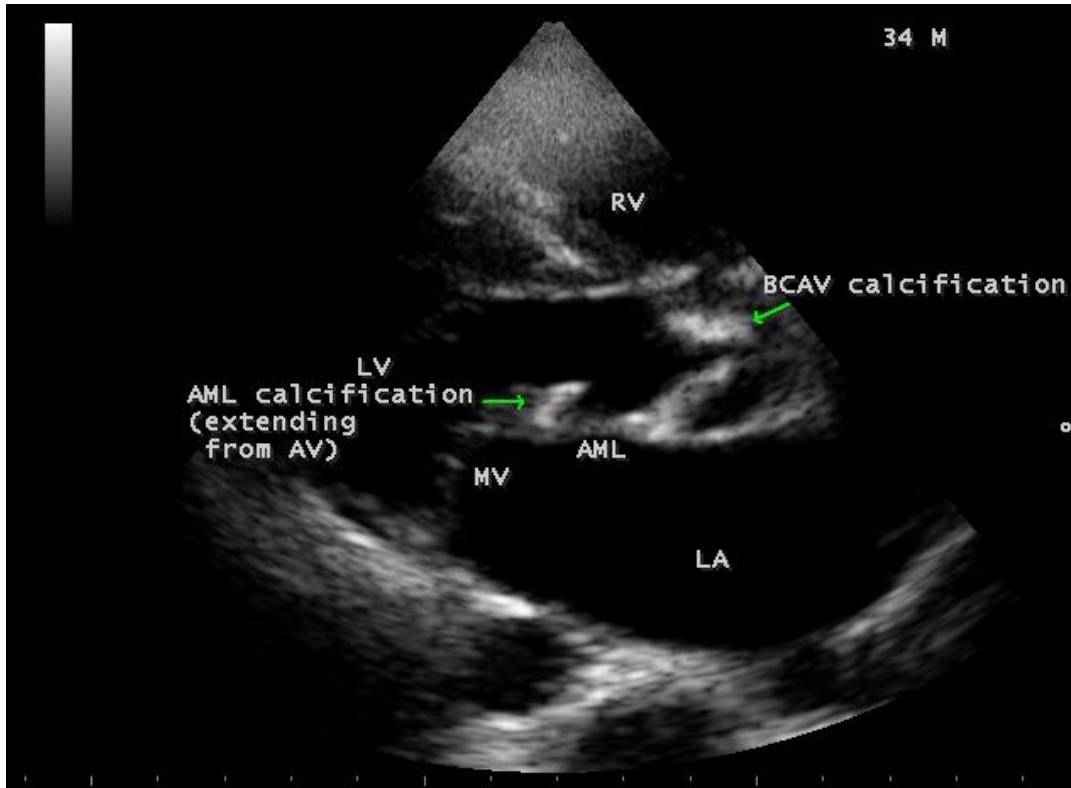
Figure 20: CW (continuous wave) Doppler showing the annular mitral stenosis (mild) jet in a 65-year old female.



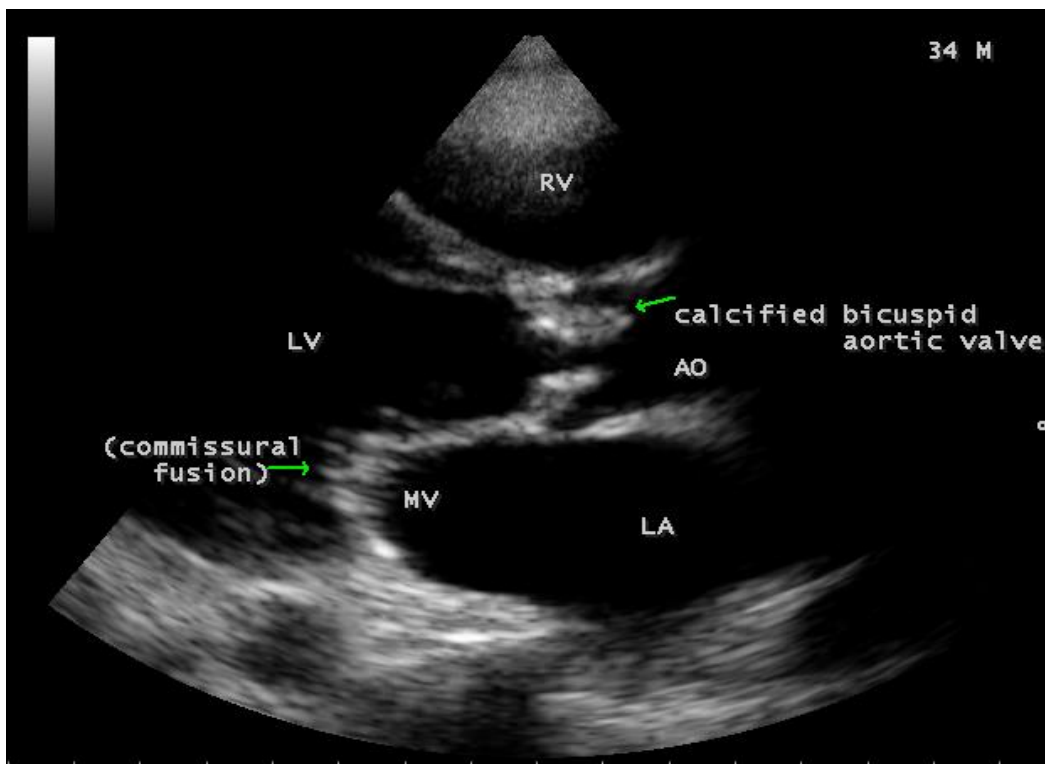
**Figure 21:** Parasternal long axis view showing the extension of aortic valve calcification to anterior mitral leaflet in a 64-year old male.



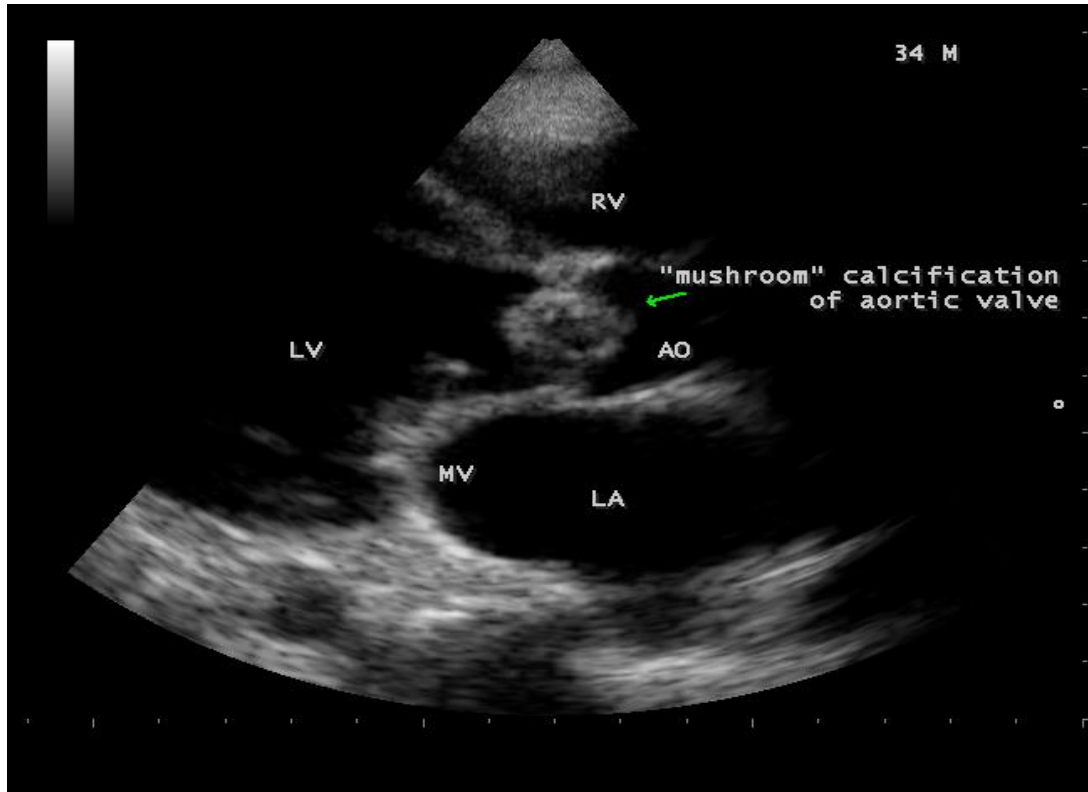
**Figure 22:** CW (continuous wave) Doppler showing the severe aortic stenosis jet in a 64-year old male.



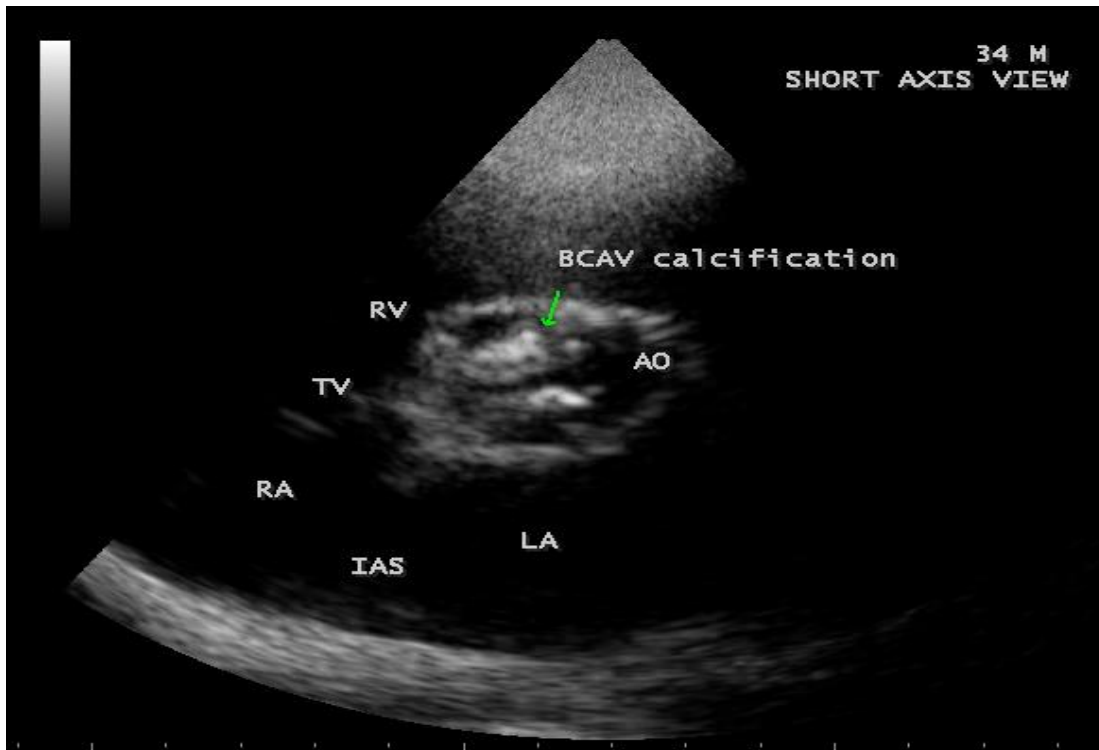
**Figure 23:** Parasternal long axis view showing dense calcium in aortic valve and anterior mitral leaflet in a 34-year old male.



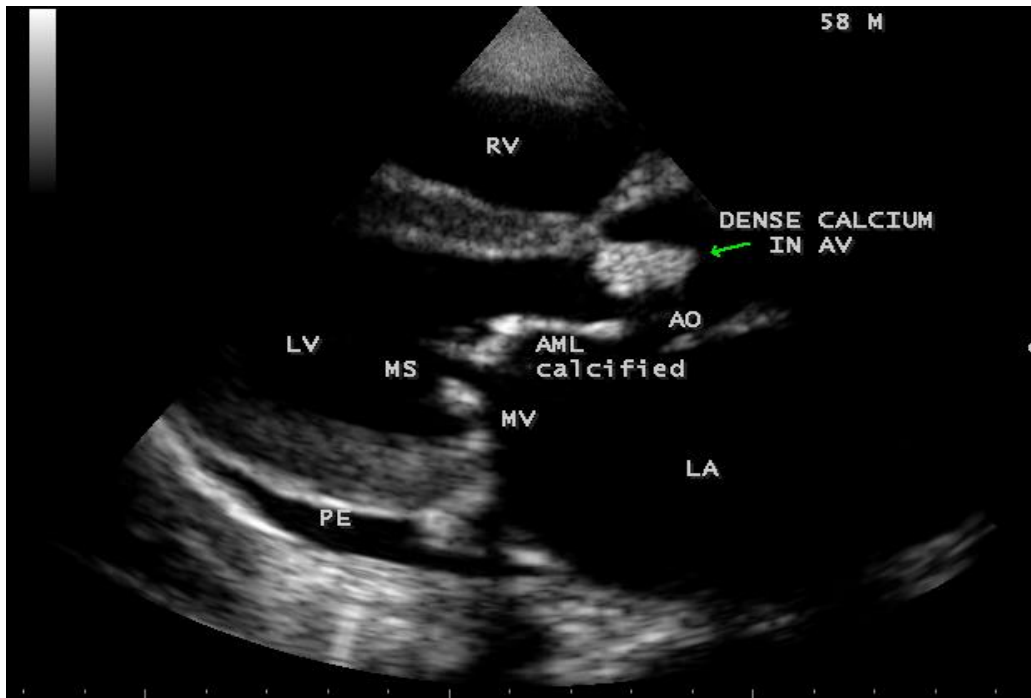
**Figure 24:** Parasternal long axis view showing the 'mushroom' calcification of bicuspid aortic valve in 34-year old male.



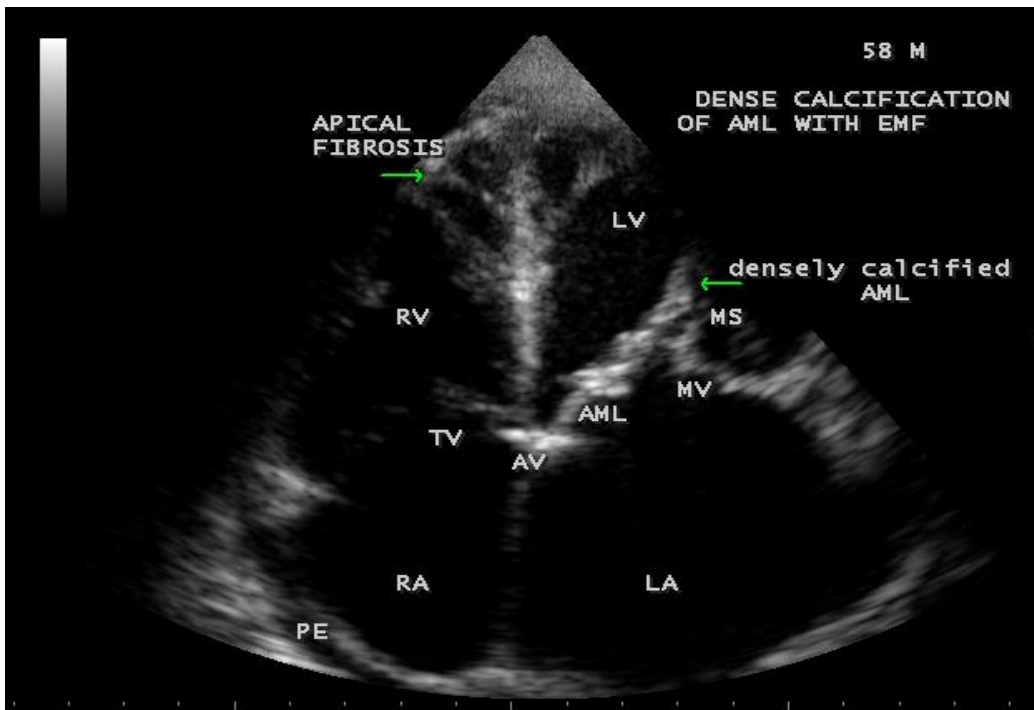
**Figure 25:** "mushroom" shaped calcification of Bicuspid aortic valve in a 34-year old male.



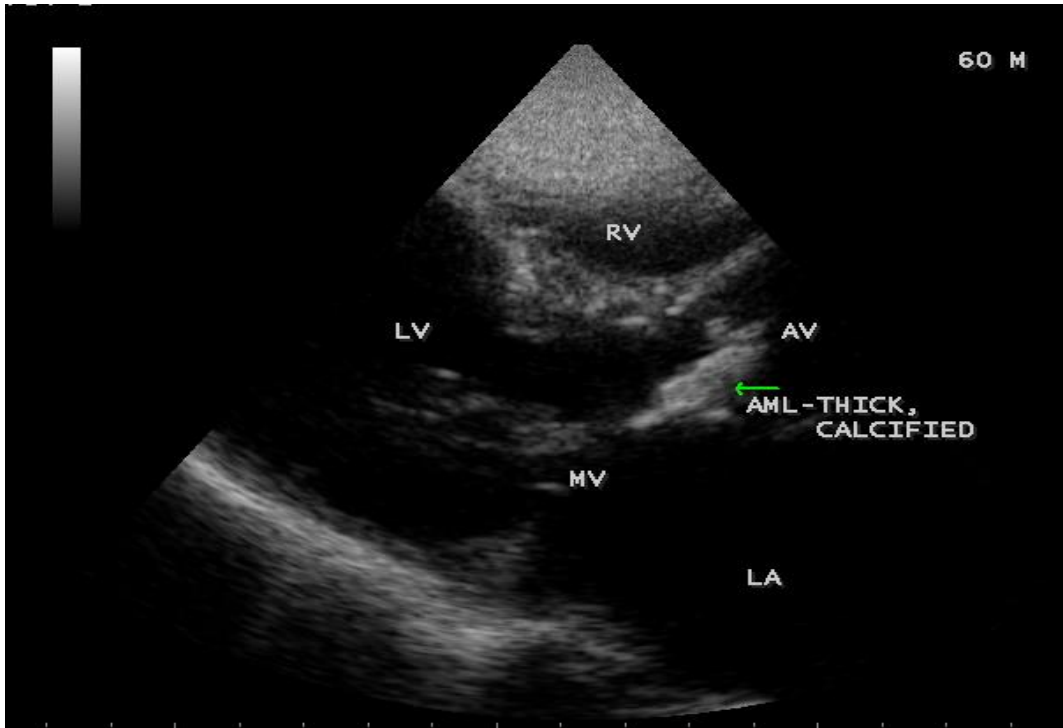
**Figure 26:** Short axis view showing the dense bicuspid aortic valve calcification in 34-year old male.



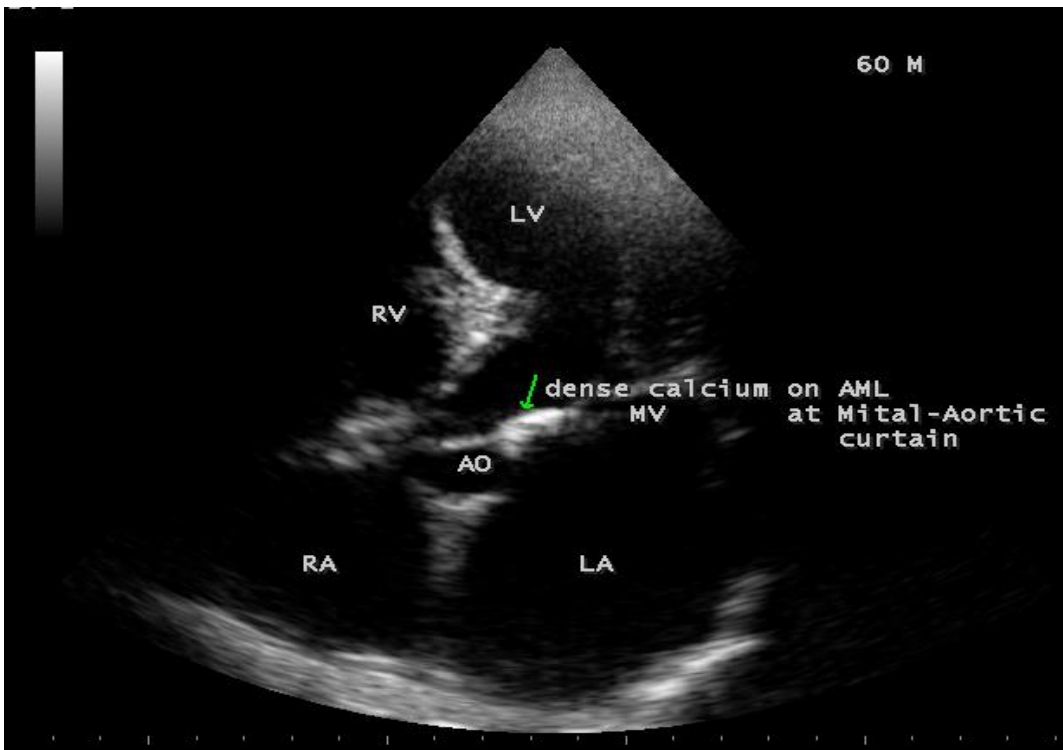
**Figure 27:** Parasternal long axis view showing the dense calcium in aortic valve and anterior mitral leaflet in EMF (endomyocardial fibrosis) in a 58-year old male.



**Figure 28:** Apical view showing the calcification of anterior mitral leaflet and RV apical fibrosis suggesting EMF (endomyocardial fibrosis) and rheumatic mitral stenosis in a 58-year old male.

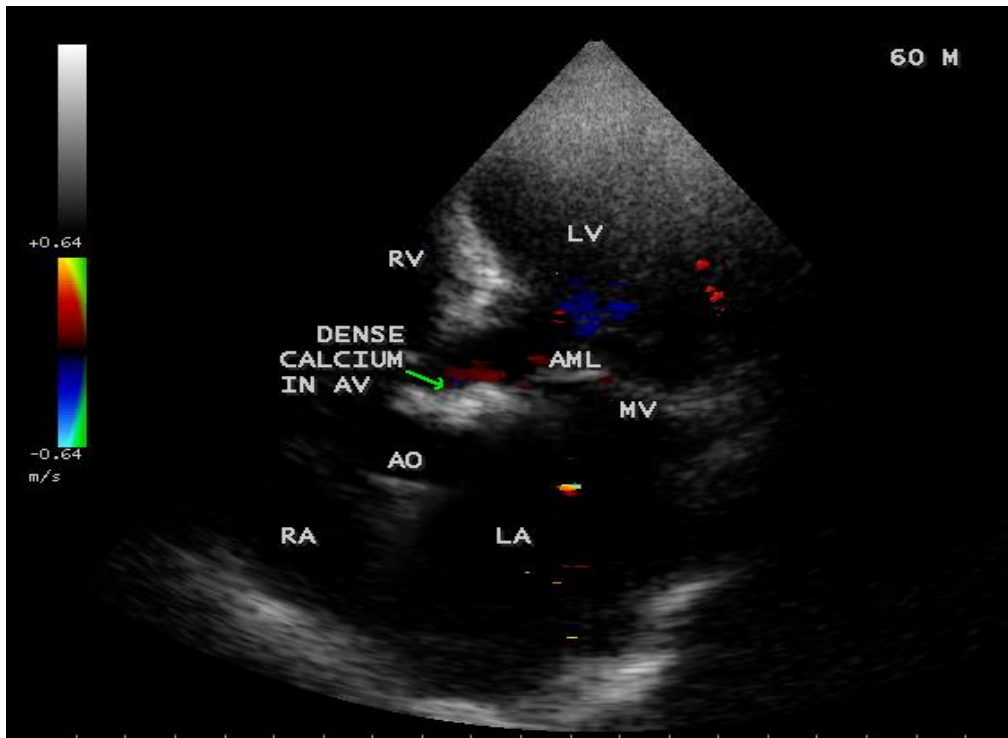


**Figure 29:** Parasternal long axis view showing the calcification of anterior mitral leaflet in a 60-year old male.

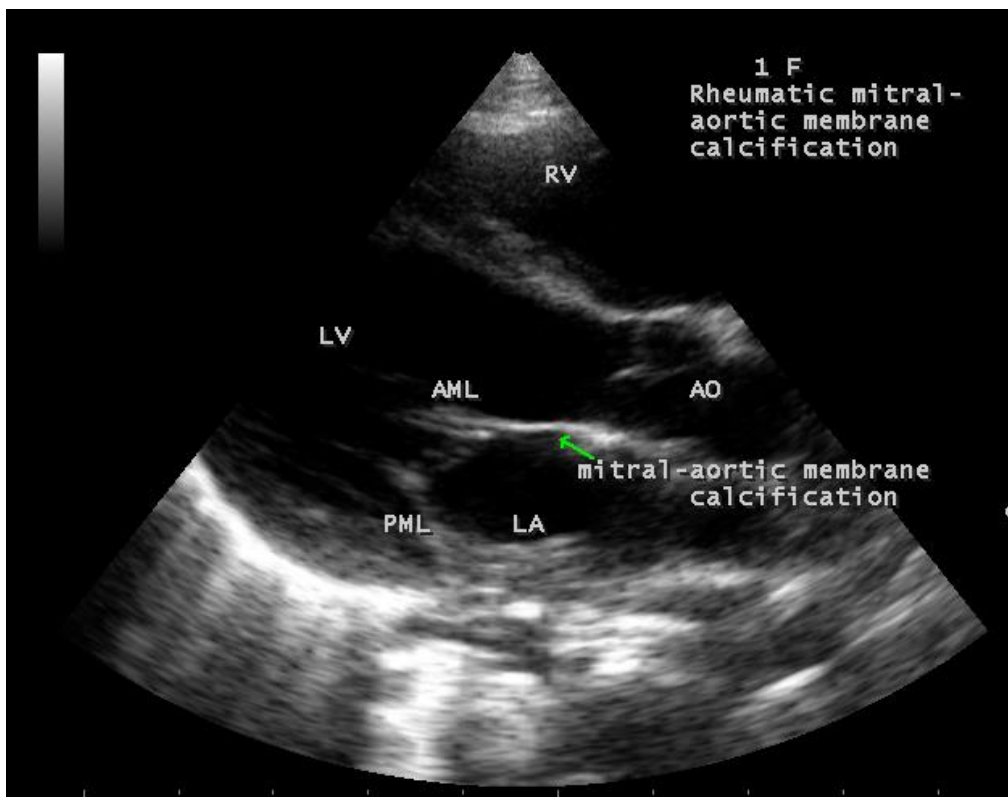


**Figure 30:** Showing the dense calcium in mitral-aortic membrane in a 60-year old male.





**Figure 31:** Dense calcium in aortic valve mimicking as ‘calcific amorphous tumor’ in a 60-year old male.



**Figure 32:** Rheumatic calcification of mitral- aortic membrane in a one-year old female child.

**3. Discussion**

**Review of literature:** Lazare Riviere, a French physician in 1663, identified large caruncle-like masses obstructing the left ventricular outflow to the aorta in necropsy findings as an earliest description of calcific aortic stenosis [4] and the calcified mass was originally attributed to endocarditis. In 1846,

Hass suggested a degenerative process occurred within the valve itself to initiate ossification. In 1904, Moenckeburg found that the aortic valve calcification occurred as a result of calcium deposition on the valve cusps due to degeneration within the layers of valve leaflets or extension of sclerotic changes of aorta to valve cusps. In 1924, Dr. Carey Coombs described the inflammatory lesion in the rheumatic valve leaflets and the

presence of new vessels developing within the valves [5]. In 1931, Christian first described that aortic stenosis with calcification of the cusps was possibly of rheumatic origin [6]. In 1938, Clawson, Noble and Lugkins stated that the 'calcified aortic nodular deformity' was predominantly of a rheumatic nature [7]. In 1939, Dry and Willius concluded that the etiologic factor of calcification was rheumatic [8] and Hamburger and Saphir found evidence for both a rheumatic and nonrheumatic origin [9]. In 1961, Edwards discussed the occurrence of calcification in stenotic rheumatic valves [10].

**Pathogenesis:** Rheumatic heart disease is the most common cause of valvular heart disease in tropical nations such as India. Rheumatic valve calcification is not a random passive process, but it is a regulated, inflammatory cellular process associated with the expression of osteoblast markers and neoangiogenesis. Early stage of calcification is in a manner akin to atherosclerosis. Once the osteoblast activity has been established, the

disease progression is more likely to be regulated by the mediators of calcium homeostasis [11]. A similar osteoblast-like process that occurs in degenerative calcific valve develops in the calcific process of rheumatic valves [12]. The cellular and molecular mechanisms that involves the valve, circulating and bone marrow derived cells have been implicated in the pathogenesis of calcification. The cellular differences between the rheumatic and degenerative lesions are the intense inflammatory infiltrate and VEGF (vascular endothelial growth factor) expression in areas of neoangiogenesis found in rheumatic valves compared to degenerative valves. The cardiovascular risk factors such as exposure to biochemical (hypercholesterolemia, hyperglycemia) or mechanical (hypertension) may disrupt the normal cellular and matrix architecture of the valve, produces an inflammatory tissue milieu, atherosclerosis like lesions, osteoblastic transformation and calcification process. The key mediators of valve calcification are shown in table 1.

Key mediators of valve calcification
VECs (valve endothelial cells) to mesenchymal transition
VICs (valve interstitial cells) to osteoblast-like bone forming cells
Matrix vesicle formation gives rise to microcalcific nodules
Lipid accumulation

**Table-1:** (Key mediators of valve calcification).

These mediators promote neoangiogenesis, extracellular matrix remodeling, fibrosis and calcification of valve leaflets. Calcification of heart valves is an immune-inflammatory disease process. The rheumatic involvement produces an inflammatory tissue environment that disrupts the endothelial layer of valve leaflets in a mechanism similar to that in atherosclerosis. The endothelial disruption may allow the lipids, including low-density lipoproteins, apolipoprotein B, (a) and E2 to penetrate and accumulate in areas of inflammation and undergo oxidative modification. These oxidative lipoproteins are highly cytotoxic, capable of stimulating intense inflammatory activity and subsequent mineralization [13]. The VECs (vascular endothelial cells) are activated and the expression of adhesion molecules that facilitate recruitment and transendothelial migration of monocytes which differentiate into macrophages, and infiltration of T-lymphocytes and  $\alpha$ -actin expressor cells. The macrophages release matrix metalloproteinases and cysteine endoproteases that lead to degradation of collagen and elastin in the valve matrix to disrupt the normal valve architecture [14]. The T-cells release proinflammatory cytokines, including transforming growth factor- $\beta$ 1, tumor necrosis factor- $\alpha$  and interleukin-1- $\beta$  which induce myofibroblast activation and cellular proliferation, ultimately help to stimulate and establish subsequent fibrotic and calcification processes that drive increasing valve stiffness [15],[16]. Increased levels of activated CD8 cells (cytotoxic T-cells or natural killer cells) and memory effector cells in patients with calcified valves may indicate a systemic adaptive immune response on valve calcification [17]. Lrp5, a coreceptor of the family of LDL receptors, has been found to regulate cellular proliferation and bone formation in valvular tissues [18]. Genetic bone markers have been found to be important in the development of osteoblast bone formation, a process that precedes calcification [19]. Lp(a) levels mediate the effect of SN rs10455872 in the gene LPA in valvular calcification. The kringle IV type 2 (KIV-2) repeats at LPA locus, which encode apolipoprotein (a) and its variation determines the plasma Lp(a) levels. NOTCH 1 on chromosome 9q34-35 is a susceptibility locus for bicuspid aortic valve and accelerates valvular calcification [20]. At the site of endothelial damage, the endothelial progenitor cells participate in the repair process by transiently establishing residence and secreting factors that facilitate proliferation and migration of resident endothelial cells [21]. In calcified valves, these progenitor cells are dysfunctional and express increased proapoptotic caspase -3 activity and decreased telomeric -repeat binding factor-2 (TERF2) expression, indicating progenitor cell senescence [22]. The VECs (valvular endothelial cells), lose

the endothelial cell properties, no longer express endothelial-specific markers such as cadherin, pieracque-like pleomorphism characteristic of mesenchymal cells or myofibroblasts and express  $\alpha$ -smooth muscle actin, type I collagen and vimentin [23]. The transforming growth factor- $\beta$ , transcription factor Msx2 and  $\beta$ -catenin signaling increase the motility and migration of these 'transformed' VECs into the surrounding tissues [24]. Once the endothelial-to-mesenchymal transition (EnMT) occurs, the BMP 2 and 4 (bone morphogenic proteins) secreted by the activated endothelial cells stimulate the calcification by activating Smad and Wnt/B-catenin signaling and upregulate the expression of osteochondrogenic transcription factor Msx2 and the faster osteoblast transcription factor Runx2 [25]. Once Runx2 is expressed, the cells are committed to an osteoblast lineage, upregulated the expression of calcification-related proteins (osteopontin, bone sialoprotein II, osteocalcin) and undergo calcification [26]. A subpopulation of VICs (valve interstitial cells) become activated in the inflammatory zone of the valve and differentiated into myofibroblasts. These myofibroblasts secrete matrix metalloproteinases which play a role in the restructuring of valve leaflet matrix and responsible for accelerated fibrosis in this process [27]. Under the influence of signaling pathways, Wnt-3-Lrp5- $\beta$  catenin [28], OPG/RANK/RANKL pathway (osteoproteogen/receptor activation of nuclear factor kappa B/RANK ligand [29], Runx-2/NOTCH1, activated by BMPs, the myofibroblasts undergo differentiation into osteoblasts, which subsequently coordinate calcification as a part of a highly regulated process akin to new bone formation and mineralize to form calcific nodules on the valves. The local environment drives the mesenchymal progenitor cells to undergo osteogenesis differentiation, elaborate bone matrix in the valve [30] and capable of contributing to valve calcification. The transition of valvular cells to an osteoblast-like phenotype is not a mutually exclusive process and these osteoblast-like cells may actively generate vesicles or undergo apoptosis to accumulate calcium and form microcalcifications. Matrix vesicles (100 to 300nm) are derived from plasma membrane of smooth muscle cells, encapsulate the calcium inhibitors (MGP- vitamin K dependent matrix Gla protein, Fetuin A- a liver derived protein, osteoproteogens), sequester, render them inactive [31] and serve as a nidus for calcium deposition [32]. Calcifying nanoparticles (10-500nm in size) consistent with nanobacteria [33],[34] which nucleate, crystallize and function as a nidus for matrix calcification [35]. The activated matrix metalloproteinases (1,2,3 and 9) and cathepsins (S,K,V and G) degrade the collagen and elastin, compromises valve integrity, augment the inflammatory response and allows

for the expansion of calcified nodules [36]. By the end stage of the disease, maturation of valve calcification occurs with lamellar bone and hemopoietic tissue and it is sustained by neoangiogenesis. The new vessels localizing to the region of inflammation and surrounds the calcific deposits. Both intercellular adhesion molecule-1 and vascular cell adhesion molecule-1 expression is increased in these vessels, suggesting that they act as an important portal of entry of inflammatory cells [37]. The mast cells get degranulated in calcified valves and release tryptase which degrade the angiogenesis inhibitor endostatin [38] and down regulation of local angiogenesis inhibitors such as chondromodulin-1 and pronomodulin-1 have been occurred. Once neovascularization has been established, the network of newly formed vessels, expressing the endothelial markers Tie-2, vascular endothelial growth factor receptor-2, smooth muscle  $\alpha$ -actin, facilitate rapid transit of inflammatory cells and procalcific signaling molecules and, these inflammatory lesions in rheumatic valvular disease is associated with angiogenesis and osteogenesis which may contribute disease progression and valvular mineralization.

**Echocardiographic features:** The genesis of calcification in aortic valve is always rheumatic [39] and the calcific extension to the mitral valve resembles J-shaped as shown in Figure 7. Calcification resembling a string of pearls in both aortic and mitral valves are typical of endocarditis. Calcification of mitral-aortic membrane has been reported as highly suggestive of radiation-induced lesions [40] and a pathologic echo density of anterior mitral leaflet is its characteristic feature [41]. But the dense calcification of anterior mitral leaflet as a bone-like structure was observed due to rheumatic mineralization as shown in Figures 3 and 4 along with calcification of aortic valve as in Figures 5 to 7 and in short axis view in Figure 8. The degenerative disease, as an aging process frequently involving the aortic and mitral valves and the central fibrous body is called as 'Lev's disease. Lenegre's disease primarily involves the conduction system without affecting the fibrous skeleton of the heart. Both these conditions mostly results in isolated chronic heart blocks in adults. Degenerative calcification of mitral annulus may cause annular mitral stenosis in elderly and the difference between the annular mitral stenosis and rheumatic mitral stenosis [42] was shown in Table 2.

Annular mitral stenosis (Figure 18)	Rheumatic mitral stenosis (Figure 19)
Heavy calcification at the base of leaflets Leaflet tips are free	Calcification of leaflets mainly at the tips Leaflet tips thickened
Leaflets open without dooming restriction	Restricted diastolic opening of leaflets with dooming

**Table 2:** (Difference between annular mitral stenosis and rheumatic mitral stenosis)

**Therapeutic Strategies:** It is now clear that there is an active biology that leads to stiffening and calcification of valve leaflets [43] and so the valvular calcification is a biologic process.

**Statins:** Lipoprotein (a) has been shown to accumulate in both early and end-stage aortic valve lesions and to co-localize with calcium deposition [44]. In atherosclerosis, inflammation and lipid deposition are the key components in both development of arterial plaque and its stability. Adverse events are predominantly related to plaque rupture, and much of the benefit from statin therapy is due to plaque stabilization and a thickening of the fibrous cap. Lowering Lp(a) levels during early -stage aortic valve disease, with the use of either niacin [45] or novel specific Lp(a) inhibitors [46] can slow the progression to aortic stenosis. Lipid-lowering with HMG-Co A reductase inhibitors (statins) has been shown to decrease inflammatory cell infiltration, osteoblast bone markers (alkaline phosphatase and Runx2) and downregulated lipoprotein receptor-related protein 5/ $\beta$ -catenin signaling to decrease valve calcification in rabbit models [47]. Despite these findings, 3 large-scale clinical trials (SEAS-Simvastatin and Ezetimibe in Aortic Stenosis [48], SALTIRE- Scottish Aortic Stenosis and Lipid Lowering Trial [49] and ASTRONOMER (Aortic Stenosis Progression Observation: Measuring Effects of Rosuvastatin) [50] failed to show a benefit for statins to limit the progression of aortic valve calcification. Also, statins are known to promote osteoblast differentiation and calcification [51]. Lowering of lipid levels may decrease calcium deposition and, halt the progress of valve calcification, but did not reverse the established calcification or valve dysfunction [52]. When the valvular interstitial cells (VICs) become osteoblast-like cells, statins may actually have a procalcifying effect.

**Warfarin:** Warfarin is an inhibitor of  $\gamma$ -carboxylase and vitamin K epoxide reductase, inhibits MGP (matrix Gla protein- an inhibitor of bone morphogenic protein (BMP) signaling [53]) activity and was shown to promote valvular calcification [54].

**Fetuin A:** It is a potent circulating inhibitor of calcification [55], acts by binding the cluster of calcium and phosphate to stabilize these ions and prevent uptake by cells and its deficiency was associated with valvular calcification [56]. Therapies with fetuin A show a potential in inhibition of valvular calcification [57].

**ACE inhibitors:** The stenotic valve is characterized by extensive thickening due to the accumulation of fibrous tissue and remodeling of the extracellular matrix. Myofibroblasts infiltrate the myocardium, secrete extracellular matrix proteins and accelerate the fibrosis, which is an integral part of the hypertrophic process [58]. The increased afterload in aortic stenosis serves as an additional load on the left ventricle and is associated with increased hypertrophic remodeling and LV dysfunction [59], leading to increased apoptosis. Myocardial ischemia occurs due to increased afterload and coronary flow reserve is impaired since the density of the coronary capillary network does not expand sufficiently to meet the demand in this pathological hypertrophy, in contrast to physiological hypertrophy in which the density of capillary network expand sufficiently. Areas of fibrosis are observed to co-localize with areas of myocyte apoptosis and drive the decompensation of the hypertrophic myocardial response. The rennin-angiotensin system is thought to modify the fibrotic process. Tissue angiotensin-converting enzyme (ACE) and angiotensin II are upregulated in stenotic aortic valves and angiotensin receptors have been identified on valve myofibroblasts [60]. Polymorphism of the ACE I/D gene have been associated with variations in left ventricular mass [61]. Beneficial effects with respect to hypertrophy, on valve narrowing [62], reduction in mortality and cardiovascular events [63] and less pronounced valve remodeling [64] were observed in patients with aortic stenosis, maintained on ACE inhibitors and angiotensin receptor blockers. There is an evidence that angiotensin receptor blocker therapy inhibits the development of atherosclerosis as well as myofibroblast and osteoblast trans-differentiation in rabbit aortic valves suggests that this drug class may be helpful in slowing aortic stenosis progression [65]. The blood pressure-lowering effect of ACE inhibitors reduces the mechanical stress and strain on the aortic valve and play a role in slowing the aortic stenosis progression by reducing inflammation, stabilizing plaque formation and mitigating the fibrotic process [66].

**Desnosumab:** The OPG/RANK/RANKL axis appears to have a central regulatory role in both calcification and osteoporosis, which coordinate calcium homeostasis via the action of osteoblasts and osteoclasts. OPG (osteoprotegerin) is a decoy receptor of RANKL, a potent stimulator of osteoclast differentiation and bone resorption [67]. Increased expression of RANKL (receptor activator of nuclear factor kappa B ligand) and reduced

levels of OPG has been also observed in stenotic aortic valves similar to osteoporosis. Inactivation of OPG in mice develops extensive vascular calcification [68]. The development of anti-RANKL monoclonal antibody desnosumab promising a strong rationale in the treatment of aortic stenosis.

**Bisphosphonates:** Calcification is a critical process in determining the progress of valvular stenosis and a overlap in pathophysiology between the aortic stenosis and osteoporosis provide a rationale for drugs such as bisphosphonates to reduce the valvular calcium, especially in patients with renal failure and bioprosthetic valves [69],[70]. However, it had no effect on freedom from aortic valve replacement or survival [71].

**Gene transfer:** By understanding the cell biology of valvular calcification, gene transfer or cell-based therapies are investigated to modulate the cellular mechanism of calcification. The expressing Runx2 in VICs (valvular interstitial cells) commits these cells to an osteoblast-like phenotype. Gene transfer of small interfering RNA that targets Runx2 using adenovirus or recombinant nonviral vectors have been shown to prevent calcification both in vitro and in vivo [72],[73]. Heterotopic ossification (HO) is characterized by pathologic endochondral bone formation at nonskeletal sites. Angiogenesis and osteogenesis are highly coupled during bone development. In the process of osteoblast differentiation, a set of bone specific genes (ALP-alkaline phosphatase, osteocalcin) are activated. Run-related protein 2 (Runx2) is a key regulator of these genes, cooperate with BMP-specific R-smads and it is considered as a molecular switch (myoblasts to osteoblasts phenotype) in osteoblast biology. Hypoxia is able to upregulate BMP2 in osteoblasts via the activation of Hif1  $\alpha$  signaling pathway. Inhibition of Hif1  $\alpha$  (hypoxia induced factor 1  $\alpha$  leads to reduce vessel formation, which may facilitate migration of host mesenchymal stem cells to the bone regeneration site. Synergistic inhibition of endochondral bone formation by silencing the angiogenic factor (Hif1  $\alpha$ ) and osteogenic factor (Runx2) by using the RNA interference technology, allow to design more targeted therapies to inhibit angiogenesis and osteogenesis[74]. miRNAs (microRNAs) have essential roles in osteoblast differentiation and heterotopic ossification. miR-203 is involved in these processes by repressing Runx2 expression in the post-transcriptional level. Therapeutic overexpression of miR-203 in osteoblasts may reduce heterotopic ossification and even prevent this disorder[75]. Cotransduction of small or short interfering RNA (siRNA) against Runx2 and Hif1  $\alpha$  to inhibit heterotopic ossification have been evaluated. TNP-470 is an antiangiogenic agent that inhibits the neovessel formation and TNP-70 inhibits the biological activity of BMP2 in early stage of bone induction. A potent delivery of a nanocomposite consisting of serum-soluble DOTAP/siRNA/PPAA-g-1% jeffamine formulation was shown to halt the osteogenic switch driven by BMP2 by silencing the Runx2m, the downstream mediator of BMP2 [76].

**Investigational therapy:** Osteoclast-like cells are identified in calcified lesions, which in turn capable of resorbing mineral deposits [77]. Thus, strategies to promote osteoclast recruitment or stimulate differentiation of monocytes and macrophages toward an osteoclast phenotype are the areas of active investigation. Strategies by delivering stem or progenitor cells via direct injection of small molecule inhibitors, osteoclasts, osteoclast-like cells or molecules that promote the transition of resident monocytes/macrophages towards an osteoclast lineage or viral vectors encoding inhibitory RNA (Runx2, Msx2) in areas of aortic valve lesions or to ischemic myocardium using a NOGA-guided catheter system [78] are under investigation.

**Lonafarnib:** Mutations in laminin A gene results in the production of a mutant lamin A protein, progerin, a component of nuclear envelope which become unstable, leading to cell death prematurely. The syndromes associated with these defects are called as 'laminopathies' (Hutchinson Gilford Progeria Syndrome (HGPS), Wiedemann-Rautenstranch syndrome, Restrictive dermatopathy) [79]. In progeria, calcific aortic stenosis represents

a degenerative premature aging process and principally involving the anterior mitral valve and proximal aortic valve cusps [80]. Systemic hypertension is common and appear before the child reaches the age of 5, and high mortality related to myocardial infarction and heart failure may occur. Farnesylation is essential for the function of both mutant and nonmutant lamin A protein, including progerin. Lonafarnib is a farnesyl transferase inhibitor that blocks the posttranslational farnesylation of prelamin A, an experimental drug under trials [81]. Another treatment attempted is a combination of two molecules-Zoledronic acid and pravastatin.

**Interventional therapy:** Balloon mitral valvotomy (BMV) is the procedure of choice for severe mitral stenosis when the valve morphology is feasible. However, BMV is contraindicated in commissural calcification since it results a high probability of leaflet tear with acute severe mitral regurgitation. BMV can be performed safely and successfully in unicommissurally calcified mitral valves [82]. An emergency percutaneous transatrial balloon mitral commissurotomy is a life-saving procedure in a valve with unfavourable morphology, presented with cardiogenic shock in critical calcific mitral stenosis [83],[84].

**Transcatheter valve implantation:** TAVR (transcatheter aortic valve replacement) was approved by FDA (Food and drug administration) for high risk surgical candidates in June 2012. There is an increase in risk of stroke due to thrombotic embolic material from the calcified valve.tissue and vascular damage results in severe paravalvular regurgitation, which is poorly tolerated in hypertrophied left ventricle leading to increase in mortality [85]. The surgical risk for mitral valve replacement is very high due to the comorbidities and technical challenges related to calcium burden. Guerrero, et al reported the first-in-human percutaneous implantation of a balloon – expandable transcatheter valve in a native mitral valve [86]. The use of newer aortic THV technologies such as Lotus (Boston Scientific Corporation) and direct flow valves (direct flow medical) in the mitral position for severe MAC (mitral annular calcification)[87] and improved outcomes were observed [88].

**Surgical therapy:** Aortic valve replacement surgery remains the only established treatment for symptomatic aortic stenosis patients [89]. Hemodynamically significant asymptomatic patients will develop symptoms within 5 years, the issues of medical management and surgical correction may pay a close attention to the researchers [90]. Presence of moderate or severe valvular calcification identifies the patients with poor prognosis who may benefit from early valve replacement before the development of symptoms [91]. and it is to be determined whether this benefit overweighs the risk of surgery [92]. Calcific mitral stenosis with severe mitral annular calcification may present a different challenges to the surgeon. Extensive debridement of calcium may increase the risk of paravalvular leakage and bleeding. Bypass of the mitral valve with a valved conduit is an another option for the treatment of severe calcific mitral stenosis [93]. Bioprosthetic valves are generally recommended for patients > 65 years and there is also greater usage in younger patients due to lack of necessity of chronic anticoagulation. The Ross operation (replacement of aortic valve with a pulmonary autograft and replacement of the pulmonary valve with a homograft) is an alternate for adolescents, young adults, including woman who wish to become pregnant and it is not favoured by the majority of surgeons due to complexity of the procedure, but excellent outcomes occurred in centers with expertise in this procedure [94].

**Screening of population:** Aortic valve calcification extending to anterior mitral leaflet with severe aortic stenosis was shown in Figures 21 and 22 in a 64-year old male. A bicuspid aortic valve calcification with rheumatic mitral stenosis was shown in Figures 17, 18, 23, 24 and it is 'mushroom' shaped [95] as in Figure 25 in a 34-year old male. J-shaped [96] mitra-aortic calcification was shown in Figure 7 in a 52-year old male. Dense

calcification of anterior mitral leaflet was shown in Figure 29 and aortic valve calcification resembling 'calcified amorphous tumor' [97] as in Figure 31 in a 60-year old male. Calcification of aortic valve in Endomyocardial fibrosis with rheumatic mitral stenosis was shown in Figures 27, 28 in a 58-year old male. Calcification of mitral-aortic membrane was shown in Figure 30 in a 60-year old male and in one-year old child as in Figure 32.

## References

1. Thubrikar, M., J., Nolan, S., P., Aouad, J., et al. (1986). Stress Sharing Between The Sinus And Leaflets of Canine Aortic Valve. *Annals of Thoracic Surgery*, 42, 434-440.
2. Parashara, D., K., Jacobs, L., E., Kotler, M., et al. (1995). Angina Caused By Systolic Compression of Left Coronary Artery As A Result of Pseudoaneurysm of The Mitral-Aortic Intervalvular Fibrosa. *American Heart Journal*, 129, 417-421.
3. Aikawa, E., Nahrendorf, M., Figueiredo, J., L., Swirski, F., et al. (2007). Osteogenesis Associates With Inflammation In Early-Stage Atherosclerosis Evaluated By Molecular Imaging In Vivo. *Circulation*, 116, 2841-2850
4. Vaslef, S., N., Roberts, W., C., (1993). Early Descriptions of Aortic Valve Stenosis. *American Heart Journal*, 125, 1465-1474.
5. Coombs, O., F., (1924). *Rheumatic Heart Disease*, New York, NY. William Wood And Co.
6. Christian, H., A., (1931). Aortic Stenosis With Calcification of The Cusps: Distinct Clinical Entity. J.A.M.A. (The Journal of the American Medical Association) 97, 158.
7. Clawson, B., J., Noble, J., F., and Lufkin, N., H., (1938). The Calcified Nodular Deformity of The Aortic Valve. *American Heart Journal*, 15, 58.
8. Dry, T., J., and Willius, F., A., (1939). Calcareous Disease of The Aortic Valve. *American Heart Journal*, 17, 138.
9. Hamburger, W., W., and Saphir, O., (1939). Aortic Stenosis. *Modern Concepts of Cardiovascular Disease*,
10. Edwards, J., E., (1961). An Atlas of Acquired Diseases of The Heart And Great Vessels. Philadelphia. W.B. (Walter Burns) Saunders, Co.
11. Messika-Zeitoun, D., Bielak, L., F., Peyser, P., A., et al. (2007). Aortic Valve Calcification: Determinants and Progression In The Population. *Arteriosclerosis, Thrombosis and Vascular Biology*, 27, 642-648
12. Mohler, E., R., Gannon, F., Reynolds, C., Zimmerman, R., Keane, M., et al. (2001). Bone Formation And Inflammation In Cardiac Valves. *Circulation*, 103, 1522-1528.
13. Parhami, F., Morrow, A., D., Balucan, J., et al. (1997). Lipid oxidation products have opposite effects on calcifying vascular cell and bone cell differentiation: A Possible Explanation For The Paradox of Arterial Calcification In Osteoporotic Patients. *Arteriosclerosis Thrombosis And Vascular Biology*, 17, 680-687.
14. Wylie-Sears, J., Aikawa, E., Levine, R., A., Yang, et al. (2011). Mitral Valve Endothelial Cells With Osteogenic Differentiation Potential. *Arteriosclerosis, Thrombosis And Vascular Biology*, 31, 598-607.
15. Kaden, J., J., Dempfle, C., E., Grobholz, R., et al. (2003). Interleukin-1 Beta Promotes Matrix Metalloproteinase Expression And Cell Proliferation In Calcific Aortic Valve Stenosis. *Atherosclerosis*, 170, 205-211.
16. Kaden, J., J., Dempfle, C., E., Grobholz, R., et al. (2005). Inflammatory Regulation of Extracellular Matrix Remodeling in Calcific Aortic Valve Stenosis. *Cardiovascular Pathology*, 14, 80-87
17. Winchester, R., Wiesendanger, M., O'Brien, W., Zhang, H., Z., et al. (2011). Circulating Activated And Effector Memory T Cells Are Associated With Calcification And Clonal Expansions In Bicuspid And Tricuspid Valves Calcific Aortic Stenosis. *Journal of Immunology*, 187, 1006-1014.
18. Rajamannan, N., M., Subramaniam, M., Caira, F., Stock, S., R., Spelsberg, T., C., (2005). Atorvastatin Inhibits Hypercholesterolemia-Induced Calcification In The Aortic Valves Via The Lrp5 Receptor Pathway. *Circulation*, 112, 1229-1234.
19. Rajamannan, N., M., Subramaniam, M., Rickard, D., et al. (2003). Human Aortic Valve Calcification is Associated With An Osteoblast Phenotype. *Circulation*, 107, 2181-2184.
20. Garg, V., Muth, A., N., Ransom, J., F., et al. (2005). Mutations In NOTCH 1 Cause Aortic Valve Disease. *Nature*, 437, 270-274.
21. Sacks, M., S., Schoen, F., J., (2002). Collagen Fiber Disruption Occurs Independent of Calcification In Clinically Explanted Bioprosthetic Heart Valves. *Journal of Biomedical Material Research*, 62, 359-371.
22. Matsumoto, Y., Adam, V., Walther, C., Kleinecke, C., Brugger, P., et al. (2009). Reduced Number And Function of Endothelial Progenitor Cells In Patients With Aortic Valve Stenosis: A Novel Concept For Valvular Endothelial Cell Repair. *European Heart Journal*, 30, 346-355.
23. Kovacic, J., C., Mercader, N., Torres, M., Boehm, M., et al. (2012). Epithelial-to-mesenchymal And Endothelial-to-Mesenchymal Transition From Cardiovascular Development to Disease. *Circulation*, 125, 1795-1808
24. Pira-Velazquez, S., Li, Z., Jimenez, S., A., (2011). Role of Endothelial-Mesenchymal Transition (EndoMT) In The Pathogenesis of Fibrotic Disorders. *American Journal of Pathology*, 179, 1074-1080
25. Bostrom, K., I., Rajamannan, N., H., Towler, D., A., (2001). The Regulation of Valvular And Vascular Sclerosis By Osteogenic Morphogens. *Circulation Research*, 109(5), 564-577.
26. Johnson, R., C., Leopold, J., A., Loscalzo, J., (2006). Vascular Calcification: Pathobiological Mechanisms And Clinical Implications. *Circulation Research*, 99, 1044-1059.
27. Liu, A., C., Joag, V., R., Gotlieb, A., I., (2007). The Emerging Role of Valve Interstitial Cell Phenotypes In Regulating Heart Valve Pathobiology. *American Journal of Pathology*, 171, 1407-1418.
28. Caira, F., C., Stock, S., R., Gleason, T., G., et al. (2006). Human Degenerative Valve Disease Is Associated With Up-regulation of Low-Density Lipoprotein Receptor-Related Protein 5 Receptor-Mediated Bone Formation. *Journal of American College of Cardiology*, 47, 1707-1712.
29. Kaden, J., J., Bickelhaupt, S., Grobholz, R., et al. (2004). Receptor Activator of Nuclear Factor Kappa B Ligand And Osteoprotegerin Regulate Aortic Valve Calcification. *Journal of Molecular And Cellular Cardiology*, 36, 57-66.
30. Chen, J., H., Yip, C., Y., Sone, E., D., Simmons, C., A., (2009). Identification And Characterization of Aortic Valve Mesenchymal Progenitor Cells With Robust Osteogenic Calcification Potential. *American Journal of Pathology*, 174, 1109-1119.
31. Schoppet, M., Kavurma, M., M., Hofbauer, J., L., C., Shanahan, C., M., (2011). Crystallizing Nanoparticles Derived From Vascular Smooth Muscle Cells Contain The Calcification Inhibitor Osteoprotegerin. *Biochemical And Biophysical Research Communications*, 407, 103-107.

32. Wuthis,R.,E.,Lipscomb, G.,F.,(2011). Matrix Vesicles: Structure, Composition,Formation And Function In Calcification, *Frontiers In Bioscience*, 17,2812-2902.
33. Miller,V.,M.,Rodgers,G.,Charlesworth,J.,A.,Kirkland,B.,et al. (2004). Evidence of Nanobacterial-Like Structures In Calcified Human Arteries And Cardiac Valves, *American Journal of Physiology: Heart And Circulatory Physiology*, 287, H 1115-1124.
34. Domingo,A.,Carrascal,Y.,Moter,P.,Martin-Luengo,C.,Bermejo,J., S et al.(2008). Association Between Self-Replicating Calcifying Nanoparticles And Aortic Stenosis. A Possible Link To Valve Calcification, *European Heart Journal*, 29, 371-376.
35. Schlieper,G., Kruger,T., Heiss,A.,Jahnen – Dechent,W.,(2011). A Red Herring In Vascular Calcification: 'Nanobacteria Are Protein –Mineral Complexes Involved In Biomineralization, *Nephrology Dialysis Transplantation*, 26, 3426- 3439.
36. Chen,J.,H.,Simmons, C.,A.,(2011).Cell-Matrix InteractionS In The Pathobiology of Calcific Aortic Valve Disease: Critical Roles For Matricellular, Matricrine, And Matrix *Mechanic Cues Circulation Research*, 108, 1510-1524.
37. Mazzone,A., Epistolato,M.,C., De Caterina,R., et al. (2004). Neovascularization, T-lymphocyte Infiltration And Heat Shock Protein-60 Are Biological Hallmarks of An Immunomediated Inflammatory Process In End-Stage Calcified Aortic Valve Stenosis. *Journal of American College of Cardiology*, 43, 1670-1676
38. Syvaranta, S., Helske,S., Laine,M.,Lappalainen,J., Kupari,M.,et al. (2010). Vascular Endothelial Growth Factor-Secreting Mast Cells And Myofibroblasts: A Novel Self-Perpetuating Angiogenic Pathway In Aortic Valve Stenosis. *Arteriosclerosis, Thrombosis And Vascular Biology*, 30, 1220-1227.
39. Hall, E.,M.,Ichioka,T.,(1940). Etiology of Calcified Nodular Aortic Stenosis, *American Journal of Pathology*, 16, 761.
40. Hering,D., Faber, L., Horstkotte, D., (2003). Echocardiographic Features of Radiation-Associated Valvular Disease, *American Journal of Cardiology*, 92, 226- 230
41. Harvey Feigenbaum, William F. Armstrong (2005). Feigenbaum's Echocardiography, Sixth Edition, Mitral Valve Disease, Chapter,11, Figure 11.95, Page 350.
42. Mohammad Raza Akram, Tze Chan, Susan McAuliffe, Adrian Chenzbraun (2009). Non-Rheumatic Annular Mitral Stenosis: Prevalence And Characteristics, *European Journal of Echocardiography*, 10(1), 103-105, Figure 1, Figure 2.
43. Miller,J.,D., Weiss,R.,M., Heistad,D.,D.,(2011). Calcific Aortic Valve Stenosis: Methods, Models, And Mechanisms. *Circulation Research*, 108, 1392-1412.
44. Gotoh,T., Kuroda,T., Yamasawa,M.,et al. (1995). Correlation Between Lipoprotein (a) And Aortic Valve Sclerosis Assessed By Echocardiography(The JMS Cardiac Echo And Cohort Study), *American Journal of Cardiology*, 76, 928-932.
45. Capuzzi,D.,M.,Guyton,J.,R.,Morgan,J.,M.,et al. (1998).Efficacy And Safety of An Extended-Release Niacin(Niaspan): A Long-Term Study, *American Journal of Cardiology*, 82, 74 U-81 U
46. Merki, E., Graham,M.,Taleb,A.,et al. (2011).Antisense Oligonucleotide Lowers Plasma Levels of Apolipoprotein (a) And Lipoprotein (a) In Transgenic Mice, *Journal of American College of Cardiology*, 57, 1611-1621.
47. Rajamannan,N.,M.,Subramaniam,M.,Springett,M.,Sebo,T.,et al. (2002). Atorvastatin Inhibits Hypercholesterolemia-Induced Cellular Proliferation And Bone Matrix Production In The Rabbit Aortic Valve, *Circulation*, 105, 2660-2665.
48. Rossebo,A.,B., Pedersen,T.,R.,Boman,K., et al. (2008).Intensive Lipid Lowering With Simvastatin And Ezetimibe In Aortic Stenosis, *New England Journal of Medicine*, 359, 1343-1356.
49. Cowell,S.,J.,Newby,D.,E.,Prescott,R.,et al. (2005). A Randomized Trial of Intensive Lipid-Lowering Therapy In Calcific Aortic Stenosis, *New England Journal of Medicine*,352, 2389-2397.
50. Chan,K.,L.,Teo,K.,Dumesnil,J.,G.,et al. (2010). Effect of Lipid Lowering With Rosuvastatin On Progress of Aortic Stenosis: Results of The Aortic Stenosis Progression Observation: Measuring Effects of Rosuvastatin (ASTRONOMER) Trial. *Circulation*,121, 306-314.
51. Mundy,G., Garrett,R., Harris,S., Chan,J., Chen,D., et al. (1999). Stimulation Of Bone Formation In Vitro And In Rodents By Statins, *Science*, 286, 1946-1949.
52. Miller,J.,D.,Weiss,R.,M.,Serrano,et al. (2009).Lowering Plasma Cholesterol Levels Halts Progression of Aortic Valve Disease In Mice, *Circulation*,119,2693-2701.
53. Yao,Y.,Bennett,B.,J.,Wang,X.,Rosenfeld,M.,et al. (2010). Inhibition of Bone Morphogenetic Proteins Protects Against Atherosclerosis And Vascular Calcification, *Circulation Research*, 107, 485-494.
54. Lemer,R.,G., Aronow,W.,S., Sekhri,A., et al. (2009).Warfarin Use And The Risk of Valvular Calcification, *Journal of Thrombosis and Haemostasis*, 7, 2023-2027
55. Jahnen-Dechent,W., Heiss,A., Schafer,C., Ketteller,M., (2011). Fetuin-A Regulation of Calcified Matrix Metabolism, *Circulation Research*, 108,1494-1509.
56. Kaden,J.,J., Reinohl,J.,O., Blesch,B., et al (2007).Systemic And Local Levels of Fetuin-A in Calcific Aortic Valve Stenosis, *International Journal of Molecular Medicine*, 20,193-197.
57. Ix,J.,H.,Chesrow,G.,M.,Shlipak,M.,et al. (2007). Association of Fetuin -A With Mitral Annular Calcification And Aortic Stenosis Among Persons With Coronary Heart Disease: Data From *The Heart And Soul Study*, *Circulation*,115, 2533-2539
58. Anderson,K.,R.,Sutton,M.,G.,Lie, et al. (1979). Histopathological Types of Cardiac Fibrosis In Myocardial Disease, *Journal of Pathology*, 128, 79-85.
59. Briand,M.,Dumesnil,J.,G., Kadem,L., Tongue,A.,et al. (2005).Reduced Systemic Arterial Compliance Impacts Significantly On Left Ventricular Afterload And Function In Aortic Stenosis: Implications For Diagnosis And Treatment, *Journal of American College of Cardiology*,46, 291-298.
60. O'Brien,K.,D.,Shavelle,D.,M., Caulfield,M.,T., et al. (2002). Association of Angiotensin –Converting Enzyme With Low-Density Lipoprotein In Aortic Valvular Lesions And In Human Plasma, *Circulation*, 106, 2224-2230.
61. Orłowska-Baranowska,E.,Placha,G., Gaciong,Z., et al. (2004). Influence of ACE 1/D Genotypes On Left Ventricular Hypertrophy In Aortic Stenosis: Gender-Related Differences, *Journal of Heart Valve Disease*,13, 574-581.
62. O'Brien,K.,D.,Probstfeld,J.,L.,Caulfield,M.,T., et al. (2005).Angiotensin-Converting Enzyme Inhibitors And Change In Aortic Valve Calcium, *Archives of Internal Medicine*, 165, 858-862.
63. Nadir,M.,A.,Wei,L., Elder,D.,H., et al. (2011). Impact of Renin-Angiotensin System Blockade Therapy On Outcome In Aortic Stenosis, *Journal of American College of Cardiology*, 58, 570-576.

64. Cote,N., Couture,C., Pibarot,P., Despres,J.,P.,et al. (2011).Angiotensin Receptor Blockers Are Associated With A Lower Remodeling Score of Stenotic Aortic Valves, *European Journal of Clinical Investigation*,41, 1172-1179
65. Arishiro,K., Hoshiga, M., Negoro,N., et al. (2007). Angiotensin Receptor-1 Blocker Inhibits Atherosclerotic Changes And Endothelial Disruption of The Aortic Valve In Hypercholesterolemic Rabbits, *Journal of American College of Cardiology*, 49, 1482-1489.
66. Newby,D.,E., Cowell,S.,J.,Boon,N.,A.,(2006). Emerging Medical Treatments For Aortic Stenosis: Statins, Angiotensin Converting Enzyme Inhibitors, or Both? *Heart*, 92, 729-734
67. Sattler,A.,M., Schoppet,M., Schaefer,J.,R.,Hofbauer,et al (2004).Novel Aspects on RANK Ligand and Osteoprotegerin In Osteoporosis And Vascular Disease, *Calcified Tissue International*, 74,103-106
68. Bucay,N.,Sarosi,I.,Dunstan,C.,R.,et al.(1998). Osteoprotegerin-Deficient Mice Develop Early Onset Osteoporosis And Arterial Calcification, *Genes & Development*, 12, 1260-1268
69. Price,P.,A.,Faus,S.,A.,Williamson,M.,K.,(2001). Bisphosphonates: Alendronate And Ibandronate Inhibit Artery Calcification At Doses Comparable to Those That Inhibit Bone Resorption, Arteriosclerosis, *Thrombosis, And Vascular Biology*,21, 817-824.
70. Rapoport,H.,S.,Connolly,J.,M., Fulmer,J.,et al. (2007). Mechanisms of The In Vivo Inhibition of Calcification of Bioprosthetic Porcine Aortic Valve Cusps And Aortic Wall With Triglycidylamine/Mercapto Bisphosphonate, *Biomaterials*, 28, 690- 699.
71. Aksoy,O., Cam,A., Goel,S.,S.,Houghtaling,P.,et al. (2012).Do Bisphosphonates Slow The Progression of Aortic Stenosis? *Journal of American College of Cardiology*,59, 1452-1459.
72. Xue,T., Mao,Z., Lin,L.,Hou, Y., Wei,X., et al. (2010). Non-Virus-Mediated Transfer of siRNAs Against Runx2 And Smad 4 Inhibit Heterotopic Ossification In Rats, *Gene Therapy*, 17,370-379.
73. Lin,L.,Chen,L.,Wang,H.,Wei,X., Fu,X., et al. (2006).Adenovirus-Mediated Transfer of siRNA Against Runx2/Cbfa1 Inhibits The Formation of Heterotopic Ossification In Animal Model, *Biochemical And Biophysical Research Communications*, 349, 564-572.
74. Lin Lin, Qi Shen,Huijie Leng, Xiaoning Duan, Xin Fu, and Changlong Yu. (2011). Synergistic Inhibition of Endochondral Bone Formation by Silencing Hif1 $\alpha$  and Runx2 in Trauma-induced Heterotopic Ossification, *Molecular Therapy*, 19(8), 1426-1432
75. Bing Tu, Shen Liu, Bo Yu, Jing Zhu Hongjiang Ruan, Tingting Tang. et al. (2016). miR-203 inhibits the traumatic heterotopic ossification by targeting Runx2, *Cell Death & Disease*, 7(10), e 2436.
76. Swati Mishra, Asa D. Vaughn, David I. Devore, and Charles M. Roth. (2012). Delivery of siRNA Silencing Runx2 Using a Multifunctional Polymer-Lipid Nanoparticle Inhibits Osteogenesis in a Cell Culture Model of Heterotopic Ossification, *Integrative Biology (Cambridge)*. 4(12): 1498–1507.
77. Steitz,S.,A.,Speer,M.,Y.,Mckee,M.,et a.l (2002).Osteopontin Inhibits Mineral Deposition And Promotes Regression of Ectopic Calcification, *American Journal of Pathology*, 161,2035-2046.
78. Smits,P.,C.,Van Geuns,R.,J., Poldermans,D., et al. (2003).Catheter-Based Intramyocardial Injection of Autologous Skeletal Myoblasts As A Primary Treatment of Ischemic Heart Failure: Clinical Experience With Six-Month Follow-Up, *Journal of American College of Cardiology*, 42, 2063-2069.
79. Csoka,A.,B., Cao,H., Sammak,P.,J, Constantinescu,D., et al. (2004). Novel Lamin A/C Gene(LMNA) Mutations in Atypical Progeroid Syndrome, *Journal of Medical Genetics*, 41, 304-308.
80. Natesh,B., Hanumanthappa, Ganigara Madhusudan, Jeyaranganath Mahimarangaiah, Cholenahally Manjunath,N.,(2011).Hutchinson-Gilford Progeria Syndrome With Severe Calcific Aortic Valve Stenosis, *Annals of Pediatric Cardiology*, 4(2), 204-206.
81. Merideth,M.,A., Gordon, L.,B., Clauss,S., et al. (2008). Phenotype And Course of Hutchinson-Gilford Progeria Syndrome, *New England Journal of Medicine*, 358, 592-604.
82. Ravindranath, et al. (2009). Balloon Mitral Valvotomy (BMV) For Calcific Mitral Stenosis, *Cardiovascular Interventions, Journal of American College of Cardiology*, 2(3), 263-264.
83. Dugal,J.,S.,Jetley,V., Sabharwal,J,S., Sofat,S., et al. (2003). Life-Saving PTMC for Critical Calcific Mitral Stenosis in Cardiogenic Shock with Balloon Impasse,5, 172-174.
84. Goldman J.,H., Slade A., Clague J.,(1998). Cardiogenic shock secondary to mitral stenosis treated by balloon mitral valvuloplasty. *Catheterization And Cardiovascular Diagnosis*.43(2):195-197
85. Webb, J.,G., Altwegg L, Boone, R.,H., et al. (2009). Transcatheter aortic valve implantation: impact on clinical and valve-related outcomes. *Circulation*,119:3009–3016.
86. Guerrero,M., Greenbaum,A., O'Neill,W.,(2014). First In Human Percutaneous Implantation of a Balloon Expandable Transcatheter Heart Valve in a Severely Stenosed Native Mitral Valve, *Catheterization And Cardiovascular Interventions*, 4,83, E287-291.
87. Lim, Z.,Y.,Boix,R.,Prendergast,B.,et al. (2015).First Reported Case of Transcatheter Mitral Valve Implantation In Mitral Annular Calcification With a Fully Repositionable And Self-Expanding Valve , *Circulation: Cardiovascular Interventions* , 8, e003031.
88. Guerrero,M., Dvir,D., Himbert,D., et al. (2016).Transcatheter Mitral Valve Replacement In Native Mitral Valve Disease With Severe Mitral Annular Calcification: Results From The First Multicenter Global Registry, *Journal of American College of Cardiology: Cardiovascular Interventions*, 9, 1361-1371.
89. Carabello,B.,A., Crawford,F.,A., Jr. (1997). Valvular Heart Disease, *New England Journal of Medicine*,337, 32-41.
90. Pellika,P.,A., Sarano,M.,E.,Nishimura,R.,A.,et al. (2005). Outcome of 622 Adults With Asymptomatic, Hemodynamically Significant Aortic Stenosis During Prolonged Follow-Up. *Circulation*,11, 3290-3295.
91. Chaliki,H.,P.,Brown,M.,L.,Sundt,T.,et al.(2007).Timing of Operation In Asymptomatic Severe Aortic Stenosis, *Expert Review of Cardiovascular Therapy*, 5, 1065-1071.
92. Pai,R.,G.,Kapoor,N.,Bansal, R.,C., et al. (2006). Malignant Natural History of Asymptomatic Severe Aortic Stenosis: Benefit of Aortic Valve Replacement , *Annals of Thoracic Surgery*, 82, 2116-2122.
93. Justin Van Meeteren, Hartzell Schaff (2017).Extracardiac Valved Conduit for Calcific Mitral Stenosis, CTS Net.
94. El-Hamamsy,I., Eryigit,Z., Stevens,L.,M., Sarang,Z., et al. (2010). Long-Term Outcomes After Autograft Versus

- Homograft Aortic Root Replacement in Adults With Aortic Valve Disease: A Randomised Controlled Trial, *Lancet*, 376, 524-531
95. Sohail,G Contractor, Eugene C Lin (2015). Valvular Calcificatio Overview, Imaging of Cardiac Calcification, Medscape.
96. Osborne Bartley (1958). Cardiac Valve Calcification And Registration of Their Movements, *Acta Radiologica*, 49(5), 329-347.
97. Mohammad Abbasi Teshnizi, Atefeh Ghorbanzadeb, Nahid Zirak, Babak Manafi, Aliasghar, et al. (2017). Cardiac Calcified Amorphous Tumor of Mitral Valve Presenting As Transient Ischemic Attack, Case Reports in Cardiology, Article ID 2376096.



This work is licensed under Creative Commons Attribution 4.0 License

To Submit Your Article Click Here:

**Submit Manuscript**

DOI:10.31579/2690-8794/286

**Ready to submit your research? Choose Auctores and benefit from:**

- fast, convenient online submission
- rigorous peer review by experienced research in your field
- rapid publication on acceptance
- authors retain copyrights
- unique DOI for all articles
- immediate, unrestricted online access

At Auctores, research is always in progress.

Learn more <https://auctoresonline.org/journals/clinical-medical-reviews-and-reports>