

Idiopathic Calciphylaxis Associated with long-Term use of Coumadin in a Non-Uremic Patient

Anupam K. Gupta

General and Minimally Invasive Surgery SSM Health Mt. Vernon.

***Corresponding Author:** Anupam K. Gupta., General and Minimally Invasive Surgery SSM Health Mt. Vernon.

Received Date: April 21, 2025; **Accepted Date:** May 01, 2025; **Published Date:** May 15, 2025

Citation: Anupam K. Gupta, (2025), Idiopathic Calciphylaxis Associated with long-Term use of Coumadin in a Non-Uremic Patient, *Clinical Medical Reviews and Reports*, 7(3); DOI:10.31579/2690-8794/257

Copyright: © 2025, Anupam K. Gupta. This is an open access article distributed under the Creative Commons Attribution License, which permits unrestricted use, distribution, and reproduction in any medium, provided the original work is properly cited.

Abstract

Introduction: Warfarin is a vitamin K antagonist anticoagulant and is the preferred mode of anticoagulation in patients with mechanical heart valves. It is known to cause skin lesions infrequently, such as coumadin-induced skin necrosis or calciphylaxis, in uremic patients.

Case Presentation: A 78-year-old lady with a body mass index of 39 kg/m² and mechanical aortic valves after 10 years of Coumadin use presented with multifocal skin necrosis and painful subcutaneous calcification.

Discussion: This case report illustrates the idiopathic formation of cutaneous and subcutaneous painful calcified lesions despite long-term strict INR (international normalized ratio) control in nonuremic patients with no triggering factors.

Conclusion: Calciphylaxis with long-term coumadin use in nonuremic patients is unusual.

Keywords: coumadin; skin necrosis; calciphylaxis; calcinosis cutis

Introduction

Coumadin is a vitamin K antagonist anticoagulant that requires a narrow therapeutic range to maintain the anticoagulant effect [1]. Coumadin blood levels can vary with interaction with other medications and dietary factors [2,3]. Coumadin-induced skin necrosis is Infrequent, but timing is usually during the initiation of Coumadin in the 1st few days [4]. Pathophysiologic is due to decreased protein C levels, leading to a hypercoagulable state and skin necrosis [4]. Calciphylaxis, a rare disorder characterized by vascular calcification of the microvessels and subcutaneous tissue resulting in ischemic skin necrosis, has also been shown to occur in patients with Coumadin use and renal failure [5]. This lesion is associated with high morbidity and mortality, with an estimated 6-month survival of only 50% and no approved management guidelines [6]. Both lesions appear as necrotic

skin lesions [3,6]. This case report describes a nonuremic patient on long-term Coumadin developing calciphylaxis in a multifocal pattern without a known triggering factor and its persistence despite holding Coumadin.

Case report

78-year-old white Caucasian lady with a body mass index of 39 kg/m², past medical history of hypertension, hyperlipidemia, rheumatoid arthritis, past surgical history of mechanical aortic valve placement in 2014 and coronary artery bypass graft in 2017, Presented with indurated skin lesions on the bilateral thigh and multiple sites on the abdominal wall for over six months duration (figure 1).

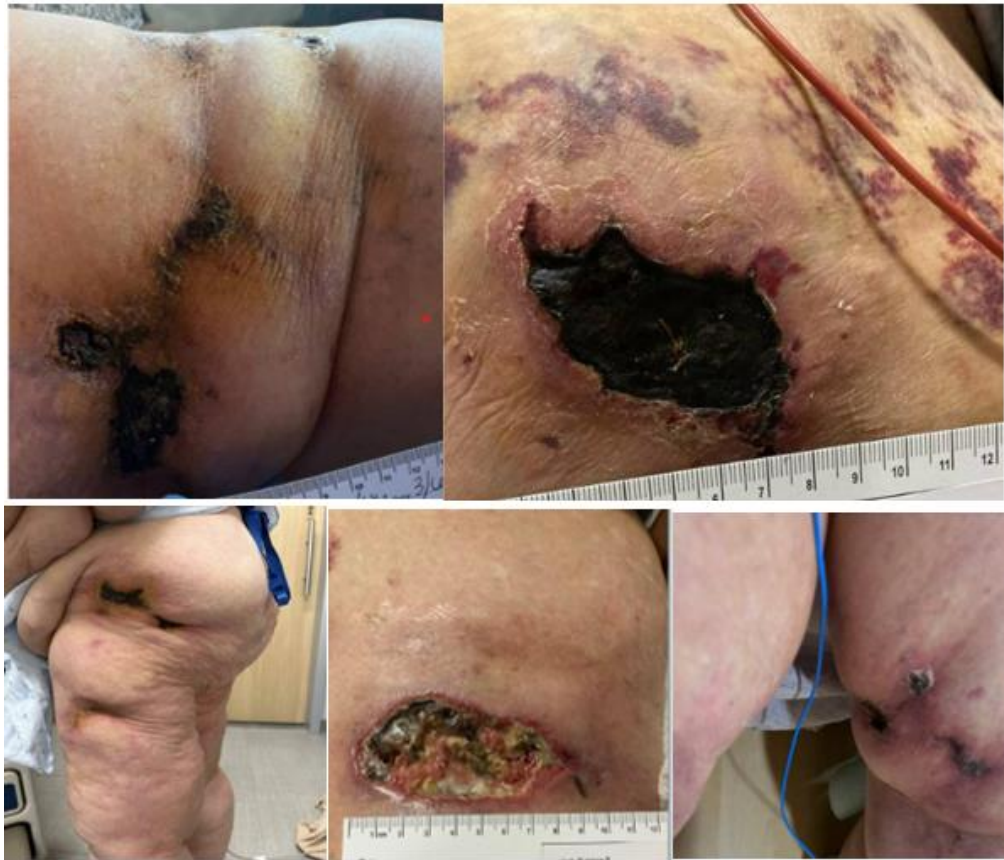

Figure 1: clockwise lesion seen on the left flank, anterior abdominal wall, left thigh, and right thigh. Left flank.

These skin lesions initially presented with induration on her flanks and anterior abdominal wall. Subsequently, they progressed to hyperpigmentation of the skin and then evidence of necrosis associated with pain and tenderness to palpation. Once the skin lesions were associated with

skin breakdown and the development of necrosis with infection, the patient needed surgical debridement. Histologically, there was evidence of dermal necrosis and micro-vascular calcification (figure 2).

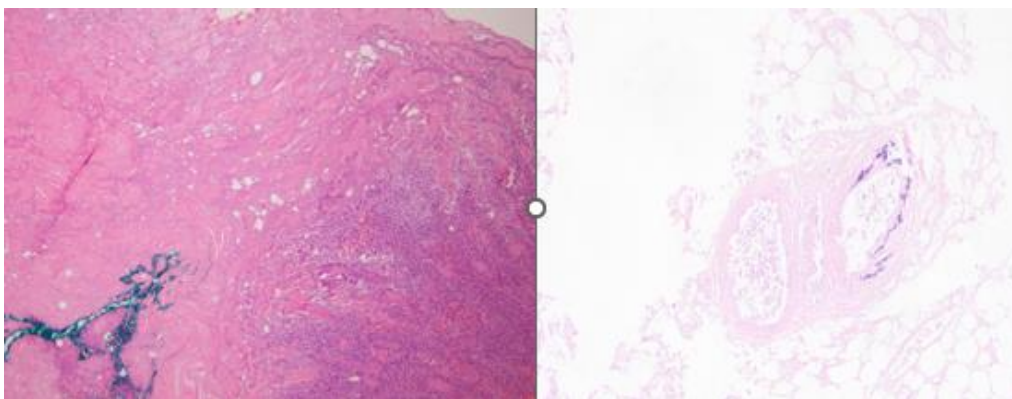


Figure 2: left image – dermal necrosis, right image vascular calcification.

Her medication history included Coumadin, metoprolol, empagliflozin, folic acid, pantoprazole, pravastatin, lasix, alendronate, oxycodone, polyethylene glycol, oxybutynin, vitamin D3, and Tylenol. She was on Coumadin for over 10 years before her current symptomatology started, with INR levels well controlled between 2 and 3.5. Her blood work at the time of diagnosis revealed a noncontributory blood picture, and blood chemistry, including calcium and phosphorus levels, were within normal range limits over the last year. A review of her renal panel over multiple years revealed

creatinine (less than one during the previous 10 years). Her calcium level for numerous years was within normal parameters for the laboratory; her internalized standard ratio under Coumadin revealed a level between 2 and 3.5 levels during the last 10 years. She had blood work within the normal range of parathormone, protein C antigen, and protein S antigen levels of laboratory parameters. A sestamibi scan did not show evidence of parathyroid overactivity. Due to necrotic skin lesions, her Coumadin was stopped for 30 days while she transitioned to Lovenox. The lesions remained stable and showed no evidence of regression; the patient had poor

compliance with Lovenox, given the development of hematoma at the injection site. She gradually transitioned back to Coumadin under heparin. A follow-up after 45 days remains the persistence of the lesions in the same clinical stage with no obvious progression.

Discussion

Coumadin is a vitamin K antagonist which prevents gamma-carboxylation of vitamin K-dependent coagulation factors [6]. One of the significant indications of Coumadin is its use in mechanical heart valve patients to avoid clot formation. Coumadin requires titration to maintain anticoagulant levels through INR monitoring. The desired targeted INR for mechanical aortic heart valve patients is 2.5 to 3.5 [7]. In our report, our patient used a self-portable device to regularly monitor her INR levels and those observed during her clinic visit. Factors II, VII, IX, and X are inhibited by Coumadin, preventing their combination with the calcium required for proper hemostatic function. Coumadin also inhibits gamma-carboxylation of protein C and protein S, innate anticoagulants. Patients with protein C deficiency receiving Coumadin may have an initial transient procoagulant effect, which can lead to thrombus formation in the microvasculature of the skin, leading to skin necrosis [1,8]. Coumadin-induced skin necrosis is usually seen in the 1st few days of initiating Coumadin. Patients with Coumadin-induced skin necrosis have shown an association with deficiency of protein C and protein S levels, a mutation, and factor 5 Leiden [9]. Calcification that occurs in the skin and subcutaneous tissue is referred to as calcinosis cutis. Calciphylaxis is a life-threatening condition with characteristic calcification of skin, subcutaneous tissue, vascular structures, and internal organs, which is usually seen in the setting of end-stage renal disease. Calciphylaxis has also been reported in patients without end-stage renal disease [10,11]. Calciphylaxis has been shown to occur in patients with non-end-stage renal disease and in post-renal transplants. There has been reported incidence of calciphylaxis in female sex with a body mass index over 30, hyperphosphatemia, deficiency of protein C protein S diabetes, etc. The underlying mechanism of this condition is not yet fully understood [12,13]. Histologically, it is characterized by calcification of skin and subcutaneous tissue arterioles, leading to skin ischemia and pain [14]. There has been an association of calciphylaxis with obese female patients with a prior history of Coumadin use, as in our patient. Even though it has been described in the literature, coumadin-associated calcification has largely been poorly understood in patients who have normal calcium, phosphorus, and electrolyte levels without end-stage renal disease. There is evidence of calcification and arterials and blood vessels of skin and subcutaneous tissue [14,15,17]. There is no standardized management protocol for calciphylaxis, and a multidisciplinary approach with surgical debridement or excision, use of sodium thiosulfate topically or intralesionally, hyperbaric oxygen, and bisphosphonates have been described with varying degrees of success [18]. A review of our patient's record revealed she had normal renal function with no triggering factor to the development of lesions.

Conclusion

Long-term use of Coumadin can be linked to multifocal, multicentric calciphylaxis, even with strict INR control, normal renal function, and a normal calcium profile. In our patient, temporarily stopping Coumadin did not lead to a regression of the lesion.

Disclosure

Dr. Anupam K Gupta, MD has no conflicts of interest or financial ties to disclose

No funding was received for this work.

NO IRB/Ethical approval was needed -This is a case report and does not meet the criteria for research.

References

1. Idelzuita Leandro Liporace, Gustavo Bernardes F. Oliveira, Lucas Bassolli de Oliveira Zlves, Nadia Marchiori Galassi, Andreia Dias Jeronimo, et.al (2025). Incidence and Predictors of Clinical Outcomes in Patients with Valvular and Nonvalvular Atrial Fibrillation Using Vitamin K Antagonists, Arquivos Brasileiros de Cardiologia, 122, 2.
2. Gupta AK, Parker BM, Ross AS. (2020). Rectus Sheath Hematoma Causing Bladder Outlet Obstruction. *Cureus*. 12(5): e7974.
3. Custódio das Dôres SM, Booth SL, Martini LA, de Carvalho Gouvêa VH, Padovani CR, et.al (2007). Relationship between diet and anticoagulant response to warfarin: a factor analysis. *Eur J Nutr*. 46(3):147-154.
4. Kakagia DD, Papanas N, Karadimas E, Polychronidis A. (2014). Warfarin-induced skin necrosis. *Ann Dermatol*. 26(1):96-98.
5. Saifan C, Saad M, El-Charabaty E, El-Sayegh S. (2013). Warfarin-induced calciphylaxis: a case report and review of literature. *Int J Gen Med*. 6:665-669.
6. Udomkarnjananun S, Kongnatthasate K, Praditpornsilpa K, Eiam-Ong S, Jaber BL, et.al (2018). Treatment of Calciphylaxis in CKD: A Systematic Review and Meta-analysis. *Kidney Int Rep*. 4(2):231-244.
7. Rishavy MA, Hallgren KW, Wilson L, Singh S, Runge KW, et.al (2018). Warfarin alters vitamin K metabolism: a surprising mechanism of VKORC1 uncoupling necessitates an additional reductase. *Blood*. 131(25):2826-2835.
8. Ryu R, Tran R. (2022). DOACs in Mechanical and Bioprosthetic Heart Valves: A Narrative Review of Emerging Data and Future Directions. *Clin Appl Thromb Hemost*. 28:10760296221103578.
9. Gupta AK, Parker BM, Ross AS. (2020). Rectus Sheath Hematoma Causing Bladder Outlet Obstruction. *Cureus*. 12(5): e7974.
10. Ng T, Tillyer ML. (2001). Warfarin-induced skin necrosis associated with Factor V Leiden and protein S deficiency. *Clin Lab Haematol*. 23(4):261-264.
11. Bachu R, Patel TH, Hemmings S. (2022). Calciphylaxis in End-Stage Renal Disease: A Rare Condition with High Mortality. *Cureus*. 14(7): e26752.
12. Guillén-Olmos E, Torregrosa JV, Garcia-Herrera A, Ganau S, Diekmann F, et.al (2021). Development of calciphylaxis in kidney transplant recipients with a functioning graft. *Clin Kidney J*. 15(4):663-671.
13. Gupta A, Rubay D, Lodin D, Borrego R, Lottenberg L. (2019). Combined Extra- and Intrapleural Hematoma After Blunt Chest Injury in an Anticoagulated Patient. *Cureus*. 11(8): e5506.
14. Saifan C, Saad M, El-Charabaty E, El-Sayegh S. (2013). Warfarin-induced calciphylaxis: a case report and review of literature. *Int J Gen Med*. 6:665-669.
15. Tsung-Yu Ko, Chih-Cheng Wu, Mu-Yang Hsieh, Chung-Wei Yang, Chi-Hung Cheng, et.al (2025). A randomized controlled trial evaluated the efficacy and safety of apixaban for prevention

- of recurrent thrombosis after thrombectomy of hemodialysis vascular access, *Kidney International*, 107, 2, (348-358).
16. Wang X, Peng L, Ma J, Zhang L, Liu J. (2022). Warfarin-Induced Calcification: Potential Prevention and Treatment Strategies. *Rev Cardiovasc Med*.23(9):322.
17. Moghadamyeghaneh Z, Chen LJ, Alameddine M, Gupta AK, Burke GW, et.al (2017). Never events and hospital-acquired conditions after kidney transplant. *Can Urol Assoc J*.11(11): E431-E436.
18. Udomkarnjananun S, Kongnatthasate K, Praditpornsilpa K, Eiam-Ong S, Jaber BL, et.al (2018). Treatment of Calciphylaxis in CKD: A Systematic Review and Meta-analysis. *Kidney Int Rep*.4(2):231-244.



This work is licensed under Creative Commons Attribution 4.0 License

To Submit Your Article Click Here:

Submit Manuscript

DOI:10.31579/2690-8794/257

Ready to submit your research? Choose Auctores and benefit from:

- fast, convenient online submission
- rigorous peer review by experienced research in your field
- rapid publication on acceptance
- authors retain copyrights
- unique DOI for all articles
- immediate, unrestricted online access

At Auctores, research is always in progress.

Learn more <https://auctoresonline.org/journals/clinical-medical-reviews-and-reports>