

# Case Report: Homozygous Familial Hypercholesterolemia: A clinical report of a male from 12 to 36 years of life

Kurt Widhalm\*, Karin Fallmann

Austrian Academic Institute for Clinical Nutrition Alserstraße 14/4a, 1090 Vienna.

**\*Corresponding Author:** Kurt Widhalm, Medical University of Vienna, 1090 Vienna Austrian Academic Institute for Clinical Nutrition Alserstraße 14/4a, 1090 Vienna.

**Received Date:** June 03, 2025 | **Accepted Date:** June 17, 2025 | **Published Date:** July 11, 2025

**Citation:** Kurt Widhalm, Karin Fallmann, (2025), Case Report: Homozygous Familial Hypercholesterolemia: A clinical report of a male from 12 to 36 years of life, *International Journal of Clinical Case Reports and Reviews*, 27(3); DOI:10.31579/2690-4861/865

**Copyright:** © 2025, Kurt Widhalm. This is an open-access article distributed under the terms of the Creative Commons Attribution License, which permits unrestricted use, distribution, and reproduction in any medium, provided the original author and source are credited.

## Abstract:

Familial hypercholesterolemia is an autosomal dominant inherited metabolic disorder characterized by elevated plasma levels of low-density lipoprotein cholesterol (LDL-C). These increased levels lead to atherosclerosis, premature cardiovascular disease, and an elevated risk of mortality. Despite its high prevalence, long-term data on affected patients remains limited.

This case report presents the lifelong clinical history of a patient diagnosed with homozygous familial hypercholesterolemia (hoFH). The boy, born in 1965, had repeated syncopal episodes from the age of nine years, leading to the diagnosis of severe hypercholesterolemia.

This historical report illustrates the challenges of managing hoFH. It highlights the role of plasmapheresis and LDL-apheresis in prolonging survival and maintaining quality of life. The case underlines the importance of early intervention and newer pharmacological approaches in extending life expectancy, beyond previously reported averages of approx. 33 years life expectancy for hoFH patients.

**Key words:** homozygous familial hypercholesterolemia; historical report; lifelong treatment

## Introduction

Familial hypercholesterolemia (FH) is a frequently occurring autosomal co-dominant inherited metabolic disorder characterized by elevated plasma levels of low-density lipoprotein cholesterol (LDL-C). [1] Over time, excess LDL-C accumulates within the intima-media of arteries, leading to the formation of atherosclerotic plaques. Consequently, individuals affected by this disorder face a significantly higher risk of early-onset cardiovascular disease (CVD). [2]

The estimated prevalence of heterozygous FH (heFH) ranges between 1 in 200 and 1 in 330, whereas homozygous FH (hoFH) is far rarer, with estimates ranging from 1 in 160,000 to 1 in 300,000. [3,4] Despite a strong consensus that initiating treatment as early as possible significantly reduces cardiovascular risk, FH remains severely underdiagnosed and undertreated. Alarming, approximately 90% of affected individuals remain undiagnosed, resulting in a lack of proper intervention and treatment. [5]

FH arises from mutations in genes encoding proteins involved in LDL-C metabolism. The severity of FH depends on the specific mutation and

zygosity. Individuals who inherit two mutated alleles develop homozygous FH (hoFH), which presents the most severe phenotype, with a life expectancy of approximately 30 years. [6,7,8]

The clinical manifestation of FH is highly variable. Although in affected individuals atherosclerosis develops in childhood and adolescence, noticeable clinical symptoms typically do not appear until advanced atherosclerosis has formed. FH is characterized by cutaneous manifestations, including xanthomas, xanthelasmas, corneal arcus, and tendon xanthomas, which represent cholesterol deposits in various tissues. [9,10,11]

The treatment of FH consists of a lifestyle modification, including a low-fat diet, regular physical activity, and nicotine avoidance and a pharmacological therapy, involving statins, ezetimibe, or PCSK9 inhibitors. [8,12] A third treatment approach involves invasive therapy, such as LDL apheresis, which is primarily reserved for individuals with hoFH or severe heFH, who exhibit inadequate response to conventional treatments. [13]

Although there is universal consensus on the importance of early treatment in FH, long-term outcome data for patients diagnosed in childhood or adolescence remain limited.

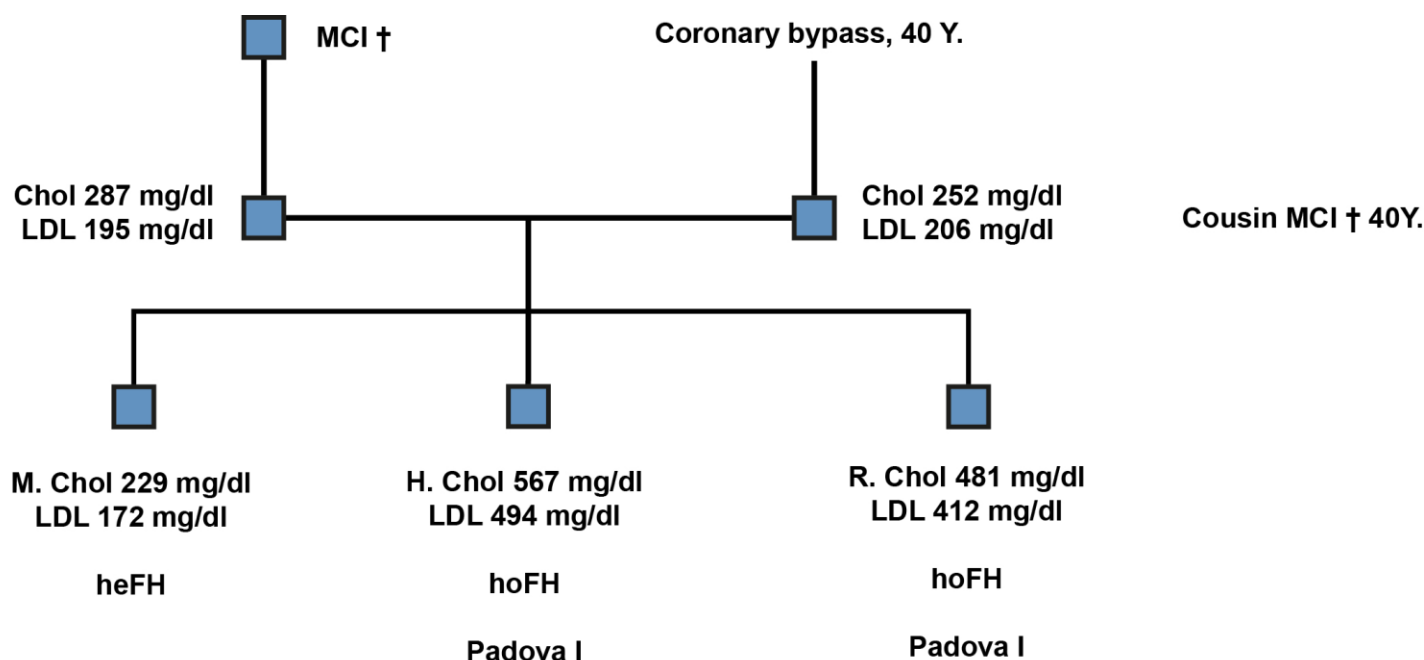
### Case Presentation

The patient was born on 13 August 1965 with normal delivery and normal postnatal development.

Family history: both parents have hypercholesterolemia, one brother has an extreme hypercholesterolemia; moderate hypercholesterolemia of another brother and a sister. Grandfather died due to myocardial infarction. Uncle (brother of the mother) had coronary bypass surgery at the age of 40 years. Cousin of the mother died due to myocardial infarction at the age of 40 years.

Person	Chol mg/dl	VLDL mg/dl	HDL mg/dl	LDL-c mg/dl	FH	TG mg/dl	VLDL mg/dl	HDL mg/dl	LDL mg/dl
Patient	567	38	44	494	homo. Padova I	Brother	567	38	44
Mother	252	25	27	206	hetero.		41	23	97
Brother	229	21	40	172	hetero.		34	23	32
Brother	481	23	54	412	homo. Padova I		25	21	42
Father	287	35	49	195	hetero.		88	33	65
Cousin (mother)	367	49	41	267	hetero.		95	29	107
Cousin (mother)	355	30	45	274	hetero.		79	24	69

**Table 1:** Family Tree, laboratory values



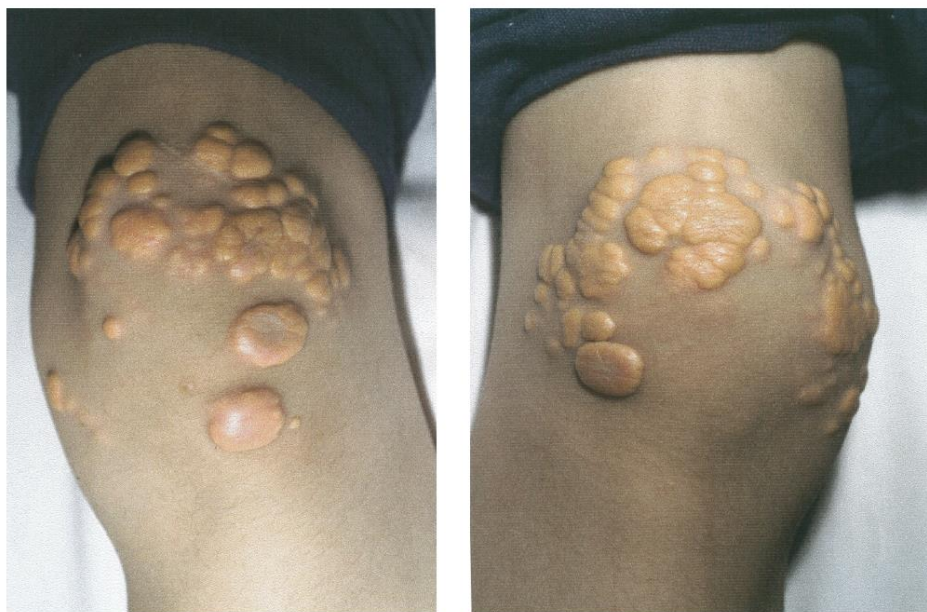**Figure 1:** Family Tree

The boy has been described by his mother as healthy until the age of approx. 9 years. From this age he had repeated syncopes with complete amnesia. Therefore, in a rural hospital, a complete check-up has been done and a hypercholesterolemia has been diagnosed, but no evidence for the syncopes have been found.

At the age of 9,5 years a further clinical examination has been done at a paediatric department of a university clinic in Austria; the diagnosis of "hypercholesterolemia" has been confirmed and a diet has been prescribed.

At the age of 10 years multiple xanthomas on the elbows and on the knees and tuberosus xanthomas on both achilles tendons have been observed; furthermore a arcus lipoids on both eyes. (Figure. 2)

At the age of 10 years the patient came for a second opinion to the department of paediatrics at the University of Vienna division metabolic diseases, and the clinical diagnosis of a homozygous form of familial hypercholesterolemia has been settled.



**Figure 2:** Multiple Xanthomas on the knees and elbows

Diagnosis of hoFH (LDL-binding from fibroblasts) Null-binding. (D.F. Bernini, Univ. Milano) Genetic diagnosis (Prof. Dr. G. Kostner, Graz): Exon 4,2 d 200g; A > G in D221G FH Padova1

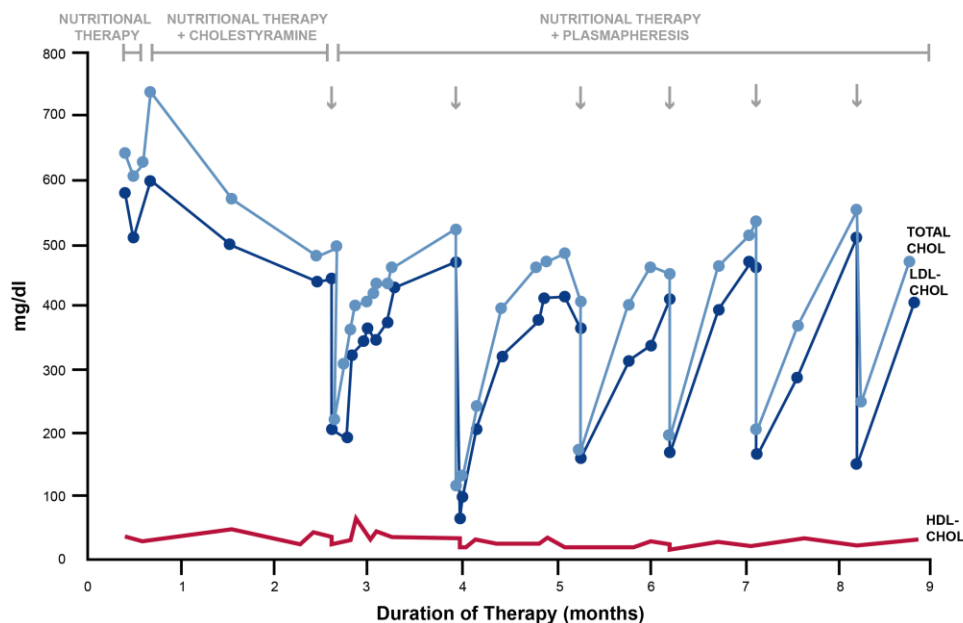
#### FH therapy

At the age of 12 years the patient has been admitted at the Univ. Clinic Vienna after an unsuccessful period of strict diet therapy treatment with Cholestyramine has been started. By means of a myocardial Scan a retrospective diagnosis of a myocardial infarction was possible.

1982, at the age of 16 years, the first Coronary Angiography was performed: left coronary artery completely occluded, diagonal vessels show atherosclerotic lesions.

After this clear diagnosis of severely affected coronary vessels and the unsuccessful treatment with Cholestyramine a plasma exchange treatment has been started.

Total cholesterol and LDL-Cholesterol levels could be lowered from approx. 700 / 600 mg/dl down to 360 / 308 mg/dl. (Figure 3)



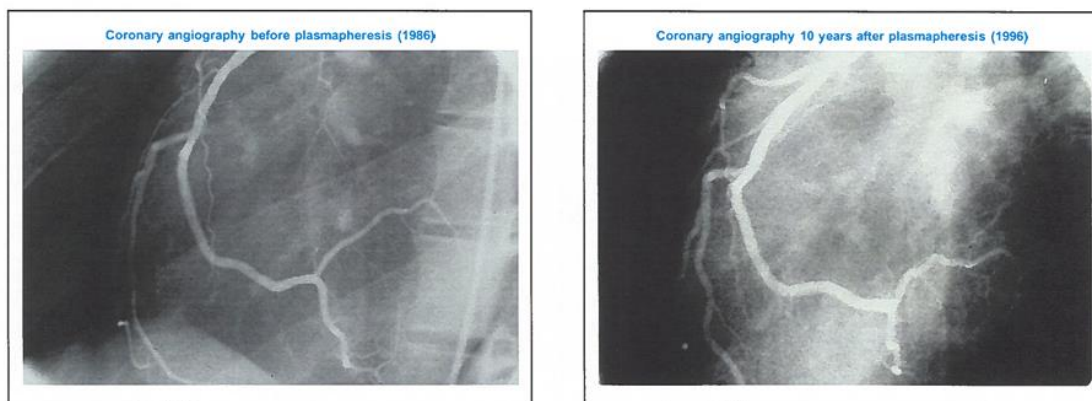
**Figure 3:** Total Cholesterol and LDL-C under treatment with Cholestyramine and repeated plasmapheresis

The plasmapheresis for 3 hours has been performed every week for 6 years, the volume adapted to the body weight.

At the age of 18 years a Doppler-Sonography of the A. Carotid int. has been performed, a marked stenosis has been found. Furthermore, marked

atherosclerotic lesions have been found in both Aa. iliacae and Aa. Fem. superficiales.

At the age of 20 years a repeated coronary angiography has been performed: the diagonal vessels seem clear without any atherosclerotic lesions; no progression has been found. (Figure. 4)



**Figure 4:** Coronary angiography before and 10 years after plasmapheresis

With 22 years: X-Ray of the achilles tendons: an enlargement until max. 2 cm has been found. Furthermore, some calcified spots.

With 23 years (1988): first LDL-Apheresis with immune absorption – columns which contained ApoB Antibodies has been started; Duration: 80 – 120 min every 4 weeks.

With 24 years: Ergometry: very good performance and capacity, normal regulation; ECG without any pathological findings.

Myocardial Scans, positive carrying capacity, with a decreased perfusion within the anteroseptal area.

With 24 years (1989): Sport with additional treatment with simvastatin (2 x 10mg).

LDL-Apheresis has been continued until 200 (for 13 years) every 4 weeks.

Lipids before and after the lipid-Apheresis.

Parameter	Level before lipid-apheresis	Level after lipid-apheresis
Cholesterol	485 mg/dl	293 mg/dl
LDL-c	449 mg/dl	207 mg/dl
HDL-c	28 mg/dl	21 mg/dl

**Table 3:** The median pre- and post-Treatment levels

In 2001: during a tennis competition he fell down and died.

In between the patient was able to carry a normal life, was very active, however he has to come to Vienna every 4 weeks for LDL-apheresis.

## Discussion

This is a historical report of one of the first patients with homozygous FH beginning from the diagnosis at the age of 10 years and the subsequent clinical observation until his death at the age of 36 years. It is interesting that the diagnosis of hoFH has been confirmed even several years after a typical family history, after typical laboratory tests and clinical signs. The syncopes which have been described by the mother can be interpreted as cardiac diffusion problem due to preexisting stenosis of the coronary arteries. The typical non-response to strict dietary measurements and the lacking effect of a cholesterol absorption inhibitor were also signs of severe form of FH. In the year of 1982 there was no other possibility for an effective treatment as the plasmapheresis. This procedure has been done for 6 years. It is notable that obviously the progression of atherosclerotic lesions could be stopped, perhaps a regression can be observed in the repeated coronary angiography. After changing to LDL-apheresis immune absorption, which has been performed every 4 weeks, the patient could stay at a normal life, was able to do his favourite sport tennis and fulfilled his duties in his profession. He died at the age of 36 years by a sudden death. There are no reports of a lifetime treatment of hoFH patients, just a few reports on cases which have been diagnosed. [14] The average life expectancy for those patients has been described by Ajufo et al at approx. 33 years. [15] Today the life expectancy seems to be longer due to causal treatments with innovative drugs (e.g. PCSK-9-inhibitors etc.). [16]

However the management of a great series (n = 201) of hoFH patients in Japan seems to be adequate. [17]

However, so far there are no reports available in the literature.

It has been shown by Thompson et al that the survival rate is dependent from the extent of cholesterol lowering by treatment. [18]

## Conclusion

This historical report shows impressive a life long history of a young patient who has been diagnosed with homozygous familial hypercholesterolemia in the eighties of the last century. It can be clearly shown, that the treatment with plasmapheresis and subsequently with lipoprotein apheresis could improve the cardiac circulation. The young man was able to have a normal life until his 36<sup>th</sup> birthday.

## Conflict of Interest

The authors declare that there is no conflict of interest and there was no financial or personal support of any organisation or other people.

## References:

1. Singh S, Bittner V. (2015). Familial Hypercholesterolemia--epidemiology, diagnosis, and screening. *Curr Atheroscler Rep* 17(2): 482.
2. Libby P, Buring JE, Badimon L, Hansson GK, Deanfield J, et al. (2019). Atherosclerosis. *Nat Rev Dis Primers* 5(1): 56.
3. Beheshti SO, Madsen CM, Varbo A, Nordestgaard BG. (2020). Worldwide prevalence of familial hypercholesterolemia.

- Journal of the American College of Cardiology*, 75(20): 2553-2566.
4. Akioyamen LE, Genest J, Shan SD, Reel RL, Albaum JM, et al. (2017). Estimating the prevalence of heterozygous familial hypercholesterolaemia: A systematic review and meta-analysis. *BMJ Open*, 7(9): e016461.
  5. Nordestgaard BG, Chapman MJ, Humphries SE, Ginsberg HN, Masana L, et al. (2013). Familial hypercholesterolaemia is underdiagnosed and undertreated in the general population: Guidance for clinicians to prevent coronary heart disease: Consensus statement of the European atherosclerosis society. *European Heart Journal*, 34(45): 3478-3490.
  6. Berberich AJ, Hegele RA. (2019). The complex molecular genetics of familial hypercholesterolaemia. *Nat Rev Cardiol*, 16(1): 9-20.
  7. Santos RD, Gidding SS, Hegele RA, Cuchel MA, Barter PJ, et al. (2016). Defining severe familial hypercholesterolaemia and the implications for clinical management: A consensus statement from the international atherosclerosis society severe familial hypercholesterolemia panel. *The Lancet Diabetes & Endocrinology*, 4(10): 850-861.
  8. Wiegman A, Gidding SS, Watts GF, Chapman MJ, Ginsberg HN, et al. (2015). Familial hypercholesterolaemia in children and adolescents: Gaining decades of life by optimizing detection and treatment. *Eur Heart J*, 36(36): 2425-2437.
  9. Widhalm K, Binder CB, Kreissl A, Aldover-Macasaet E, Fritsch M, et al. (2011). Sudden death in a 4-year-old boy: A near-complete occlusion of the coronary artery caused by an aggressive low-density lipoprotein receptor mutation (w556r) in homozygous familial hypercholesterolemia. *The Journal of Pediatrics*, 158(1): 167.
  10. Cuchel M, Bruckert E, Ginsberg HN, Raal FJ, Santos RD, et al. (2014). Homozygous familial hypercholesterolaemia: New insights and guidance for clinicians to improve detection and clinical management. A position paper from the consensus panel on familial hypercholesterolaemia of the European atherosclerosis society. *European Heart Journal*, 35(32): 2146-2157.
  11. Widhalm K, Benke IM, Fritz M, Geiger H, Helk O, et al. (2017). Homozygous familial hypercholesterolemia: Summarized case reports. *Atherosclerosis*, 257: 86-89.
  12. Raal FJ, Hovingh GK, Catapano AL. (2018). Familial hypercholesterolemia treatments: Guidelines and new therapies. *Atherosclerosis*. 277: 483-492.
  13. Widhalm K, Kleinberger G, Strobl W, Pachinger O, Kalman J. (1984). Diagnostik und effiziente Therapie mittels Plasmapherese bei einem Patienten mit homozygoter familiärer Hypercholesterinämie. *Helv. Paediat. Acta*; 39: 153-160.
  14. Dumić M, Uroic A, Francetić I, Puretić Z, Matisić D. et al. (2007). 3 years old boy – a homozygous familial hypercholesterolemia. *Lijes Vjesn*; 129(5): 130-133.
  15. Ajufo E, Cuchel M. (2016). Recent Developments in Gene Therapy for Homozygous Familial Hypercholesterolemia. *Curr Atheroscler Rep.*; 18 (5): 22.
  16. Bélanger AM, Akioyamen L, Allothman L, Genest J. (2020). Evidence for improved survival with treatment of homozygous familial hypercholesterolemia. *Curr Opin Lipidol.*; 31(4): 176-181.
  17. Takeji Y, Tada H, Ogura M, Nohara A, Kawashiri MA. et al. (2023). Clinical Characteristics of Homozygous Familial Hypercholesterolemia in Japan. *Jacc. Asia*; 3 (6): 881-891.
  18. Thompson GR, Blom DJ, Marais AD, Seed M, Pilcher GJ, Raal FJ. (2018) Survival in homozygous familial hypercholesterolemia is determined by the on-treatment level of serum cholesterol. *European Heart Journal*. 39(14): 1162-1168.



This work is licensed under Creative Commons Attribution 4.0 License

To Submit Your Article Click Here:

[Submit Manuscript](#)

DOI:10.31579/2690-4861/865

#### Ready to submit your research? Choose Auctores and benefit from:

- fast, convenient online submission
- rigorous peer review by experienced research in your field
- rapid publication on acceptance
- authors retain copyrights
- unique DOI for all articles
- immediate, unrestricted online access

At Auctores, research is always in progress.

Learn more <https://auctoresonline.org/journals/international-journal-of-clinical-case-reports-and-reviews>