

Comparative Characteristics of Methods for Treating Partial Anomalous Pulmonary Venous Drainage (PAPD)

Mirolyubov L.M*

Professor, head of the department of pediatric surgery.

***Corresponding Author:** Mirolyubov L.M., Professor, head of the department of pediatric surgery.

Received Date: 18 April, 2025 | **Accepted Date:** 28 April, 2025 | **Published Date:** 20 May, 2025

Citation: Mirolyubov L.M., (2025), Comparative Characteristics of Methods for Treating Partial Anomalous Pulmonary Venous Drainage (PAPD), *Journal of Clinical Surgery and Research*, 6(4); DOI:10.31579/2768-2757/167

Copyright: © 2025, Mirolyubov L.M. This is an open access article distributed under the Creative Commons Attribution License, which permits unrestricted use, distribution, and reproduction in any medium, provided the original work is properly cited.

Abstract:

The final situation regarding the treatment of CHADLV with or without ASD remains alarming in terms of the prognosis of postoperative cardiac arrhythmias and remote stenotic complications at the mouth of the SVC. We have developed and tested in the clinic our own original method of correction of CHADLV taking into account the prevention of stenotic complications in the remote period, as well as postoperative cardiac arrhythmias.

keywords: pediatric cardiac surgery; cardiac surgery; cardiovascular surgery

Introduction

It is known that partial Anomalous pulmonary venous drainage (APVD) is one of the most common pathologies of pulmonary venous return [1, 2, 3]. The defect was first described by Winslow (1739). During a pathological examination, he discovered abnormal drainage of the pulmonary vein of the upper lobe of the right lung into the superior vena cava. The anatomy and clinical features of this defect were most fully studied by Brody (1942). R. Darling et al . (1957) systematized the anatomical variants (types) of the defect . In most cases (97.2%), drainage of the right pulmonary veins is observed, and in the rest - the left [4]. The incidence of this defect is at least 1.5% among all congenital heart defects (CHD) [1, 5]. The average life expectancy of patients with CHD without surgical correction does not exceed 37-40 years [1,2]. The first successful operation to correct CADPV using the closed method of "atrioseptopexy" was performed by W. Neptune in 1953. The modern stage of treatment of the defect began with the introduction of open heart surgery into clinical

practice. In 1955, under hypothermia conditions, F. Lewis was the first to perform an operation to correct abnormal drainage of the pulmonary veins into the right atrium and superior vena cava. Later, artificial blood circulation began to be used to perform the operation. Partial correction is particularly difficult abnormal drainage of the right upper pulmonary veins into the superior vena cava (AUPV to SVC) with or without an atrial septal defect (ASD). The most common surgical treatment for ASD involves the application of an intra-atrial patch made of autopericardium, which directs blood flow from the pulmonary veins through the ASD into the left atrium (LA). The applied patch, which forms a tunnel, narrows the lumen of the superior vena cava in the area of its mouth by half or more, therefore, in order to preserve the true volume-diameter and prevent venous hypertension in the SVC system, it is necessary to apply a second patch outside the atrium (usually it is made of xenopericardium, since the autopericardium has already been used).

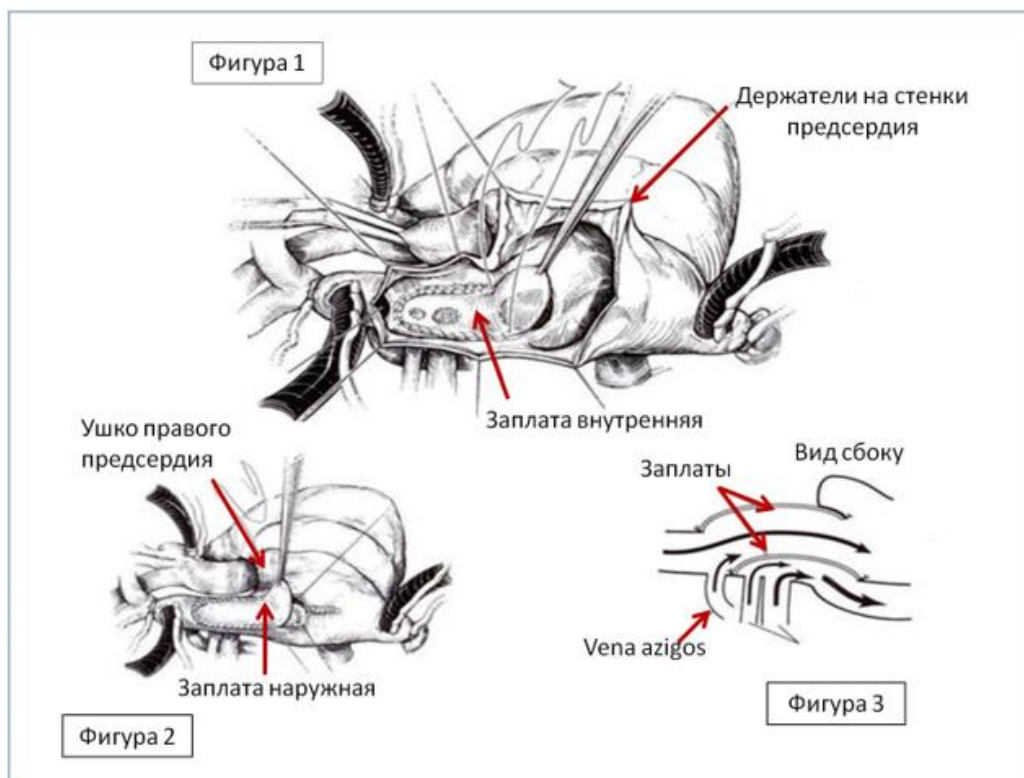


Figure 1: An internal patch is applied, which transfers the pulmonary veins into the left atrium.

Figure 2: External patch of xenopericardium to prevent narrowing in the area of the first patch. Classic version.

Figure 3: Blood flows after plastic surgery. Side view.

The above-described two-patch method of surgical treatment of CHADLV is the "gold standard" in the treatment of this pathology. In the cardiac surgery department of the Republican Children's Clinical Hospital of the Ministry of Health of the Republic of Tatarstan, we have used it for quite a long time. At late stages after the operation, from 1 to 3-5 years, patients operated by us repeatedly returned with phenomena of venous hypertension in the system of the superior vena cava. The cause of complications at late stages of observation in all cases was the fibrous-cicatricial process with phenomena of calcification of the xenopericardial patch, which led to narrowing of the mouth of the superior vena cava. The method proposed by Verdun et al., which also provides, as in the classical version, the application of a patch on the ASD with the simultaneous transfer of anomalous veins to the left atrium, and then, in order to prevent narrowing in the area of the mouth of the superior vena cava, the implementation of a direct anastomosis of the right atrial appendage with the cut off superior vena cava. It turned out that Verdun's method does not guarantee against stenotic complications in the area of the suture strip and complications from the conduction system of the heart (the sinus node, the master of the cardiac rhythm, is located in the mouth of the superior vena cava). In 2019, Krivoshechekov E.V. and co-authors modified the

Verdun method by cutting out a shaped flap from the atrial wall, also trying to reduce the number of complications in the long-term observation period. The final situation regarding the treatment of CHADLV with or without ASD remains alarming in terms of the prognosis of postoperative cardiac arrhythmias and remote stenotic complications at the mouth of the SVC. We have developed and tested in the clinic our own original method of correction of CHADLV taking into account the prevention of stenotic complications in the remote period, as well as postoperative cardiac arrhythmias. The method involves access to the right atrium to the pulmonary veins and ASD by an incision along the upper edge of the superior vena cava with a transition to the lower ridge-rib of the right atrial appendage. The access provides good visualization of the necessary structures, and from it we perform the application of an internal patch with the transfer of the abnormal drainage. Instead of the second patch, we use a dissected auricle, the apex of which easily reaches the upper edge of the dissected superior vena cava. Suture strips along the edges of the auricle and the dissected vein allow us to cover the orifice of the SVC narrowed by the first patch like a hood. Priority reference.... The results were followed for 7 years. 19 patients were operated on, postoperative rhythm disturbances and stenotic disorders were not observed in any case.

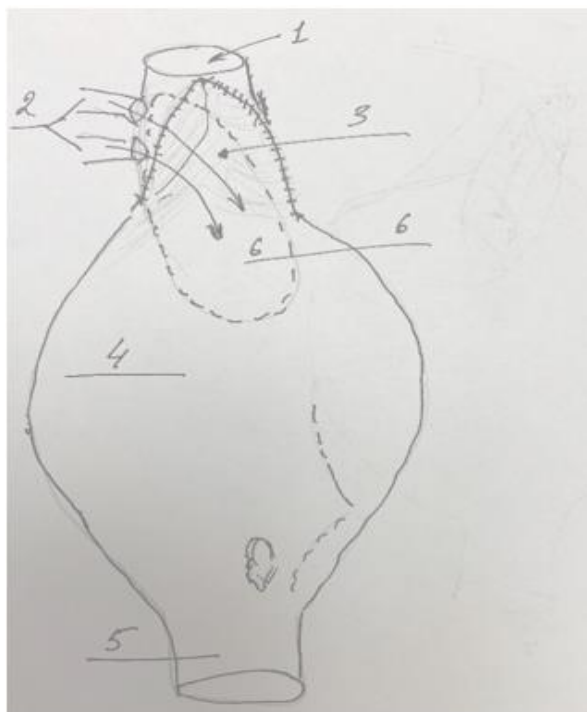


Figure 4: After applying a patch with the transfer of abnormal veins to the left atrium, plastic surgery of the vein mouth was performed with tissue from the atrial appendage: "Covering with a hood".

1-superior vena cava; 2-anomalous veins; 3-upper part of the auricle with the borders of the suture strip; 4-atrium; 5-inferior vena cava; 6-projection of the internal patch.

Priority for invention from January 2025.

Conclusions:

1. The proposed method of correcting CHADLV shows good results in preventing both cardiac arrhythmia and remote stenotic complications in the area of the main surgical intervention.
2. Reduced risk of mechanical damage to the sinus node and conduction pathways compared to complete excision of the superior vena cava.

Reference

1. John W. Kirklin , Brian G. Barrat-Boyes . CARDIAC SURGERY. 1986 , s. 464.
2. Constantine Mavrodis, Karl L. Backer. PEDIATRIC CARDIAC SURGERY. 3rd Edition . 2003. S. 283-296.
3. Burakovsky V.I., Bokeria L.A. Cardiovascular surgery. Manual. 1989. P. 213-214.
4. Jacobs JP, Burke RP, Quintessenza JA, Mavrodis C. Atrial septal defect, Ann. Thorac . Surg. 69 (suppl) ,: S18, 2000.
5. DeLeon SY, Freeman JE, Ilbawi MN, et all. Surgical techniques in partial anomalous pulmonary veins to the superior vena cava. Ann. Thorac. Surg. 55:1222, 1993.



This work is licensed under Creative Commons Attribution 4.0 License

To Submit Your Article, Click Here:

Submit Manuscript

DOI:[10.31579/2768-2757/167](https://doi.org/10.31579/2768-2757/167)

Ready to submit your research? Choose Auctores and benefit from:

- fast, convenient online submission
- rigorous peer review by experienced research in your field
- rapid publication on acceptance
- authors retain copyrights
- unique DOI for all articles
- immediate, unrestricted online access

At Auctores, research is always in progress.

Learn more <https://www.auctoresonline.org/journals/journal-of-clinical-surgery-and-research>