

Yasser's Electrocardiographic Palpitations Wave with Bilobed Apical Floating Heart Syndrome in Yasser's Fibrillation-a Strange Innovative Cardiovascular and Radiological Discoveries

Yasser Mohammed Hassanain Elsayed

Critical Care Unit, Kafr El-Bateekh Central Hospital, Egyptian Ministry of Health (MOH), Damietta, Egypt

***Corresponding Author:** Yasser Mohammed Hassanain Elsayed, Critical Care Unit, Kafr El-Bateekh Central Hospital, Egyptian Ministry of Health (MOH), Damietta, Egypt

Received date: January 20, 2025; **Accepted date:** February 21, 2025; **Published date:** April 01, 2025

Citation: Yasser Mohammed Hassanain Elsayed, (2025), Yasser's Electrocardiographic Palpitations Wave with Bilobed Apical Floating Heart Syndrome in Yasser's Fibrillation-a Strange Innovative Cardiovascular and Radiological Discoveries, *Journal of Thoracic Disease and Cardiothoracic Surgery*, 6(2); DOI:10.31579/2693-2156/125

Copyright: © 2025, Yasser Mohammed Hassanain Elsayed. This is an open access article distributed under the Creative Commons Attribution License, which permits unrestricted use, distribution, and reproduction in any medium, provided the original work is properly cited.

Abstract

Rationale: Atrial fibrillation (AF) is the most common arrhythmia. It is known leading cause of ischemic cerebrovascular accidents. Yasser's fibrillation (sinusoidal AF) or mixed AF is a new cardiovascular discovery. The partial sino-atrial nodal function has an essential role in the presence of sinusoidal AF (Yasser's fibrillation) or mixed AF and its interpretation. Sinusoidal AF (Yasser's fibrillation) or mixed AF may be balanced between AF and normal sinus rhythm.

Patient concerns: A 23-year-old, single male farmer Egyptian patient was presented to the physician outpatient clinic with Yasser's fibrillation (Sinusoidal AF) and chest pain. The patient was referred and admitted to the intensive care unit (ICU) for AF with chest pain.

Diagnosis Yasser's electrocardiographic wave with Bilobed Apical Floating Heart Syndrome in a young with Yasser's fibrillation (Sinusoidal atrial fibrillations) and a strange extremely rare associated rhythm.

Interventions: Chest X rays, electrocardiography, oxygenation, IV amiodarone, and echocardiography.

Outcomes: Dramatic response and excellent outcomes were the results.

Lessons: Bilobed Apex heart with Floating Heart syndrome is an innovative cardiovascular and radiological discovery. The Bilobed Apex heart with Floating Heart syndrome with "Yasser's Electrocardiographic Palpitations Waves" and off-phenomenon post-amiodarone IVB injection are remarkable innovative constellations. "Yasser's Electrocardiographic Palpitations Waves" was shortly described as a superficial upright wave associated with unusual palpitations. Bilobed Apex heart with Floating Heart has no known cause. It is mostly congenital. The senses of sudden heart stoppage, generalized fatigue, vertigo, acute confusion, generalized body relaxation, a sense of separation from the environment, and a sense of no abnormality within minutes of amiodarone IVB injection are an off-phenomenon.

Keywords: yasser's electrocardiographic wave; bilobed apex; floating heart syndrome; congenital heart diseases; yasser's fibrillation; u waves; sinusoidal atrial fibrillations; atrial fibrillation

Abbreviations

AF: Atrial fibrillation

CHF: Chronic heart failure

CVA: Cerebrovascular accidents

ECG: Electrocardiogram

ICU: Intensive care unit

ED: Emergency department

IHD: ischemic heart disease

O2: Oxygen

POC: Physician outpatient clinic

SAN: Sino-atrial nodal

TEE: Transesophageal echocardiogram

VR: Ventricular rate

Introduction:

Atrial fibrillation (AF) is the most common arrhythmia. AF is an abnormal arrhythmia characterized by rapid and irregular beating of the atrial chambers of the heart [2]. It is known leading cause of ischemic cerebrovascular accidents (CVA). The elderly, hypertension, underlying heart and lung disease, congenital heart disease, heavy alcohol consumption, stress, illicit drug use, atrial ischemia, advanced age, Inflammation, genetic factors, and, neurological, and endocrine disorders are trigger risk factors for AF [1]. Aging populations are parallel with improved outcomes in several chronic diseases that lead to AF diagnoses. Transient ischemic attack (TIA), ischemic CVA, chronic heart failure (CHF), systemic embolism, and sudden cardiac death (SCD) are associated catastrophic with AF [3]. AF may be paroxysmal (less than seven days) or persistent (more than seven days) [4]. Symptoms vary from asymptomatic to chest pain, palpitations, palpitations, dyspnea, nausea, dizziness, profuse sweating, and fatigue. The ECG is essential for the diagnosis of AF. An irregular irregularity pattern with no distinguishable p-waves is essential for the diagnosis of AF. Fibrillatory waves may be present may be absent [1]. Transesophageal echocardiogram (TEE) is a choice for evaluating for atrial thrombus secondary to AF. TEE should always be done before cardioversion in these patients to minimize the risk of stroke [5,6]. Screening for AF during routine examination is a cost-effective strategy compared with no screening. Screening with pulse monitoring is nearly the most cost-effective strategy [6]. The management of atrial fibrillation in the acute setting depends on hemodynamic stability and risk stratification [1]. Anticoagulants, anti-arrhythmic drugs, devices, and non-pharmacologic measures in the last 30 years have improved the cardiac functionality of AF [7]. Non-pharmacological therapy including ablation therapy and pacemaker implantation are considered. Pacing is used for severe cases resulting in CHF in AF [8-10]. **Yasser's fibrillation** (Sinusoidal AF) or mixed AF is a new cardiovascular discovery. The partial sino-atrial nodal (SAN) function has an essential role in the presence of Sinusoidal AF (Yasser's fibrillation) or mixed AF and its interpretation. Sinusoidal AF (Yasser's fibrillation) or mixed AF may be balanced between AF and normal sinus rhythm (NSR). The percentages of normal sinus beats to AF beats in the cases of Sinusoidal AF (Yasser's fibrillation) may be a guide for the approximate healthy or sick part of the SAN [11,12].

Case presentation:

A 23-year-old single young male farmer Egyptian heavy smoker patient was presented to the physician outpatient clinic (POC) with presyncope, tachypnea, angina, and palpitations. The chest pain was non-specific. He gave a history of daily 10 cigarettes for about 5 years. There was no history of the same attack. The patient denied a history of other relevant rheumatic or congenital heart diseases, drugs, or other special habits. Oral consent was taken. Upon general physical examination; generally, the patient has anxiety, irritability, tachypnea, and distress with an irregular tachycardia pulse rate of VR; 140 bpm, blood pressure (BP) of 100/70 mmHg, respiratory rate of 20 bpm, a temperature of 36°C, and pulse oximeter of oxygen (O₂) saturation of 95%. Irregular tachycardia was heard on chest auscultations. Currently, the patient was referred and admitted to the ICU for atrial fibrillation with chest pain. Initially, the patient was treated with O₂ inhalation by O₂ system line (100%, by simple mask, 5L/min). One amiodarone IVB amp (150 mg) diluted in 100 ml Dextrose 5% (concentration 1.5 mg/ml) was given over 10 minutes. Within 3 minutes of

the above amiodarone IVB injection, the patient senses a sudden heart stoppage, generalized fatigue, vertigo, acute confusion, generalized body relaxation, a sense of separation from the environment, and a sense of no abnormality. Maintained amiodarone IVI amps (360 mg) diluted in 500 ml Dextrose 5% (with concentration 1.8 mg/ml) over next 6 hours, then amiodarone IVI amps (540 mg) diluted in 500 ml Dextrose 5% (infusion rate 0.5 mg/minutes) over next 18 hours were given. The patient was hourly monitored for temperature, pulse, blood pressure, ECG, and O₂ saturation. The initial ECG tracing was done on the initial presentation in the POC showing Yasser's fibrillation (sinusoidal atrial fibrillations) (of VR: 137) with to one-to-one triple rhythm of sinus beat, junctional beat, and pre-exciting beat. There are coved T-waves with wide coved p-wave, squared ST-segment elevation with wide coved p-wave, and squared ST-segment elevation with pre-exciting p-wave with some irregularities (**Figure 1A**). The second ECG tracing was taken within 2 minutes of the above ECG showing Yasser's fibrillation (sinusoidal AF) (of VR: 131) with alternation of variable triple rhythm of sinus beat, junctional beat, and Ta wave. There are also coved T-waves with wide coved p-wave, squared ST-segment elevation with wide coved p-wave, and squared ST-segment elevation with large irregularities (**Figures 1B and 2A**). The patient is still complaining of palpitations. So, the third ECG tracing was taken within 30 hours of the above ECG tracing and after the above management showing normal sinus rhythm (NSR of VR: 67) with abnormal superficial upright waves among T waves and P waves which upright in all leads except aVR is superficially inverted. It is flat in aVL and V1 (**Figures 1C and 2B**). The patient is still complaining of palpitations. So, the fourth ECG tracing was taken within 4 days of the first ECG tracing and after the above management showing NSR (of VR: 60) with superficial upright waves among T waves and P waves which upright in all leads except aVR and V1 is abnormal superficially inverted. It is flat in aVL (**Figure 1D**). The fifth ECG tracing was taken within 7 days of the first ECG and after the above management showing NSR (of VR: 79) with abnormal superficial inverted waves among T waves and P waves in V1-3 (**Figure 1E**). The plain chest-XR film was done on the second day of the presentation showing the bilobed apex and air space between the lower surface of the heart and diaphragm (**Figure 3A**). Echocardiography was done on the second day of presentation showing no abnormalities with normal ejection fraction (EF) (71.23 %) (**Figure 3B**). The initial complete blood count (CBC) after discharge; Hb was 13.6 g/dl (during hospitalization; 15.7 *10³/mm³), RBCs; 4.79*10³/mm³ (during hospitalization; 5.66*10³/mm³), WBCs; 3.2*10³/mm³ (during hospitalization; 4.7*10³/mm³); (Neutrophils; 44 %, Lymphocytes: 45%, Monocytes; 9%, Eosinophils; 2% and Basophils 0%), and Platelets; 178*10³/mm³ (during hospitalization; 233*10³/mm³). SGPT was (22.4 U/L) and SGOT was (20.8U/L). TSH was (1.39uU/ml). RBS was (105 mg/dl). Serum creatinine (0.92mg/dl) and blood urea was (31.5 mg/dl). Plasma sodium was (139.6mmol/L). Serum potassium was (4.17mmol/L). Total calcium was (8.9mg/dl). The troponin I test was negative. Yasser's electrocardiographic wave with Bilobed Apical Floating Heart Syndrome in a young with Yasser's fibrillation (Sinusoidal atrial fibrillations) and strange extremely rare associated rhythms **was the most probable diagnosis**. Within a few minutes of starting the above amiodarone IVB, the patient showed dramatic clinical and electrocardiographic improvement. The patient was discharged within 24 days after clinical stabilizations and electrocardiographic improvement and continued on amiodarone tablets (200mg, BID, with gradual tapering) and diltiazem tablets (60 mg, OD). Further recommended cardiac follow-up was advised.

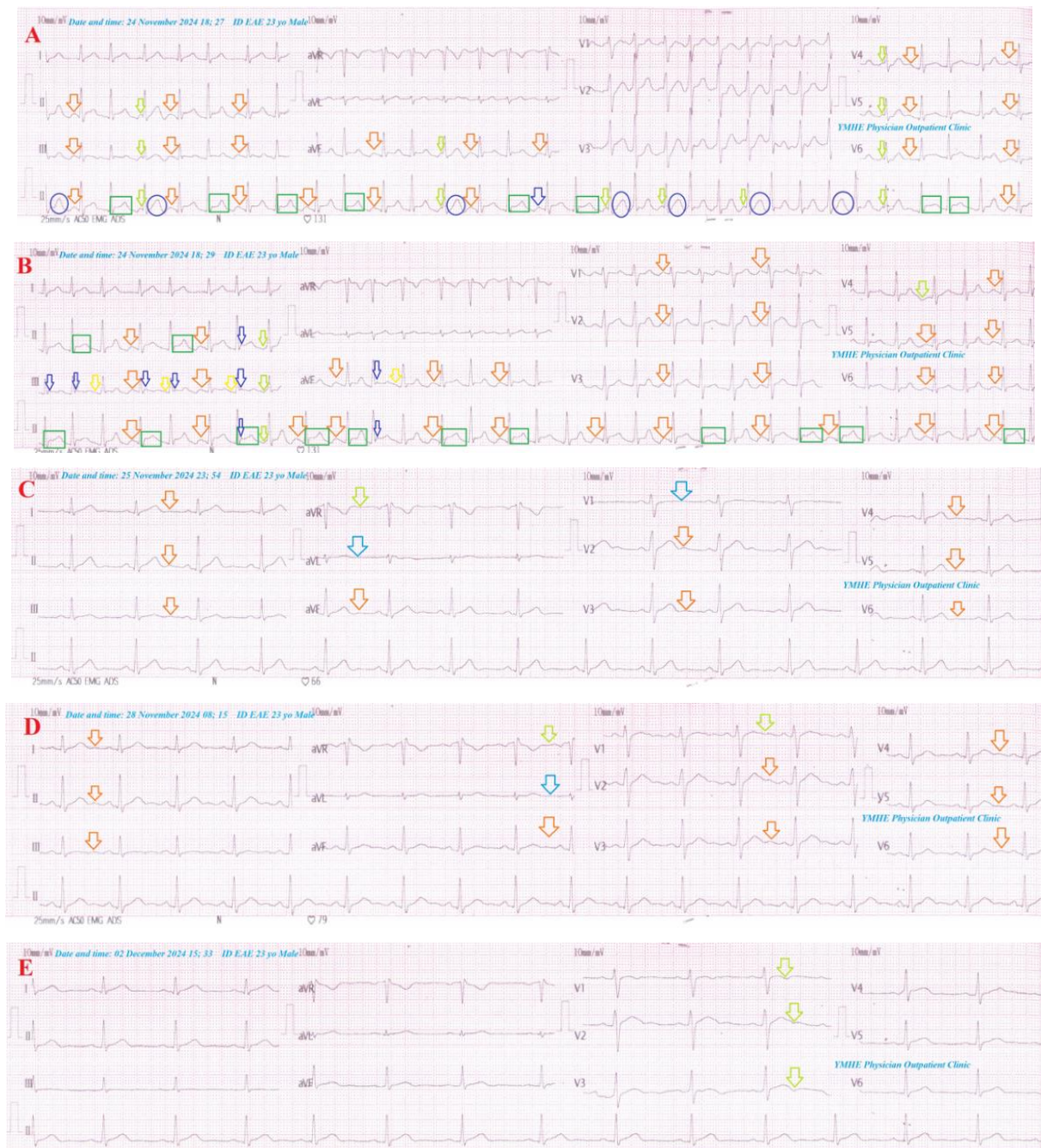


Figure 1: Serial ECG tracings; A. tracing was taken on the initial presentation in the POC showing Yasser's fibrillation (sinusoidal atrial fibrillations) (of VR: 137) with one to one-to-one triple rhythm of sinus beat (orange arrows), junctional beat (green squares), and pre-exciting beat (lime arrows). There are coved T-wave (dark blue circles) with wide coved p-wave (orange arrows), squared ST-segment elevation with wide coved p-wave (orange arrows), and squared ST-segment elevation (green squares) with pre-exciting p-wave (lime arrows) with some irregularities. **B. tracing** was taken within 2 minutes of the above ECG showing Yasser's fibrillation (sinusoidal AF of VR: 131) with alternation of variable triple rhythm of sinus beat, junctional beat (dark blue and lime arrows), and Ta wave (yellow arrows). There are also coved T-wave with wide coved p-wave (orange arrows), squared ST-segment elevation (green squares) with wide coved p-wave (orange arrows), and squared ST-segment (green squares) elevation with large irregularities. **C. tracing** was taken within 30 hours of the above ECG tracing and after the above management showing normal sinus rhythm (NSR of VR: 67) with abnormal superficial upright waves among T waves and P waves which upright in all leads (orange arrows) except aVR is superficially inverted (lime arrow). It is flat in aVL and V1 (light blue arrows). **D. tracing** was taken within 4 days of the first ECG tracing and after the above management showing NSR (of VR: 60) with superficial upright waves among T waves and P waves which upright in all leads (orange arrows) except aVR and V1 (lime arrows) is abnormal superficially inverted. It is flat in aVL (light blue arrows). **E. tracing** was taken within 7 days of the first ECG and after the above management showing NSR (of VR: 79) with abnormal superficial inverted waves among T waves and P waves in V1-3 (lime arrow).

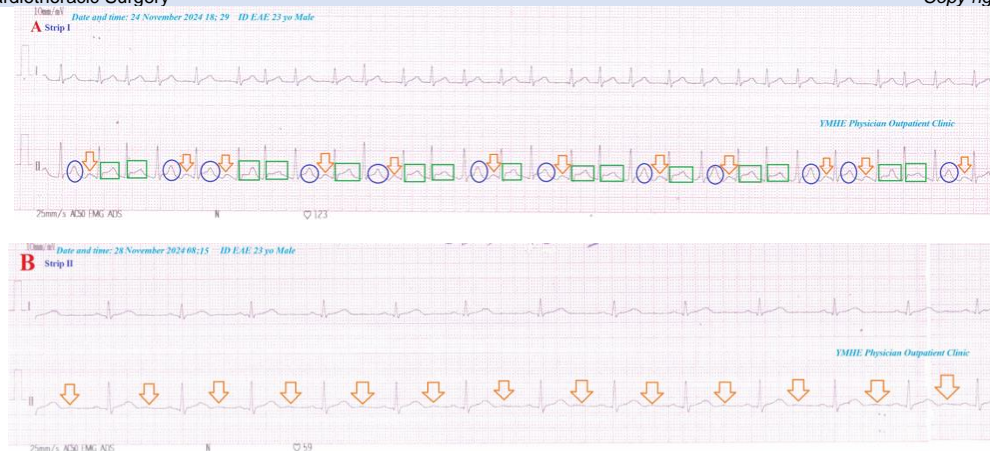


Figure 2: Serial ECG strips; A. strip tracing was taken on the initial presentation in the POC showing Yasser's fibrillation (sinusoidal AF) with the same changes in the above A and B tracing. **B. strip tracing** was taken within 4 days of the first ECG tracing and after the above management showing NSR (of VR: 60) with abnormal superficial upright waves among T waves and P waves.

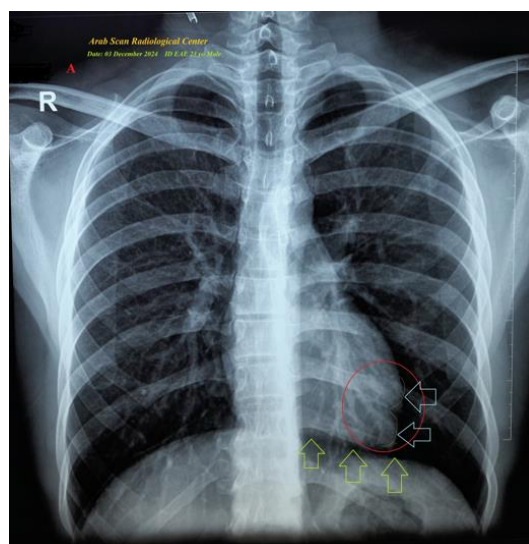


Figure 3A; Chest x-ray was done on the second day of presentation showing bilobed apex (red circle, light blue arrows, and golden circumferential arrows) and air space between the lower surface of the heart and diaphragm (lime arrows).

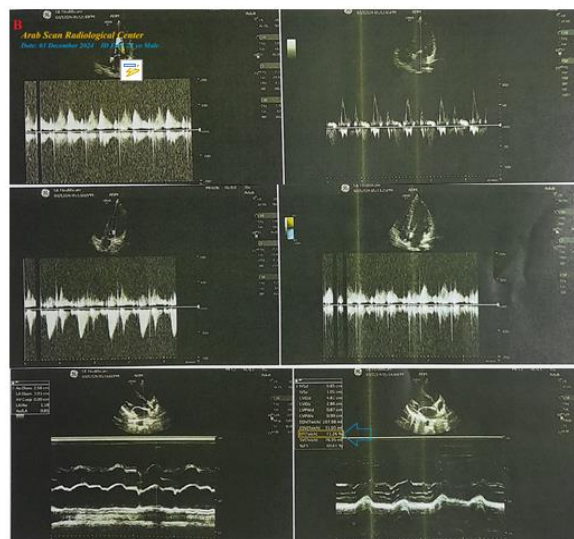


Figure 3B; was done on the second presentation day and showed no abnormalities with normal EF (71.23 %, yellow rectangle and light blue arrow).

Discussion

• Overview:

• A young, single male farmer Egyptian patient was presented to the physician outpatient clinic with Yasser's fibrillation (Sinusoidal AF) and chest pain. The patient was referred and admitted to the intensive care unit (ICU) for AF with chest pain.

• **The primary objective** for my case study was the presence of a young, single male farmer Egyptian patient who presented with Yasser's fibrillation (Sinusoidal AF) in the ICU.

• **The secondary objective** for my case study was how you would manage this case in the ICU.

• An irregular irregularity pattern with no distinguishable p-waves was indicated for the diagnosis of AF (**Figures 1A, 1B, and 2A**).

• Interestingly, the presence of sinus beats with AF beats will strengthen the higher suspicion for the diagnosis of Yasser's fibrillation (Sinusoidal AF) (**Figures 1A, 1B, and 2A**). There are sporadic P waves in the presence of underlying AF supporting the diagnosis of Yasser's fibrillation (Sinusoidal atrial fibrillations) or mixed AF [11,12].

• The dramatic response of Yasser's fibrillation (Sinusoidal AF) to IVB amiodarone happened.

• The presence of these abnormal superficial upright waves among T waves and P waves in all leads but superficially inverted in aVR and flat in aVL and V1 (**Figures 1C and 2B**) or upright in all leads but superficially inverted in aVR and V1 and flat in aVL (**Figure 1D**) is a significant.

• These superficial upright waves were associated with unusual palpitations even, when the patient was calm, connected to the ECG apparatus, and even after stoppage of both oral amiodarone and diltiazem. These new abnormal waves which are associated with unknown palpitations exclusively named "Yasser's Electrocardiographic Palpitations Waves".

• U waves were the most probable and important differential diagnosis for "Yasser's Electrocardiographic Palpitations Wave: the current ECG case study. The persistence of these abnormal waves among T and P waves, absence of organic cardiac diseases, normal thyroid functions, normal

electrolytes, and extension of these waves in all ECG leads, will strongly exclude the diagnosis of U waves [13]. U waves often register in all leads except V6, most frequently in V2 and V3. In tachycardia or hypocalcemia, the U wave is superimposed on the T wave. In tachycardia, the U wave fuses with the R wave of the next cardiac cycle. Prominent U waves (more than 1-2 mm or 25% of the height of the T wave.) are most commonly seen in hypokalemia. It may be caused by hypercalcemia, thyrotoxicosis, digitalis, epinephrine, and Class 1A and 3 antiarrhythmic, congenital long QT syndrome, and intracranial hemorrhage. An inverted U wave may represent cardiac ischemia (especially with left anterior descending coronary artery disease or left ventricular volume overload [14-18]. An inverted U wave may be a specific ECG sign of myocardial ischemia [19].

• The origin of these abnormal waves is unknown. Its presence with complaining of palpitations may be as delayed repolarization of Purkinje fibers, prolonged repolarization of mid-myocardial "M-cells", repolarization of the papillary muscle, and after-potentials resulting from mechanical forces in the ventricular wall are suggested theories [13].

• The irregular alternation among the sinus beats, junctional beats, preexciting beats, and fibrillatory waves or Ta waves happened (**Figures 1A, 1B, and 2A**).

• Bilobed apical heart in the chest-X-ray film with a large space between the diaphragm and inferior surface of the heart (**Figure 3A**) may support the new diagnosis of Bilobed Apex, Floating Heart Syndrome. There is no known interpretation for this bilobed apex. It may be congenital (**Figure 4**)

• The patient's description of senses a sudden heart stoppage, generalized fatigue, vertigo, acute confusion, generalized body relaxation, a sense of separation from the environment, and a sense of no abnormality within 3 minutes of amiodarone IVB injection was noted.

• This may be an off-phenomenon with a new and important description post-acute reliving of arrhythmia. There are no known pathophysiological mechanisms. Recirculation after sudden reliving of associated arrhythmia may be suggestive interpretation theory.

• I can't **compare** the current case with similar conditions. There are no identical or known cases with the same management for near comparison.

• The only limitation of the current study was the unavailability of electrophysiological study and coronary angiography.

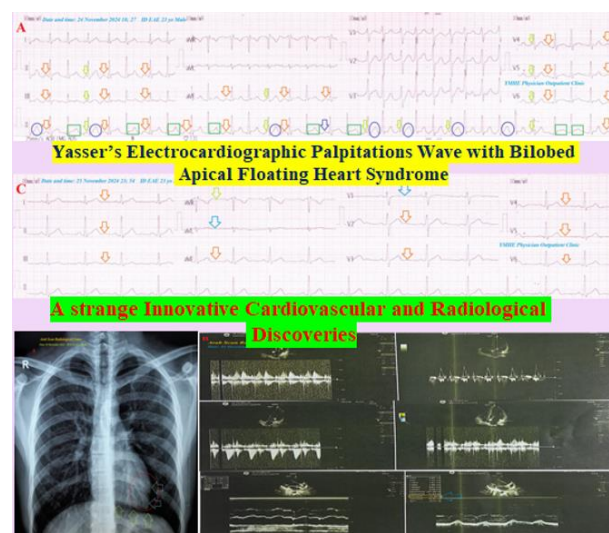


Figure 4- The author caricatures a display of a Bilobed Apex heart with Floating Heart syndrome with "Yasser's Electrocardiographic Palpitations Waves".

Conclusion and Recommendations

- Bilobed Apex heart with Floating Heart syndrome is an innovative cardiovascular and radiological discovery.
- The Bilobed Apex heart with Floating Heart syndrome with "Yasser's Electrocardiographic Palpitations Waves" and off-phenomenon post-amiodarone IVB injection are remarkable innovative constellations.
- "Yasser's Electrocardiographic Palpitations Waves" was shortly described as a superficial upright wave associated with unusual palpitations.
- Bilobed Apex heart with Floating Heart has no known cause. It is mostly congenital.
- The senses of sudden heart stoppage, generalized fatigue, vertigo, acute confusion, generalized body relaxation, a sense of separation from the environment, and a sense of no abnormality within 3 minutes of amiodarone IVB injection are an off-phenomenon.

Conflicts of interest

- There are no conflicts of interest.

Acknowledgment

- I want to thank my wife for saving time and improving the conditions for supporting me.

References

1. Nesheiwat Z, Goyal A, Jagtap M. (2024). Atrial Fibrillation.
2. Sanders GD, Lowenstern A, Borre E, Chatterjee R, Goode A, Sharan L, et al. (2018). Stroke Prevention in Patients with Atrial Fibrillation: A Systematic Review Update [Internet]. Rockville (MD): Agency for Healthcare Research and Quality (US)
3. Amin A, Houmsse A, Ishola A, Tyler J, Houmsse M. (2016). The current approach of atrial fibrillation management. *Avicenna J Med.* 6(1):8-16.
4. Markides V, Schilling RJ. Atrial fibrillation: classification, pathophysiology, mechanisms and drug treatment. *Heart.* 2003 Aug;89(8):939-43.
5. Robert R, Porot G, Vernay C, Buffet P, Fichot M, Guenancia C, et al. Incidence, Predictive Factors, and Prognostic Impact of Silent Atrial Fibrillation After Transcatheter Aortic Valve Implantation. *Am J Cardiol.* 2018 Aug 1;122(3):446-454.
6. Tarride JE, Quinn FR, Blackhouse G, Sandhu RK, Burke N, Gladstone DJ, et al. (2018). Is Screening for Atrial Fibrillation in Canadian Family Practices Cost-Effective in Patients 65 Years and Older? *Can J Cardiol.*; 34(11):1522-1525.
7. Munger TM, Wu LQ, Shen WK. (2014). Atrial fibrillation. *J Biomed Res.*; 28(1):1-17.
8. Karnad A, Pannelay A, Boshnakova A, Lovell AD, Cook RG. (2018). Stroke prevention in Europe: how are 11 European countries progressing toward the European Society of Cardiology (ESC) recommendations? *Risk Manag Healthc Policy.*; 11:117-125.
9. Laäs DJ, Naidoo M. (2018). Oral anticoagulants and atrial fibrillation: A South African perspective. *S Afr Med J.*;108(8):640-646.
10. Bai CJ, Madan N, Alshahrani S, Aggarwal NT, Volgman AS. (2018). Sex Differences in Atrial Fibrillation-Update on Risk Assessment, Treatment, and Long-Term Risk. *Curr Treat Options Cardiovasc Med.*;20(10):79.
11. Hassanain Elsayed YM. (2024). Sinusoidal Atrial Fibrillation (Yasser's Fibrillation) and Partial SAN Function in COVID-19 Pneumonia; a New Cardiovascular Discovery Change in Atrial Fibrillation Directory, *International Journal of Cardiovascular Medicine.*;3(5):1-8.
12. Elsayed YMH. Sympathetic Crashing Acute Pulmonary Edema in Elderly with Yasser's Fibrillation, Multiple Valvular Disease, and Possible Multivessel Disease in COVID Pneumonia; Prognostication and Management. *Journal of Medicine Care and Health Review* 1(5):1-6.
13. Burns Ed. U Wave.
14. Gerson MC, Phillips JF, Morris SN, McHenry PL. (1979). Exercise-induced U-wave inversion as a marker of stenosis of the left anterior descending coronary artery. *Circulation.*;60(5):1014-1020.
15. Conrath CE, Opthof T. (2005). The patient U wave. *Cardiovasc Res.*;67(2):184-186.
16. Franckowiak SC, Dobrosielski DA, Reilley SM, Walston JD, Andersen RE. (2011). Maximal heart rate prediction in adults that are overweight or obese. *J Strength Cond Res.*;25(5):1407-1412.
17. Pérez Riera AR, Ferreira C, Filho CF, Ferreira M, Meneghini A, Uchida AH, et al. (2008). The enigmatic sixth wave of the electrocardiogram: the U wave. *Cardiol J.*;15(5):408-421.
18. Gerson MC, McHenry PL. (1980). Resting U wave inversion as a marker of stenosis of the left anterior descending coronary artery. *Am J Med.* ;69(4):545-550.
19. Sovari AA, Farokhi F, Kocheril AG. (2007). Inverted U wave, a specific electrocardiographic sign of cardiac ischemia. *Am J Emerg Med.* ;25(2):235-237.



This work is licensed under Creative Commons Attribution 4.0 License

To Submit Your Article Click Here: **Submit Manuscript**

DOI: [10.31579/2693-2156/125](https://doi.org/10.31579/2693-2156/125)

Ready to submit your research? Choose Auctores and benefit from:

- ❖ fast, convenient online submission
- ❖ rigorous peer review by experienced research in your field
- ❖ rapid publication on acceptance
- ❖ authors retain copyrights
- ❖ unique DOI for all articles
- ❖ immediate, unrestricted online access

At Auctores, research is always in progress.

Learn more <http://www.auctoresonline.org/journals/journal-of-thoracic-disease-and-cardiothoracic-surgery>