

Intraoperative Innominate Vein Perforation Due to Malpositioned Central Venous Catheters: A Dual Hazard with Fatal Outcome

Mohamed Eraqi ^{1*}, Ketak Nagare ¹, Tamer Ghazy ²

¹Department of Cardiac Surgery, Klinikum Bayreuth GmbH, Bayreuth, Germany.

²Department of Cardiac Surgery, Phillips University, Marburg, Germany.

***Corresponding Author:** Mohamed Eraqi, Department of Cardiac Surgery, Klinikum Bayreuth GmbH, Bayreuth, Germany.

Received Date: May 05, 2025 | **Accepted Date:** May 22, 2025 | **Published Date:** May 30, 2025

Citation: Mohamed Eraqi, Ketak Nagare, Tamer Ghazy, (2025), Intraoperative Innominate Vein Perforation Due to Malpositioned Central Venous Catheters: A Dual Hazard with Fatal Outcome, *International Journal of Clinical Case Reports and Reviews*, 26(3); DOI:10.31579/2690-4861/823

Copyright: © 2025, Mohamed Eraqi. This is an open-access article distributed under the terms of the Creative Commons Attribution License, which permits unrestricted use, distribution, and reproduction in any medium, provided the original author and source are credited.

Abstract:

This case report highlights a rare but catastrophic complication of central venous catheter (CVC) malposition during cardiac surgery. An 81-year-old woman with a thoracic aortic aneurysm and moderate aortic valve insufficiency developed an iatrogenic Type A aortic dissection following coronary angiography, resulting in hemorrhagic pericardial effusion and cardiogenic shock. Emergency surgery involved a Bentall procedure, partial aortic arch replacement, and coronary artery bypass grafting. Although cardiopulmonary bypass was successfully weaned, massive venous bleeding occurred during sternal closure due to a vascular defect between the left brachiocephalic vein and superior vena cava caused by malpositioned CVCs. Despite initial control with manual compression, the patient suffered refractory hemodynamic instability due to complete loss of venous access, leading to multiple episodes of ventricular fibrillation and intraoperative death. This case underscores the critical importance of vigilant CVC placement and monitoring during complex cardiac surgeries to prevent potentially fatal complications.

Key words: central venous catheter; catheter malposition; cardiac surgery complications; intraoperative bleeding; venous access injury

Introduction

Central venous catheters (CVCs) play an indispensable role in cardiac surgery by providing access for fluid administration, medication delivery, and hemodynamic monitoring. However, the malposition of these catheters can result in severe complications, such as vascular injury, thrombosis, or embolism. The reported incidence of CVC malposition varies from 1% to 6.7%, with mechanical injuries predominantly occurring in the thoracic region [1].

In complex procedures like aortic surgery, CVC malposition poses a dual hazard, causing both mechanical injury and the loss of venous access, which can lead to life-threatening complications. This risk is particularly heightened in patients requiring high-dose catecholamine support, where maintaining vascular access is crucial for hemodynamic stability [2]. Prompt identification and correction of CVC malposition are vital to prevent catastrophic outcomes during surgery [3].

This case report aimed to present a rare but fatal instance of intraoperative vascular perforation caused by malpositioned central venous catheters

during complex aortic surgery, emphasizing the need for vigilant catheter placement and intraoperative monitoring to prevent similar complications.

Case Presentation

An 81-year-old female patient with a history of thoracic aortic aneurysm measuring 54 mm and moderate aortic valve insufficiency over several years had previously declined surgical intervention. She presented with recurrent atypical chest pain. An elective diagnostic coronary angiography was scheduled. During the procedure, the patient experienced an iatrogenic Type A aortic dissection (**Figure. 1**) following multiple unsuccessful attempts to cannulate the right coronary ostium. Subsequently, she was promptly referred to our hospital and admitted to the intensive care unit (ICU) in cardiogenic shock due to a hemorrhagic pericardial effusion, indicative of early cardiac tamponade. Computed tomography (CT) angiography revealed a Type A dissection extending from the aortic root to the superior mesenteric artery. Emergency surgery was initiated after obtaining verbal informed consent from the patient and her daughter.

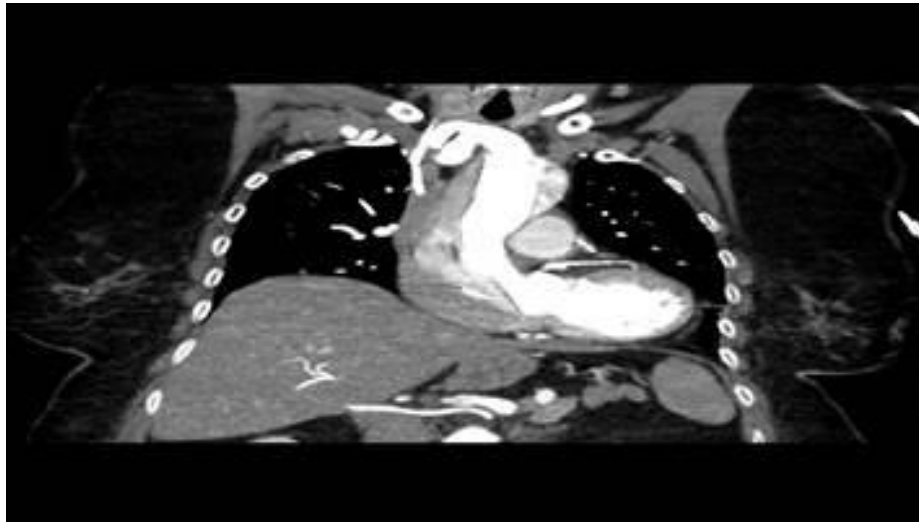


Figure 1: Chest CT Angiography, Coronal View showed a Type A aortic dissection within an aneurysmally dilated aorta.

Alongside standard perioperative monitoring, a central venous catheter (CVC) was inserted into the left subclavian vein to complement the pre-existing right internal jugular vein CVC that had been placed at the referring hospital.

Surgical Strategy

Intraoperatively, dissection involving the brachiocephalic trunk, the left common carotid artery, and the right subclavian artery was identified. Arterial cannulation was performed via the right femoral artery using a 20-Fr cannula and an 8-mm prosthetic graft placed in the distal left carotid artery. The patient was cooled to 28 °C, and selective antegrade cerebral perfusion was established following clamping of the aortic arch vessels.

Upon opening the ascending aorta, an intimal tear was discovered above the ostium of the right coronary artery (entry point), with dissection involving the right coronary ostium.

The surgical procedures performed included:

- Partial aortic arch replacement with a 32-mm vascular prosthesis,

- Aortic root replacement (modified Bentall procedure) with a 30-mm conduit, biological aortic valve replacement using a 25-mm Carpentier-Edwards PERIMOUNT Magna Ease aortic (Edwards Lifesciences LLC), and Reimplantation of the left coronary ostium [4],
- Aorto-coronary bypass grafting to the right coronary artery (RCA) using the left great saphenous vein (flow: 96 mL/min, pulsatility index [PI]: 1.5, diastolic flow [DF]: 63%).

Weaning from cardiopulmonary bypass proceeded uneventfully, with good myocardial contractility. However, high doses of vasopressor support (norepinephrine at 0.03 µg/kg/min and vasopressin at 0.1 units/min) were necessary due to low systemic vascular resistance. Following the achievement of satisfactory hemostasis, the surgical field was inspected, and closure of the right groin and sternum was performed.

During sternal wiring, sudden massive venous bleeding occurred. Re-exploration revealed a large defect (approximately 2 cm × 2 cm) between the left brachiocephalic vein and the superior vena cava, located in close proximity to the tips of the two malpositioned inserted CVCs (right internal jugular vein and left subclavian vein) (**Figure. 2 and 3**).

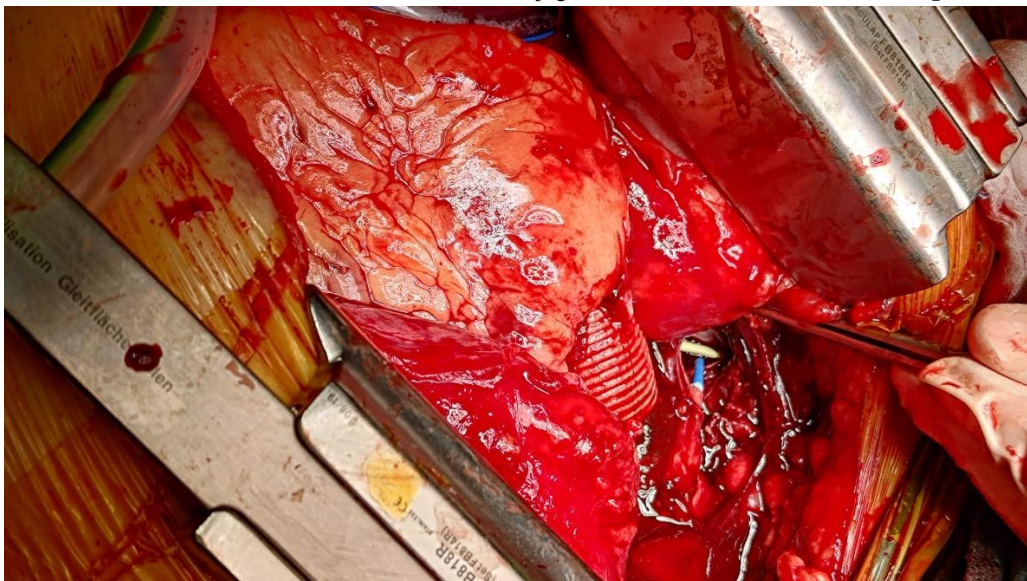

Figure 2

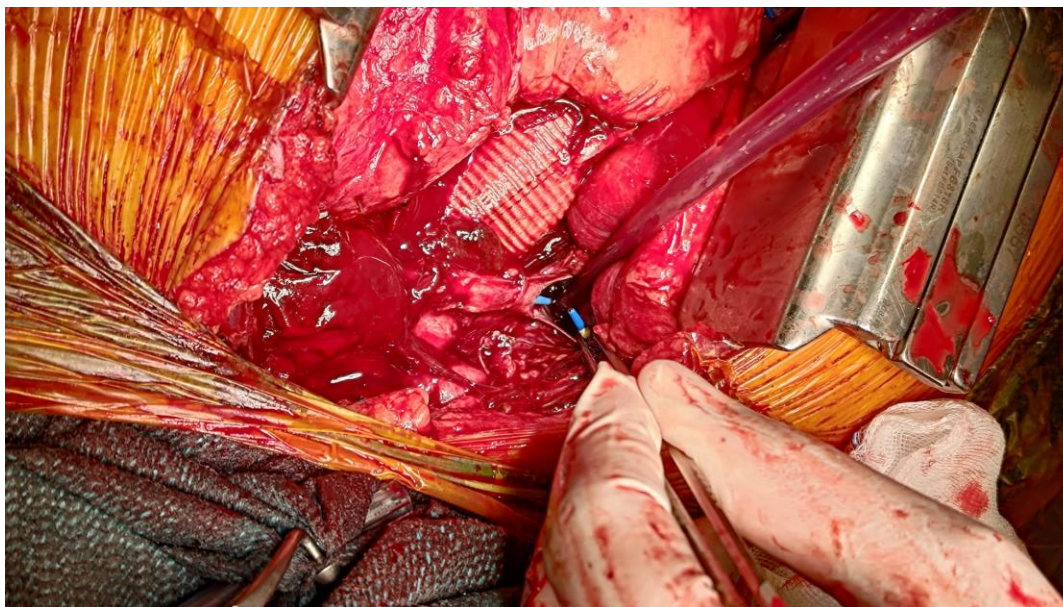

Figure 3

Figures 2 and 3: Intraoperative view showing a large venous defect at the junction of the left brachiocephalic vein and the superior vena cava. The tip of the central venous catheters (**white** and **blue**) is visible near the site of injury.

Manual compression was applied to the defect and the superior vena cava to achieve hemostasis; however, this maneuver led to the complete functional loss of venous access in a critically catecholamine-dependent, vasoplegic patient.

Subsequently, the patient experienced rapid hemodynamic instability, leading to multiple episodes of ventricular fibrillation. Several direct current (DC) shocks and prolonged internal cardiac massage (approximately 40 minutes) were required. A new venous access via the left femoral vein was established after approximately 15 minutes. Recommencing the cardiopulmonary bypass was extremely challenging and 'x' was not possible. Despite maximal resuscitative efforts, the patient unfortunately succumbed intraoperatively.

Discussion

Central venous catheters (CVCs) are routinely used during cardiac surgery; however, malpositioning can result in rare yet catastrophic complications. Regardless of the insertion site, catheter tip malposition poses the risk of vascular wall perforation. While optimal tip positioning remains a topic of debate, there is a consensus that the catheter should terminate within a large central vein, typically the superior vena cava (SVC), ideally outside the pericardial sac and oriented parallel to the vessel's long axis [5]. A tip that abuts the vessel or cardiac wall at an acute angle, as observed in our case, heightens the risk of perforation [6].

Schummer et al. proposed an anatomical zoning system of the central venous system—Zone A (lower SVC to upper right atrium), Zone B (upper SVC to the confluence of the innominate veins), and Zone C (left innominate vein). For safety, right-sided catheters should terminate in Zone B, while left-sided catheters should only be placed in Zone A. Placement in Zone C is discouraged due to higher complication risk as seen in our case (**Figure. 2 and 3**) [7].

Several authors, including Roland et al., have emphasized the importance of keeping the catheter tip within the designated "safe zones" to prevent adverse outcomes [1, 5, 8]. Right-sided CVCs are generally preferred over

left-sided approaches due to a lower risk of dysfunction and malposition. The left brachiocephalic vein, being anatomically longer and more tortuous—approximately 4.5 cm longer than its right counterpart—and following an oblique caudal course over the aortic arch, is predisposed to sharp angulation, particularly as it crosses the midline. This anatomical feature, often overlooked on standard frontal chest imaging, can lead to increased catheter torque, endothelial irritation, and potential perforation [7, 9].

A probable contributing factor to the vascular perforation in this case was an intraoperative incident where the infusion pump signaled a high-pressure alarm. In response, manual manipulation of the catheter, specifically attempts to adjust its position, was performed to restore function without confirming proper tip placement. Given that the catheter tips were already lodged in a thin-walled venous segment, such manipulation may have exacerbated mechanical stress on the vessel wall, ultimately resulting in perforation as depicted in **Figures 1 and 2**.

In this case, the patient's advanced age and the fragility of venous walls may have further increased susceptibility to injury. Additionally, the high infusion rates and large fluid volumes administered intraoperatively likely contributed to vessel damage [8]. Kajiyama et al. reported a similar case in which intraoperative rapid transfusion was implicated in vascular rupture [10]. Smith et al. also highlighted that high-flow jets and hypertonic or irritant drugs delivered through a malpositioned catheter can exacerbate endothelial damage [8].

Conclusion

This case underscores the dual risks associated with malpositioned central venous catheters: mechanical venous injury and the functional loss of critical vascular access. It emphasizes the critical importance of careful intraoperative management and precise verification of CVC positioning to avert such fatal outcomes, particularly during complex aortic surgeries.

References:

1. Roldan, C. J., & Paniagua, L. (2015). Central venous catheter intravascular malpositioning: Causes, prevention, diagnosis, and correction. *Western Journal of Emergency Medicine*, 16(5):262-268.
2. Wicky, S., Meuwly, J. Y., Doenz, F., Uské, A., Schnyder, P., & Denys, A. (2002). Life-threatening vascular complications after central venous catheter placement. *European Radiology*, 12(4):1018-1025.
3. Pikwer, A., Bååth, L., Davidson, B., Perstoft, I., & Åkeson, J. (2008). The incidence and risk of central venous catheter malpositioning: A prospective cohort study in 1619 patients. *Anaesthesia and Intensive Care*, 36(1):106-112.
4. Cherry, C., DeBord, S., & Hickey, C. (2006). The modified Bentall procedure for aortic root replacement. *AORN Journal*, 84(1):98-107.
5. Hade, A. D., Beckmann, L. A., & Basappa, B. K. (2019). A checklist to improve the quality of central venous catheter tip positioning. *Anaesthesia*, 74(7):1467-1479.
6. Gibson, F., & Bodenham, A. (2013). Misplaced central venous catheters: Applied anatomy and practical management. *British Journal of Anaesthesia*, 110(5):897-905.
7. Chen, Y. J., Chung, S. C., & Liu, Y. C. (2018). Delayed Malposition of Central Venous Catheter Induced Mediastinum Hematoma with Innominate Vein Perforation. *Asian Journal of Anesthesiology*, 56(2):5-12.
8. Smith, T., Kaufman, C., & Quencer, K. (2022). Internal Jugular Central Venous Catheter Tip Migration: Patient and Procedural Factors. *Tomography*, 8(2):83-91.
9. Salik, E., Daftary, A., & Tal, M. G. (2007). Three-dimensional Anatomy of the Left Central Veins: Implications for Dialysis Catheter Placement. *Journal of Vascular and Interventional Radiology*, 18(3):721-729.
10. Kajiyama, S., Migita, T., Saeki, N., & Kawamoto, M. (2011). A case of large vein perforation by pumping using central venous catheter revealed by postoperative CT. *Japanese Journal of Anesthesiology*, 60(10):123-130.



This work is licensed under Creative Commons Attribution 4.0 License

To Submit Your Article Click Here:

[Submit Manuscript](#)

DOI: [10.31579/2690-4861/823](https://doi.org/10.31579/2690-4861/823)

Ready to submit your research? Choose Auctores and benefit from:

- fast, convenient online submission
- rigorous peer review by experienced research in your field
- rapid publication on acceptance
- authors retain copyrights
- unique DOI for all articles
- immediate, unrestricted online access

At Auctores, research is always in progress.

Learn more <https://auctoresonline.org/journals/international-journal-of-clinical-case-reports-and-reviews>