

Diffuse Xanthonychia and Bronchorrhea Revealing Yellow Nail Syndrome

Hajar Moata ^{1*}, Fouzia Hali ¹, Hajar Arfaoui ², Hajar Bamha ², Salma Msika ², Hasna Jabri ², Wiam El Khattabi ², Hicham Aff ², Soumiya Chiheb ¹

¹ Department of Dermatology and Venerology. Ibn Rochd University Hospital, Casablanca.

² Respiratory disease department of "20 Août 1953" hospital. Ibn Rochd University Hospital. Casablanca.Morocco

*Corresponding Author: Hajar Moata, Department of Dermatology and Venerology. Ibn Rochd University Hospital, Casablanca.

Received date: December 05, 2023; Accepted date: December 13, 2023; Published date: December 22, 2023

Citation: Hajar Moata, Fouzia Hali, Hajar Arfaoui, Hajar Bamha, Salma Msika, et al, (2023), Diffuse Xanthonychia and Bronchorrhea Revealing Yellow Nail Syndrome, *Dermatology and Dermatitis*, 9(1); DOI:10.31579/2578-8949/136

Copyright: © 2023, Hajar Moata. This is an open-access article distributed under the terms of The Creative Commons. Attribution License, which permits unrestricted use, distribution, and reproduction in any medium, provided the original author and source are credited.

Abstract

Yellow nail syndrome (YNS) is a rare clinical entity. It is characterized by yellow and thickened nails, lymphedema and/or chronic respiratory manifestations. Etiopathogenesis of YNS is still not elucidated. The treatment is mainly symptomatic.

Keywords: diffuse xanthonychia; bronchorrhea; yellow nail syndrome

Introduction

A 21-year-old man consulted for a modification of the aspect of his 20 nails, treated as onychomycosis with no improvement. The patient also reported recurrent respiratory infections and bronchorrhea for 10 years.

There were no similar cases in the family. Physical examination revealed dystrophic nails, diffuse xanthonychia and pachyonychia associated with subungual hyperkeratosis (figure 1).

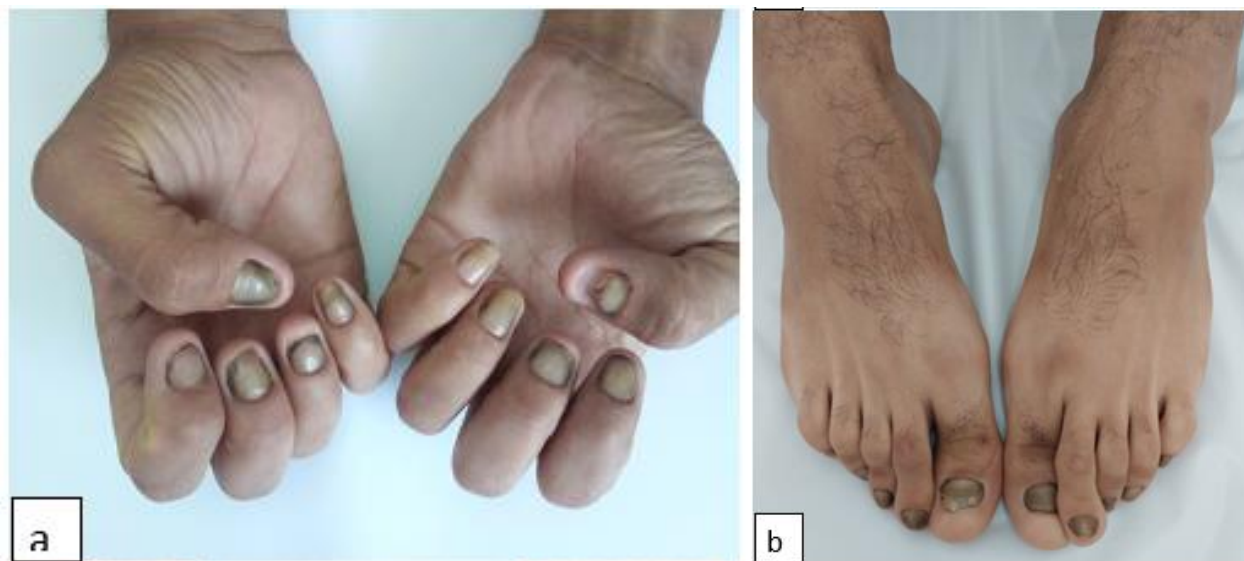


Figure 1(a,b) : Diffuse Xanthonychia

There was no lymphoedema. Mycology culture was sterile.

The association of diffuse xanthonychia and chronic respiratory manifestations is suggestive of yellow nail syndrome (YNS). The chest X-ray shows a tram-track sign, and computed tomography reveals a signet ring sign (figure 2), confirming the diagnosis of bronchiectasis.

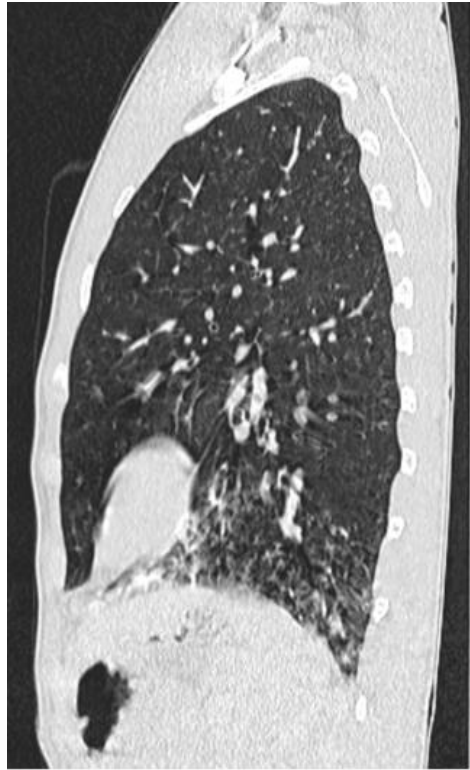

Figure 2: Computed tomography: signet ring sign (bronchiectasis)

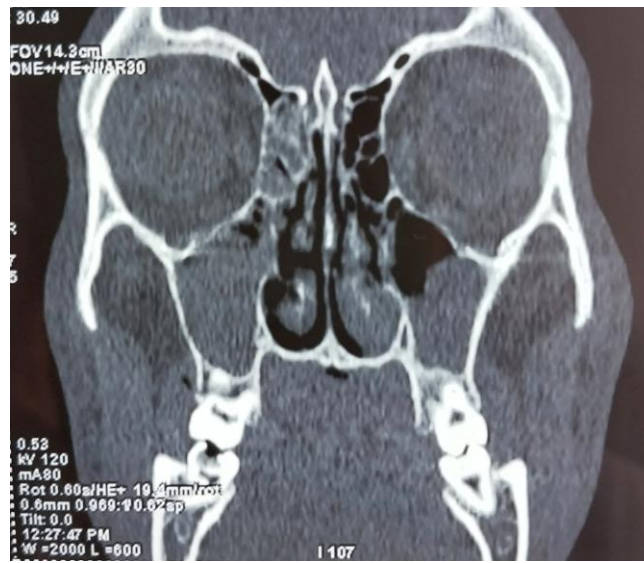


Figure 3: Computed tomography of the sinuses: mucosal thickening

Computed tomography of the sinuses objectives mucosal thickening obliterating the right maxillary sinus and a polypoid aspect in the left maxillary sinus.

YNS triad is defined by diffuse xanthonychia, lymphedema, usually affecting the lower limbs, and respiratory manifestations represented, in our case, by bronchiectasis and chronic sinusitis. The Other thoracic manifestations reported in the literature include pleural effusion, chronic cough, recurrent pneumonia and pulmonary fibrosis [1].

Lymphedema was absent in our patient, but xanthonychia of the 20 nails and chronic respiratory involvement were sufficient to retain the diagnosis of YNS. The pathogenesis of this syndrome remains poorly understood, probably involving anatomical and/or functional abnormalities of the lymphatic system [2]. The interest of diagnosing YNS resides in its associations with various endocrine, lymphatic and autoimmune diseases. Cases of associated neoplasia have also been reported in the literature. Therefore, YNS can be considered a paraneoplastic syndrome. In our case, full blood count, thyroid function

and immunological tests including anti-nuclear, **anti-DNA** antibodies, and rheumatoid factor were normal. Abdominal ultrasound and tumor markers revealed no abnormalities. The prognosis of YNS is variable. It depends on both associated diseases and YNS related symptoms, varying from a modification of the nail color to severe manifestations including cellulitis complicating severe lymphedema or resistant and recurrent pulmonary infections. There is no curative treatment for YNS. Treatment aims to improve the various symptoms [3].

References

1. Vignes S, Baran R. (2017). Yellow nail syndrome : à review. Orphanet J Rare Dis, 27 :12(1) :42.
2. Letheulle J, Deslée G, Guy T, Lebargy F, Jégo P, Delaval P, Desrues B, Jouneau S. (2012). Le syndrome des ongles jaunes : présentation de cinq cas [The yellow nail syndrome : à series of five cases]. Rev Mal Respir, 29(3) :419-425.
3. Cheslock M, Harrington DW. (2022). Yellow Nail Syndrome. StatPearls [Internet]. Treasure Island (FL) : StatPearls Publishing.



This work is licensed under Creative Commons Attribution 4.0 License

To Submit Your Article Click Here:

[Submit Manuscript](#)

DOI:10.31579/2578-8949/136

Ready to submit your research? Choose Auctores and benefit from:

- fast, convenient online submission
- rigorous peer review by experienced research in your field
- rapid publication on acceptance
- authors retain copyrights
- unique DOI for all articles
- immediate, unrestricted online access

At Auctores, research is always in progress.

Learn more <https://auctoresonline.org/journals/dermatology-and-dermatitis>