

Dural venous sinus angioplasty and stenting for treatment of idiopathic intracranial hypertension: a single-center experience with 20 consecutive cases

Vinicius Moreira Lima *, Clara Demeneck Pereira, Plinio Rodrigo Maximo, Marcelle Rehem, Noel Peixoto, Bruno de Sousa Mendes Parente, Eduardo Siqueira Waihrich

¹Department of Neurosurgery, Instituto Hospital de Base do Distrito Federal, SMHS, Área Especial, quadra 101, 70330-150, Brasília, DF, Brazil.

²Hospital Universitário de Brasília, Setor de Grandes Áreas Norte, 605, Asa Norte, 70840-901, DF, Brazil.

***Corresponding Author:** Vinicius Moreira Lima, Department of Neurosurgery, Instituto Hospital de Base do Distrito Federal, SMHS, Área Especial, quadra 101, 70330-150, Brasília, DF, Brazil.

Received date: May 10, 2024; **Accepted date:** May 27, 2024; **Published date:** June 14, 2024

Citation: Vinicius M. Lima, Clara D. Pereira, Plinio R. Maximo, Marcelle Rehem, Noel Peixoto, et al, (2024), Dural venous sinus angioplasty and stenting for treatment of idiopathic intracranial hypertension: a single-center experience with 20 consecutive cases, *J. Neuroscience and Neurological Surgery*, 15(5); DOI:10.31579/2578-8868/320

Copyrights: © 2024, Vinicius Moreira Lima. This is an open-access article distributed under the terms of The Creative Commons Attribution License, which permits unrestricted use, distribution, and reproduction in any medium, provided the original author and source are credited

Abstract

Background: Dural venous sinus stenosis has been shown to be a potential cause or aggravating factor of idiopathic intracranial hypertension (IIH). Endovascular therapy for angioplasty of venous sinus stenosis is emerging as a potential alternative to treat IIH.

Objective: This article aims to present the results of a cases series representing the experience of a single center in treating this disease.

Materials and Methods: We retrospectively reviewed the angiographic and manometric data of patients undergoing angioplasty and stenting for the treatment of IIH with venous sinus stenosis on magnetic resonance angiography. All patients had failed conventional medical treatment. Data on demographic features, clinical and radiologic presentation, and outcomes were collected retrospectively.

Results: 20 female patients, with persistent headache and papilledema, underwent venous sinus angioplasty and stenting. Mean age was 35.9 (SD, 10) years. Eighteen patients (90%) had clinical improvement after the procedure. Of these, all showed resolution (17 patients, 94%) or partial improvement (1 patient, 6%) of papilledema within 6 months. Two patients had persistent moderate-to-severe headache (intensity > 6 on a 10-point pain scale), with continued papilledema despite stable visual acuity on visual field testing. The mean pre-procedure lumbar puncture opening pressure was 30.1 (SD, 4) mm Hg, decreasing to 16.2 (SD, 4) mm Hg after the procedure. Only 4 patients experienced complications directly or indirectly related to the procedure, with no impact on outcome.

Conclusion: Angioplasty and stenting of the stenotic segment may effectively and safely treat IIH associated with focal venous sinus stenosis, with a high technical success rate and an acceptable complication rate.

Keywords: idiopathic intracranial hypertension; dural sinus stenosis; angioplasty; stent

Abbreviations

IIH: idiopathic intracranial hypertension CSF: cerebrospinal fluid

ICP: intracranial pressure

VAS: visual analog scale

SD: standard deviation

Introduction

Idiopathic intracranial hypertension (IIH), also known as pseudotumor cerebri, is a potentially debilitating disease with an average prevalence of 1 case per 100,000 population, preferentially affecting young women (aged 20 to 44 years).[1-3] The disease is characterized by decreased visual acuity, progressive headache, and pulsatile tinnitus associated with

elevated cerebrospinal fluid (CSF) opening pressures on lumbar puncture.[1,2] Visual disturbance results from the transmission of intracranial pressure (ICP) to the optic nerve sheath, leading to bilateral papilledema, present in up to 95% of cases.[2,3] If left untreated, IIH can lead to optic nerve atrophy and permanent visual loss.[2-4]

Diagnosis is based on the criteria developed by Walter Dandy in 1937, modified over time as the understanding of the disease has advanced.[5,6] The most widely accepted criteria are (1) signs and symptoms referable only to elevated ICP, (2) CSF opening pressure > 25 cm H₂O, (3) normal CSF composition, and (4) no evidence of mass lesion or other structural cause using modern imaging techniques.[6]

The cause of increased ICP remains controversial, and this doubt is responsible for different philosophies to approach the disease. However, intracranial venous hypertension leading to decreased CSF reabsorption has been implicated as a potential common pathway of IIH.[8,11] Recent studies have shown a direct relationship between the presence of focal stenosis in the dural sinuses, often in the sigmoid, transverse, or superior sagittal sinuses, and the presence of IIH. Focal stenosis was demonstrated in 30%-93% of patients with IIH vs 6.8% of the control population.[10] In a positive feedback loop, regardless of the initial cause of focal stenosis, venous hypertension proximal to the stenotic area leads to increased ICP causing continued extrinsic stenosis or worsening of pre-existing stenosis.[12]

Traditional treatment of IIH consists initially of the use of carbonic anhydrase inhibitors, reducing CSF production, and serial lumbar punctures for relief.[15, 21]. In case of treatment failure, CSF diversion procedures, especially lumboperitoneal shunt placement or optic nerve sheath fenestration, may be indicated.[14,15] Other measures such as weight loss, in some cases even requiring gastric bypass, can be effective in reducing ICP and improving visual symptoms.[14]

The success rate in controlling the disease reaches up to 80% of cases immediately after these procedures. However, recurrence of symptoms at 1 year can reach 50% for ventriculoperitoneal shunts and 40% for optic nerve sheath fenestration, [16] especially in patients with poor adherence to medical treatment.

With advances in neuroimaging, showing that most patients with IIH may have structural abnormalities of the venous sinuses, and improvements in endovascular techniques, adequate diagnosis of focal stenosis followed by venous sinus angioplasty and stenting has emerged as a potentially effective treatment strategy for IIH, although concrete data regarding its long-term durability and effectiveness are still lacking.[10,11,18, 19] In this paper, we present a series of 20 consecutive cases of patients with IIH with venous sinus stenosis treated with angioplasty and stenting in a single center.

Materials and Methods

We retrospectively reviewed 20 consecutive cases of female patients with confirmed IIH, receiving medical treatment in the neurology department, who underwent endovascular treatment with dural venous sinus angioplasty and stenting. Data on demographic features, clinical presentation, peri-procedural complications, and clinical-neurologic monitoring were collected. Regarding neurologic findings, the following variables were evaluated: headache type and intensity (visual analog scale [VAS]), tinnitus, presence or absence of papilledema, visual deficits documented by an ophthalmologist, and lumbar puncture opening pressure.

All patients received standard medical treatment with a carbonic anhydrase inhibitor and serial lumbar punctures for at least 3 months (with intervals of 2 to 4 weeks based on clinical progress), in addition to

encouragement of behavioral changes (weight loss, physical activity). All patients had intrinsic or extrinsic stenosis in at least one dural venous sinus seen on magnetic resonance angiography evaluated by a neuroradiologist with no involvement in the intervention. During angiographic examination, in addition to confirming the stenotic lesion, pre- and post-stenosis manometry was performed to assess the real indication for stenting as previously defined (gradient > 8 mm Hg).

Data collected during the procedures included stenosis location and side, balloon used and stent placed, peri-procedural complications, procedure-related angiographic changes, stenosis severity, and pressure gradient in the stenotic area.

After a literature search and review in the main available sources, a comparison was made with the data obtained in this series.

Procedure

All procedures were performed with the patients under general anesthesia. All patients were pretreated with dual antiplatelet therapy starting 5 days before the procedure: 9 patients with aspirin 100 mg daily + clopidogrel 75 mg daily; and 11 patients with aspirin 100 mg daily + ticagrelor 90 mg every 12 hours.

Arterial access was obtained via the femoral artery with a 5F introducer sheath to perform cerebral digital subtraction angiography and to confirm the stenotic lesion and side, in addition to venous roadmap imaging. Venous access was obtained via the femoral vein in 80% of cases (16 patients) with an 8F introducer sheath or directly with a long sheath (Neuromax 088 or BMX 096). In the remaining patients, access was obtained via direct puncture of the jugular vein according to the side of the target stenotic region. All punctures were ultrasound guided to reduce access-related complications. After venous access, patients received 5000 IU of intravenous heparin.

Using a navigation system (select catheter and hydrophilic guidewire within a long sheath), the long sheath was placed at the level of the jugular bulb ipsilateral to the stenotic lesion to facilitate navigating the microcatheter distal to the stenosis. A 0.027-inch microcatheter was placed within the sheath and navigated over a 0.014-inch guidewire into the transverse-sigmoid sinus, and upstream and downstream pressure measurements were obtained from the stenosis. The stent would only be deployed if the pre- and post-stenotic pressure difference (gradient) was above 8 mm Hg, which was confirmed in all cases reported in this series. After pressure measurements, the microcatheter was removed and the 0.014-inch guidewire was advanced as far distally and safely as possible from the stenosis (superior sagittal sinus or contralateral jugular bulb), and then the stent was deployed across the stenosis. In cases of increased vessel tortuosity and navigation difficulties, an intermediate catheter (Benchmark 071) was used to assist with navigation and stent placement. Different stents were used to perform angioplasty, and the choice depended on patient-related factors (stenosis location and severity, vessel tortuosity, and difficulty in accessing and positioning components) as well as on the availability of stents. Details of the stents placed are provided below. In case of residual stenosis, compliant balloon post-dilation was performed.

Dual antiplatelet therapy was continued for 6 months after the procedure for all patients, and at least one follow-up computed tomography angiography or digital subtraction angiography was performed within 6 months.

Case 1: Young patient diagnosed with medically refractory IIH with headache and papilledema, with angiographic diagnosis of dural venous sinus stenosis at the right transverse-sigmoid sinus junction and venous manometry showing a gradient of 12 mm Hg (Figure 1).

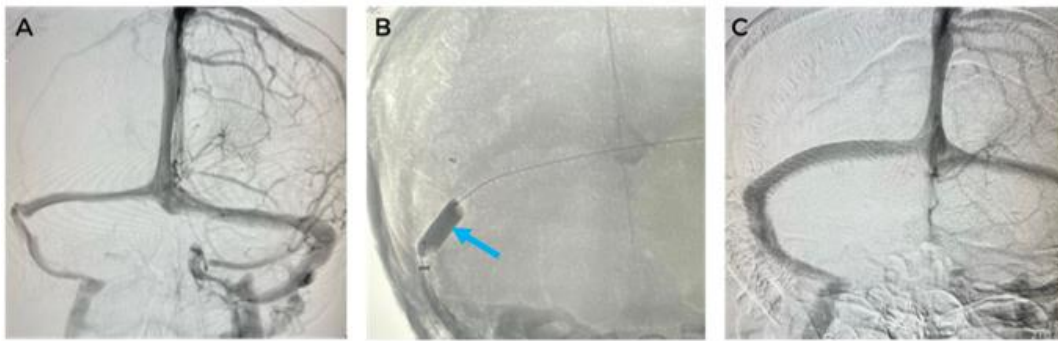


Figure 1. Pre- and post-procedure images of venous sinus angioplasty with placement of 2 telescoping carotid stents (CASPER) and balloon. (A) Panoramic angiogram in the venous phase, anteroposterior (AP) view. (B) Primary balloon angioplasty at the site of focal stenosis before inserting the guiding catheter for stent placement. C: Final result after stent implantation, AP view.

Case 2: Young patient diagnosed with IIH with progressive visual loss, with angiographic diagnosis of dural venous sinus stenosis at the right transverse-sigmoid sinus junction and venous manometry showing a gradient of 10 mm Hg (Figure 2).

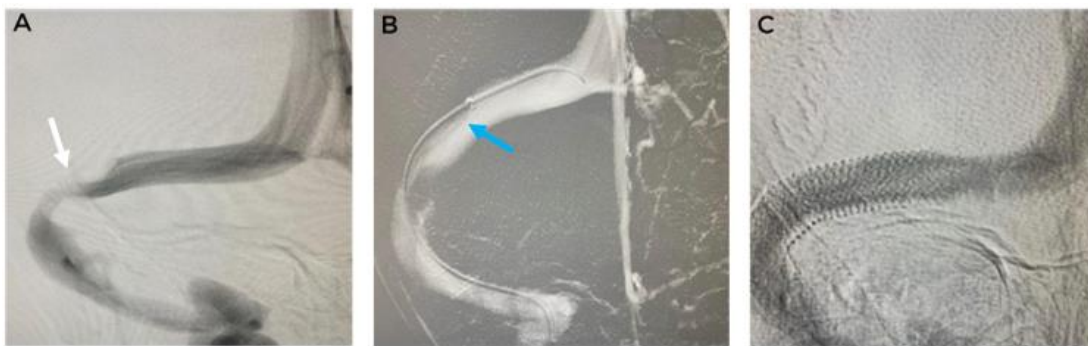

Figure 2. Pre- and post-procedure images of venous sinus angioplasty with placement of 1 carotid stent (PRECISE). Post-angioplasty manometry with a gradient of 0 mm Hg. (A) Venous phase angiogram, anteroposterior (AP) view, showing stenosis of the right transverse-sigmoid segment. (B) Navigation of the support system distal to the site of stenosis for subsequent stent deployment. (C) Final result after stent implantation, AP view.

Results

From November 2015 to April 2023, 20 female patients diagnosed with IIH and stenosis in at least one dural sinus were treated with angioplasty and stenting at our institution. Table 1 shows the demographic and clinical characteristics of the study sample (Table 1). All patients were women,

with a mean age of 35.9 (SD, 10) years. All patients had daily holocranial headache refractory to analgesics, with a mean intensity of 8.1 (SD, 1.4) on a 10-point VAS, papilledema, and some degree of decreased visual acuity. Five patients had associated pulsatile tinnitus. The mean pre-procedure lumbar puncture opening pressure was 30.1 (SD, 4) mm Hg.

Mean age	35.9 (±10) years	
Symptoms and clinical findings	Pre-angioplasty	Post-angioplasty (6-month follow-up)
Headache frequency (headaches with pain intensity of VAS >3)	20/20	6/20
Headache intensity (mean)	8.1 (± 1.4)	2.65 (± 2)
Tinnitus	5	1
Visual acuity	18/20	5/20
Papilledema	20/20	3/20
Opening pressure	30.1 (± 4) mm Hg	16.2 (± 4) mm Hg
Pressure gradient	15 (± 4) mm Hg	2.8 (± 1.7) mm Hg

Legend: VAS, visual analog scale.

Table 1. Demographic and clinical data of the study sample (n = 20 female patients)

At 6-month follow-up, headache improved substantially in 90% (18/20) of patients, with 12 patients showing near-resolution of headache in frequency and intensity (VAS < 3), with the mean intensity decreasing to 2.65 (SD, 2) in 10 of all 20 patients. Tinnitus was eliminated in 4 of the 5 patients reporting tinnitus prior to the intervention. CSF opening pressure on follow-up lumbar puncture decreased to 16.2 (SD, 4.3) mm Hg, and papilledema resolved in 85% (17/20) of patients. No patient had worsening of visual acuity on ophthalmologic examination, with 75% reporting improvement and 25% stabilization of vision compared with pre-procedure visual acuity.

Headache, papilledema, and lumbar puncture opening pressure did not improve in 1 patient, and her treatment was considered to have failed.

The mean pre-procedure trans-stenosis pressure gradient decreased from 15 (SD, 4) mm Hg to 2.8 (SD, 1.7) mm Hg in patients with successful angioplasty. Even in the patient with a failed treatment at the end of follow-up, a post-angioplasty gradient < 8 mm Hg was obtained (cutoff to indicate treatment).

Regarding stenosis location, 9 occurred in the transverse sinus (3 right and 6 left), 3 in the sigmoid sinus (2 right and 1 left), and 7 in the

transverse-sigmoid junction (4 right and 3 left). In 1 case, stents were placed at 2 different sites of stenosis (1 in the transverse sinus and 1 in the jugular bulb), both on the same side (on the left). Regarding stents, 19 were self-expanding stents (5 WallStent, 7 Casper, 5 Precise, and 2 CGuard) and 1 was a balloon-mounted stent (Table 2).

There were no intraoperative complications, but 1 patient developed a large inguinal hematoma in the first 24 hours post-procedure, without clinical or laboratory repercussions, which was managed conservatively.

One patient developed significant gastrointestinal bleeding after 3 months of antiplatelet therapy, and clopidogrel was discontinued at the time, without neurologic repercussions. The patient had a patent stent on the 6-month follow-up angiography.

On the 6-month follow-up angiography, 1 patient showed a new stenosis proximal to the stented segment, without clinical repercussions, which was managed conservatively. No instances of in-stent thrombosis or significant neointimal hyperplasia were observed. The patient whose treatment was considered to have failed showed no abnormal findings on follow-up angiography and was referred for evaluation for lumboperitoneal shunt placement.

Stenosis location	Side	Stent placed	Complications (overall)	Follow-up imaging (6 months)
Transverse	L	WallStent	Gastrointestinal bleeding	Patent stent
Transverse	L	WallStent	—	Patent stent
Sigmoid	L	WallStent	—	Patent stent (new stenosis proximal to the stent)
Sigmoid	R	Casper	—	Patent stent
Transverse	R	Casper	Hematoma at the puncture site	Patent stent
Transverse	L	WallStent	—	Patent stent
Transverse	L	Casper	—	Patent stent
Sigmoid	R	WallStent	—	Patent stent
Transverse	L	Casper	Failed treatment	Patent stent
Transverse and sigmoid	R	Precise	—	Patent stent
Transverse	R	Casper	—	Patent stent
Transverse	R	Precise	—	Patent stent
Transverse	L	Precise	—	Patent stent
Transverse and jugular bulb	L	Casper	Vocal cord paralysis secondary to intubation (resolved with speech therapy)	Patent stent (on CT angiography)
Transverse and sigmoid	R	Precise	—	Patent stent
Transverse and sigmoid	L	Balloon-mounted stent (Medtronic)	—	Patent stent (on CT angiography)

Transverse and sigmoid	R	Casper	—	Patent stent
Transverse and sigmoid	L	Precise	—	Patent stent (on CT angiography)
Transverse and sigmoid	L	CGuard	—	Patent stent (on CT angiography)
Transverse and sigmoid	R	CGuard	Small cortical SAH immediately after, without clinical repercussions	Patent stent (on CT angiography)

Legend: L: left; R: right; CT: computed tomography, SAH: subarachnoid hemorrhage.

Table 2. Angioplasty data

Discussion

IIH remains a poorly understood disease with an important predilection for overweight young women. Every year, 0.9 to 1.07 per 100.000 persons develop IIH.[1,10] Generally, these patients present with pulsatile tinnitus, papilledema, and progressive visual loss.[1,2] Recent studies have demonstrated an association between focal stenosis in the dural venous sinus outflow and IIH in up to 93% of cases.[1,10] Apparently, these stenoses can act as a cause or aggravating factor of the disease to such an extent that angioplasty of the stenotic lesions has proven to be a new treatment strategy.[18]

Unfortunately, failure to diagnose venous stenosis is not rare, with the stenotic lesion being interpreted as a normal anatomic variant or the presence of arachnoid granulations. Higgins et al evaluated 20 patients with IIH whose brain magnetic resonance angiography scans were initially reported as normal and later assessed specifically for stenoses. Of the 20 patients, 13 were reclassified as having some degree of stenosis.[16]

In the present study, most patients (90%) showed some clinical improvement, whether subjective (headache and tinnitus) or objective (papilledema and CSF opening pressure). Although only 60% (12/20) of patients showed resolution or near-resolution of all symptoms, there was no progression of visual loss in the study sample (visual acuity stabilized or improved in 100% at 6-month follow-up), highlighting the positive impact of the treatment used.

Our data are consistent with other recently published series. Regarding headache, most case series report improvement but not complete resolution for the majority of patients.[1,2,10,16,17] One case series reported that 10 of 12 patients had persistent headache in some form, although papilledema resolved in all of them.[1] A case series from the Barrow Neurological Institute reported only improvement of headache, without complete resolution of symptoms.[10] In our series, one patient showed no clinical improvement, in addition to maintaining elevated CSF opening pressure on follow-up lumbar puncture despite adequate stent implantation and a pressure gradient consistent with the indication for angioplasty, being the only patient in the sample considered to have a failed treatment. This patient showed significant weight gain (12 kg in 6 months), and this factor influenced her response to treatment, as impaired venous return at the thoracic level and the consequent reduction in dural venous sinus outflow can explain this condition. A second patient had only partial improvement of headache and visual acuity, with a stable visual field (unchanged papilledema on ophthalmologic examination) and normal opening pressure at 6-month follow-up. Optimized medical therapy was maintained and close monitoring of symptoms and papilledema was proposed.

An important finding was the low complication rate both during and after the procedure. Only 4 patients experienced adverse events: 2 cases of

procedural complications (1 hematoma at the puncture site and 1 cortical subarachnoid hemorrhage); 1 case related to antiplatelet therapy (gastrointestinal bleeding); and 1 case related to orotracheal intubation (vocal cord paralysis). None of the complications resulted in worsening of severity or outcome of the patients within 6 months. Although the systemic bleeding event occurred in the group of patients using clopidogrel, due to our small sample size, we cannot conclude about the efficacy/safety between the two different antiplatelet regimens (aspirin + clopidogrel and aspirin + ticagrelor).

Limitation

A limitation of this study is that the data originate from a retrospective series with a limited number of cases. Nevertheless, the data are in line with those published in the literature and the results are promising. We can infer that dural sinus angioplasty is a safe procedure and that adverse events should become even rarer with the increasing number of cases with an indication for treatment, growing expertise of the teams, and improvements in the techniques and materials used.

Conclusion

In patients diagnosed with IIH associated with focal venous sinus stenosis and venous manometry indicating a pressure gradient >8 mm Hg, angioplasty and stenting of the stenotic segment may represent an effective and safe treatment strategy with a high technical success rate and an acceptable complication rate. The analysis of data from the present study reflects the current clinical evidence, showing that venous sinus stenting is beneficial for these patients. However, larger prospective studies comparing the different treatment approaches, as well as those that show long-term clinical and radiological follow-up are needed to help determine the optimal approach in these patients.

Financial disclosure: This research did not receive any specific grant from funding agencies in the public, commercial, or not-for-profit sectors.

Declarations of interest: None.

References

1. Kumpe DA, Bennett JL, Seinfeld J, Pelak VS, Chawla A, Tierney M. (2012). Dural sinus stent placement for idiopathic intracranial hypertension. *J Neurosurg.* 116:538-548.
2. Fields JD, Javedani PP, Falardeau J, et al. (2013). Dural venous sinus angioplasty and stenting for the treatment of idiopathic intracranial hypertension. *J Neurointerv Surg.* 5:62-68.
3. Mollan SP, Ali F, Hassan-Smith G, Botfield H, Friedman DI, Sinclair AJ. (2016). Evolving evidence in adult idiopathic intracranial hypertension: pathophysiology and management. *J Neurol Neurosurg Psychiatry.* Sep; 87(9):982-992.

4. Shah VA, Kardon RH, Lee AG, Corbett JJ, Wall M. (2008). Long-term follow-up of idiopathic intracranial hypertension: the Iowa experience. *Neurology*. 70:634-640.
5. Lai LT, Danesh-Meyer HV, Kaye AH. (2014). Visual outcomes and headache following interventions for idiopathic intracranial hypertension. *J Clin Neurosci*. Oct;21(10):1670–1678.
6. Friedman DI, Jacobson DM. (2002). Diagnostic criteria for idiopathic intracranial hypertension. *Neurology*. 59:1492-1495.
7. Friedman DI, Jacobson DM. (2002). Diagnostic criteria for idiopathic intracranial hypertension. *Neurology*. Nov;59(10):1492–14925.
8. Friedman DI. (2006). Cerebral venous pressure, intra-abdominal pressure, and dural venous sinus stenting in idiopathic intracranial hypertension. *J Neuroophthalmol*. 26:61-64.
9. Johnston I, Paterson A. (1974). Benign intracranial hypertension. II. CSF pressure and circulation. *Brain*97:301-312.
10. Albuquerque FC, Dashti SR, Hu YC, et al. (2011). Intracranial venous sinus stenting for benign intracranial hypertension: clinical indications, technique, and preliminary results. *World Neurosurg*. 75:648-652.
11. Higgins JN, Cousins C, Owler BK, Sarkies N, Pickard JD. (2003). Idiopathic intracranial hypertension: 12 cases treated by venous sinus stenting. *J Neurol Neurosurg Psychiatry*. 74:1662-1666.
12. Owler BK, Parker G, Halmagyi GM, et al. (2005). Cranial venous outflow obstruction and pseudotumor Cerebri syndrome. *Adv Tech Stand Neurosurg*. 30:107-174.
13. Kesler A, Hadayer A, Goldhammer Y, Almog Y, Korczyn AD. (2004). Idiopathic intracranial hypertension: risk of recurrences. *Neurology*. 63:1737-1739.
14. Fridley J, Foroozan R, Sherman V, Brandt ML, Yoshor D. (2011). Bariatric surgery for the treatment of idiopathic intracranial hypertension. *J Neurosurg*. 114:34-39.
15. Feldon SE. (2007). Visual outcomes comparing surgical techniques for management of severe idiopathic intracranial hypertension. *Neurosurg Focus*. 23:E6.
16. Higgins JN, Gillard JH, Owler BK, Harkness K, Pickard JD. (2004). MR venography in idiopathic intracranial hypertension: unappreciated and misunderstood. *J Neurol Neurosurg Psychiatry*. 75:621-625.
17. Shapiro M, Raz E, Nossek E, et al. (2023). Cerebral venous anatomy: implications for the neurointerventionalist. *J Neurointerv Surg*. 15:452-460.
18. None Raynald, Yang H, Tong X, et al. (2023). Stenting versus medical treatment for idiopathic intracranial hypertension: a matched-control study. *J Neurointerv Surg*. 15:1021-1026.
19. Teleb MS, Cziep ME, Issa M, Lazzaro M, Asif K, Hong SH, Lynch JR, Fitzsimmons BF, Remler BF, Zaidat OO. (2015). Stenting and angioplasty for idiopathic intracranial hypertension: a case series with clinical, angiographic, ophthalmological, complication, and pressure reporting. *J Neuroimaging*. Jan-Feb;25(1):72-80.
20. Spitze A, Malik A, Lee AG. (2014). Surgical and endovascular interventions in idiopathic intracranial hypertension. *Curr Opin Neurol*. Feb;27(1):69–74.
21. Celebisoy N, Gökçay F, Sirin H, Akyürekli O. (2007). Treatment of idiopathic intracranial hypertension: topiramate vs acetazolamide, an open-label study. *Acta Neurol Scand*. Nov;116(5):322–327.



This work is licensed under Creative Commons Attribution 4.0 License

To Submit Your Article Click Here:

Submit Manuscript

DOI: [10.31579/2578-8868/320](https://doi.org/10.31579/2578-8868/320)

Ready to submit your research? Choose Auctores and benefit from:

- fast, convenient online submission
- rigorous peer review by experienced research in your field
- rapid publication on acceptance
- authors retain copyrights
- unique DOI for all articles
- immediate, unrestricted online access

At Auctores, research is always in progress.

Learn more <https://auctoresonline.org/journals/neuroscience-and-neurological-surgery>