

# Open Abdominal Metroplasty for The Treatment of Uterine Septum in A Woman with Uterine Factor Infertility- A Case Report

Ayodeji Kayode Adefemi<sup>1</sup>, Chidinma Magnus Nwogu<sup>2</sup>, Omisakin Sunday Isaac<sup>3,4</sup>, Aloy Okechukwu Ugwu<sup>3,6\*</sup>, Adebayo Awoniyi<sup>3</sup>, Chioma E Obodo<sup>5</sup>, Ijeoma Ohagwu<sup>3</sup>, Kehinde S. Okunade<sup>3,4</sup>

<sup>1</sup>Department of Obstetrics and Gynaecology, Ayinke House, Lagos State University Teaching Hospital, Ikeja, Nigeria.

<sup>2</sup>Department of Obstetrics and Gynaecology, Kingswill Advanced fertility Specialist Hospital, FESTAC Town, Lagos, Nigeria.

<sup>3</sup>Department of Obstetrics and Gynaecology, Lagos University Teaching Hospital, Idi-Araba, Mushin, Lagos, Nigeria.

<sup>4</sup>Department of Obstetrics and Gynaecology, College of Medicine, University of Lagos, Nigeria.

<sup>5</sup>Department of Obstetrics and Gynaecology, Mayqu, Ministry of Health Saudi Arabia.

<sup>6</sup>Department of Obstetrics and Gynaecology, Atlantic Assisted Reproductive Therapies, Dresden Row, Halifax, Nova Scotia, Canada.

\***Corresponding Author:** Aloy Okechukwu Ugwu, Atlantic Assisted Reproductive Therapies, Dresden Row, Halifax, Nova Scotia, Canada.

**Received date:** December 03, 2024; **Accepted date:** December 10, 2024; **Published date:** December 17, 2024

**Citation:** Ayodeji K. Adefemi, Chidinma M. Nwogu, Omisakin S. Isaac, Aloy O. Ugwu, Adebayo Awoniyi, et al, (2024), Open Abdominal Metroplasty for The Treatment of Uterine Septum in A Woman with Uterine Factor Infertility- A Case Report, *J. Women Health Care and Issues*, 7(8); DOI:10.31579/2642-9756/229

**Copyright:** © 2024, Aloy Okechukwu Ugwu. This is an open access article distributed under the Creative Commons Attribution License, which permits unrestricted use, distribution, and reproduction in any medium, provided the original work is properly cited.

## Abstract

Anomalies of the Paramesonephric duct is a group of congenital malformations that occur either from the failure to complete bilateral Mullerian duct elongation, fusion, duct canalization, or resorption of the septum. Septate uterus is the commonest of these anomalies and is associated with adverse pregnancy outcomes especially miscarriages. Metroplasty has been associated with improved pregnancy outcomes with hysteroscopic resection been the preferred approach currently. Open abdominal metroplasty is a useful alternative in low resource set-up or where facilities for hysteroscopy is not readily available or not affordable. The need for this case report is to document the case of a complete uterine septum in a 31-year-old woman with three previous miscarriages who had open abdominal metroplasty and subsequent pregnancy with good outcome.

**Key words:** Uterine septum, Strassman metroplasty, spontaneous conception, live birth.

## Introduction

Mullerian duct anomalies (MUA) occur from malformations at any step of the Mullerian developmental process. They are seen in 5.5% of the unselected population, in 8% amongst infertile women, and in 13.3% of those with miscarriages.<sup>1</sup>

Septate uterus is the most common of the Mullerian duct anomalies. It has the worst prognosis and is associated with high incidence of miscarriage and habitual abortion.<sup>1, 2</sup>

The persistence of the partitioning from a defective fusion of paramesonephric ducts during embryogenesis is the basis for uterine septum. It is largely asymptomatic making the true prevalence difficult to ascertain.<sup>3</sup> Although there is not so much robust evidence to show the association between septate uterus and infertility and other reproductive outcomes. However, the plausible link may be that that uterine septum can lead to increased rates of spontaneous abortion, preterm labour, intrauterine growth restriction, abnormal placentation, malpresentation of the fetus, and caesarean section rate.<sup>4</sup>

Management of Uterine septum has undergone tremendous changes from conservative management to Jones or Tompkins open abdominal metroplasty and now hysteroscopic metroplasty which is regarded as the gold standard in the contemporary obstetrics.<sup>5</sup> However, in developing countries where there is paucity of hysteroscopic equipment and expertise, open abdominal metroplasty can still be of relevance to help alleviate the suffering of these women with infertility from septate uterus.

## Case Presentation

### Patient information

She was a 31-year-old woman with three previous miscarriages who presented to our facility for infertility evaluation. She has been married for three years. She attained menarche at 13 years. Her menstrual cycle had been regular with severe primary dysmenorrhea that will sometimes last up to 5 days. She was not using any hormonal or non-hormonal contraceptive method. There was no associated heavy menstrual bleeding, dyspareunia,

intermenstrual or post coital bleeding. She has had three consecutive miscarriages, each between gestational age of 7 to 9 weeks, two of which she had manual vacuum aspiration with no post abortal complications. Her last cervical smear was six months prior to presentation which was negative for intraepithelial neoplasia or malignancy. Her last menstrual period was two weeks prior to presentation.

**Clinical findings**

Her external genitalia were grossly normal looking with no obvious abnormality and no evidence of female genital mutilation. Her Blood pressure was 120/70mmHg, heart rate of 88 beats per minute, respiratory rate was 16 cycles per minute and oxygen saturation was 98% at room air. Other examination findings were unremarkable.

**Diagnostic approach**

Her hormone profile, blood sugar, thyroid function and antiphospholipid antibody screening were normal. Transvaginal ultrasound scan revealed two separate uterine cavities with a common cervix and septum almost close to the cervix and normal uterine fundus. Ovaries were radiologically normal. (Fig 1).

Hysterosalpingogram (HSG) also showed two uterine cavities with a common cervix and angle between the uterine horns was 65 degrees (less than 75°) suggestive of septate uterus.

She was counselled on further diagnostic options including an MRI, hysteroscopy and laparoscopy but she declined because of unavailability of

funds or insurance coverage. She was then consented for open abdominal surgery.

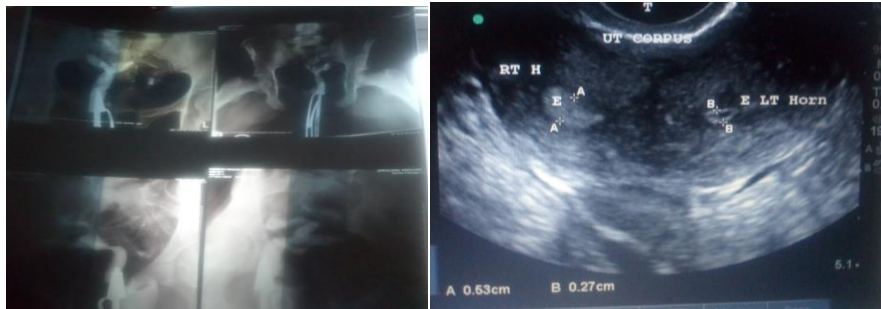**Surgical/Therapeutic intervention**

She had surgery during the follicular phase of her menstrual cycle. Following laparotomy, a single Antero fundal incision on the uterus was made and dissected sideways to access both halves of the endometrial cavities. Findings revealed a normal sized uterus with normal external contour, two uterine cavities smaller than usual separated by a thick septum just short of the cervix which was excised with both cavities unified and cervix probed and dilated to size 6 dilator to reduce stenosis from adhesion. Endometrium was closed with polyglactin 910 number 3/0 suture. The myometrium closed with polyglactin 910 number 2 and serosa closed with the continuous base-ball pattern with polyglactin 910 number 1 and anti-adhesion barrier applied ('Surgicel'). Fallopian tubes and ovaries were normal. A tight cervico-isthmic tourniquet made with a size 16 Foley catheter ensured negligible blood loss. An intrauterine Lippes loop (an intrauterine device without the copper) was inserted into the uterus to prevent adhesion.

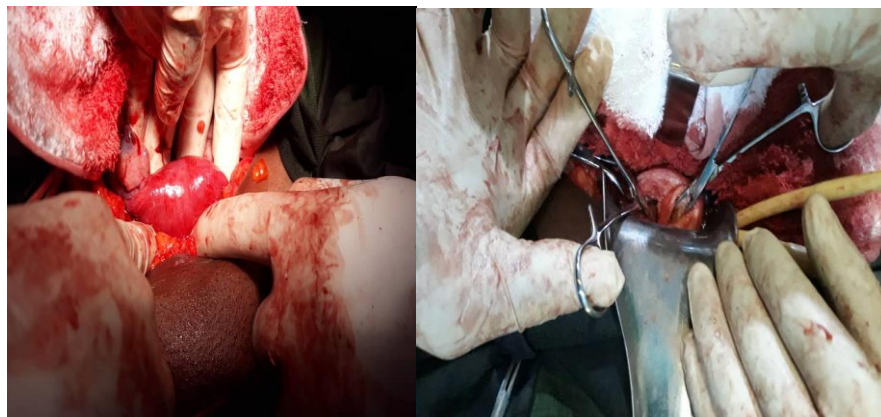
**Follow-up and outcome**

Post-operative care included oral antibiotic and analgesics. Her post-operative recovery was uneventful. She was discharged third post-operative day. Her menses returned three weeks post procedure. She subsequently missed her period on the 5th post operative month.

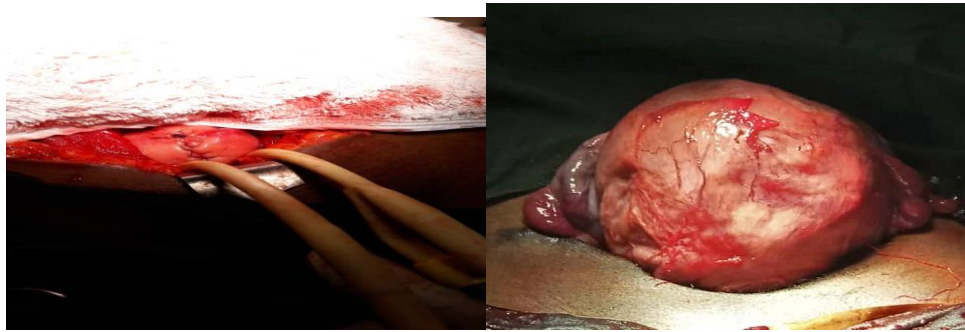
Ante-natal was uneventful except for heightened anxiety during the first trimester and third trimester. She had a male neonate following an elective caesarean section at 39 weeks.



**Figure 1 & 2;** Pre-operative HSG and Pre-operative transvaginal sonography respectively.



**Figure 3 and 4;** Images of external surface of uterus pre metroplasty and probes in both halves of endometrial cavity during open metroplasty respectively.



**Figure 5 & 6;** Images of Post metroplasty appearance of external surface of uterus and post caesarean section appearance of uterus respectively.

## Discussion

Septate uterus is the most common of all congenital uterine anomalies and Mullerian duct anomalies. The septal tissue is made of fibromuscular tissue with an endometrium with reduced sensitivity to pre-ovulatory hormonal changes and significantly reduced transmembrane vascular endothelial growth factor (VEGF) receptors than the normal uterine tissue.<sup>5, 6</sup> Infertility and dysmenorrhoea may be common.<sup>1</sup> A diagnosis of septate uterus alone is not an indication for surgery unless complicated with poor reproductive outcome.

2. Hysterosalpingography (HSG) which has over the years been used to screen for anatomic anomalies is limited by its inability to evaluate external uterine contour, and so cannot reliably differentiate between septate and bicornuate uterus or differentiate between an incomplete septum or an arcuate uterus from a bicornuate uterus.<sup>6</sup> Saline infusion sonohysterography (SIS) also serves a similar purpose without the danger of exposure to radiation.<sup>6</sup> Laparoscopy after HSG suspicion is usually needed to confirm the diagnosis.

Transvaginal sonography (TVS) has proven helpful in diagnosing septate uterus with a sensitivity of 100% and specificity of 80%.<sup>7</sup> Three-dimensional ultrasonography allows for planar reformatted sections through the uterus giving an accurate evaluation of the fundal and entire external contour with results similar to endoscopic evaluation.<sup>7</sup>

MRI allows for a non-invasive alternative approach of assessing both the internal and the external contour of the uterus and useful in virgins with suspicion of congenital uterine anomaly.<sup>8</sup> Although our patient had transvaginal ultrasound scan and HSG, she was financially constrained to do other investigations.

Hysteroscopic (transcervical) metroplasty with or without concurrent laparoscopy is the standard treatment of choice for septate uterus.<sup>9</sup> Open or abdominal metroplasty has given way with the advent of modern endoscopic instruments and techniques; however, an abdominal uterine septum resection can still be performed for septate uterus in a limited resource surgical setting achieving remarkable improved fetal survival rates post-surgery as was done for our patient.

## Conclusion

Metroplasty improves reproductive outcome associated with Mullerian anomalies. Hysteroscopic (transcervical) metroplasty has replaced abdominal metroplasty in patients with septate uterus by reducing morbidity but abdominal metroplasty is a useful alternative in developing nations with limited availability of minimal access surgical procedures.

## Acknowledgements

We are grateful to all the nurses, medical record staff, radiologists and theatre staff in our facility who contributed immensely to the patient care.

## Authors contributions

All authors contributed to the conception of the case report. Literature search and review were performed by OA, NM, AK, KO. The first draft of the case report was written by NM and critically reviewed by OA and AK. All authors commented and reviewed the final draft of the case report.

## Data availability

Not applicable for a case report.

## Ethical approval

Not applicable for a case report.

## Declaration of patient's consent to use their images/photos

The authors certify that they have obtained all appropriate patient consent forms. In the form, she has given her consent for her images/photographs and other clinical information to be reported in the journal. She understands that her name and initials will not be published, and due efforts will be made to conceal her identity.

## Declaration of Helsinki

Authors declare that the study was conducted in accordance with the ethical principles of the Helsinki Declaration.

## Financial support and sponsorship

Nil.

## Conflicts of interest

There are no conflicts of interest.

## Disclaimer (Artificial Intelligence)

We hereby declare that no generative AI technologies such as Large Language Models (ChatGPT, COPILOT, etc.) and text-to-image generators have been used during writing or editing of manuscripts.

## References:

1. Gulavi E, Kyende Mutiso S, Mariara Muriuki C, Mukaindo Mwaniki A. (2018). Successful Pregnancy Outcome after Open Strassman Metroplasty for Bicornuate Uterus. *Case Rep Obstet Gynecol*. May 31; 2018:4579736.
2. Nwogu CM, Adefemi AK, Ugwu AO, Odoh EU, Fadeyi DB, Adebayo A. (2024). "Reproductive Outcomes in Two Nigerian Women with Septate Uterus: A Case Series and Literature Review". *Asian Journal of Medical Principles and Clinical Practice* 7 (2):408-414.
3. Chang Y, Shen M, Wang S, Guo Z, Duan H. (2023). Reproductive outcomes and risk factors of women with septate uterus after hysteroscopic metroplasty. *Front Endocrinol (Lausanne)*.; 14:1063774. Published 2023 Jun 8.

4. Zhang B, Wu S, Zhao X, Tan L, Xu D. (2022). Treatment of septate uterus. *Zhong Nan Da Xue Xue Bao Yi Xue Ban*. Nov 28;47(11):1487-1494.
5. Blanco-Breindel MF, Kahn J, Singh M. Septate Uterus. [Updated 2023 Jul 15]. In: StatPearls [Internet]. Treasure Island (FL): StatPearls Publishing; 2024 Jan-.
6. Kumar K, Pajai S, Baidya GR, Majhi K. (2023). Utility of Saline Infusion Sonohysterography in Gynecology: A Review Article. *Cureus*. Feb 24;15(2): e35424.
7. Russo C, Conway F, Siciliano T, Selntigia A, Giuseppe Martire F, Soreca G, Ticconi C, Exacoustos C. (2022). 3D transvaginal ultrasound diagnosis of uterine septa according to different classifications: are there other measurements that correlate to reproductive outcome in small indentation length? *Facts Views Vis Obgyn*. Jun;14(2):129-138.
8. Jegannathan D, Indiran V. (2018). Magnetic resonance imaging of classified and unclassified Müllerian duct anomalies: Comparison of the American Society for Reproductive Medicine and the European Society of Human Reproduction and Embryology classifications. *SA J Radiol*. Apr 23;22(1):1259.
9. Carrera M, Pérez Millan F, Alcázar JL, et al. (2022). Effect of Hysteroscopic Metroplasty on Reproductive Outcomes in Women with Septate Uterus: Systematic Review and Meta-Analysis. *J Minim Invasive Gynecol* ;29(4):465-475.



This work is licensed under Creative Commons Attribution 4.0 License

To Submit Your Article Click Here:

[Submit Manuscript](#)

DOI:10.31579/2642-9756/229

#### Ready to submit your research? Choose Auctores and benefit from:

- fast, convenient online submission
- rigorous peer review by experienced research in your field
- rapid publication on acceptance
- authors retain copyrights
- unique DOI for all articles
- immediate, unrestricted online access

At Auctores, research is always in progress.

Learn more <https://www.auctoresonline.org/journals/women-health-care-and-issues>