

Combo Drugs Therapy Improves Restoration of Patency of Culprit Vessel in Acute ST-Elevation Myocardial Infarction – A case report of 3 patients

SKS Lairikyengbam ^{1*}, Ramdeo Yadave ², Arica Devi Mayanglambam ³

¹ Chief Cardiologist.

² Senior Consultant, Interventional Cardiologist.

³ Academic Executive. SKY Hospital & Research Centre Pvt. Ltd., India.

*Corresponding Author: SKS Lairikyengbam, SKY Hospital & Research Centre Pvt. Ltd., Imphal, India.

Received date: December 19, 2024; Accepted date: December 27, 2024; Published date: January 06, 2025

Citation: SKS Lairikyengbam, Ramdeo Yadave, Arica Devi Mayanglambam, (2025), Combo Drugs Therapy Improves Restoration of Patency of Culprit Vessel in Acute ST-Elevation Myocardial Infarction – A case report of 3 patients, *J Clinical Cardiology and Cardiovascular Interventions*, 8(1); DOI: [10.31579/2641-0419/436](https://doi.org/10.31579/2641-0419/436)

Copyright: © 2025, SKS Lairikyengbam. This is an open access article distributed under the Creative Commons Attribution License, which permits unrestricted use, distribution, and reproduction in any medium, provided the original work is properly cited.

Abstract

Acute ST-Elevation Myocardial Infarction (STEMI) usually results from an occlusive coronary thrombus at the site of a ruptured atherosclerotic plaque. Thrombolysis has a role in the management of patient with acute STEMI and restoration of culprit vessel arterial flow as normal as possible. Early thrombolytic therapy in acute STEMI reduced mortality by the time of hospital discharge and better functional outcomes at 6 months. Thrombolytic therapy when given within 10 minutes of arrival at the Emergency Room helped restore the patency of culprit vessel patency to 0-30% in our 3 patients with acute STEMI. This may indicate that thrombolytic therapy augmented with loading anti-platelet drugs and bolus intravenous drug enoxaparin given in ≤ 10 minutes may be a viable alternative to primary percutaneous coronary intervention when the later is not available or not possible within Door-to-Balloon time of 120 minutes.

Keywords: door to needle time; culprit vessel; acute myocardial infarction

Abbreviations Used:

STEMI- ST Elevation Myocardial Infarction;

LVEF- Left Ventricular Ejection Fraction;

CAG- Coronary Angiogram;

DTE- Door-to-ECG time;

DTD- Door-to-Diagnosis time;

DTB- Door-to-Balloon time;

DNT- Door-to-Needle time;

DAP- Dual Antiplatelet Therapy;

FMC- First Medical Contact;

LAD- Left Anterior Descending,

ER- Emergency Room,

CAD- Coronary Artery Disease

Introduction

Coronary artery disease (CAD) is a major cause of morbidity and mortality in India. Approximately, 8-10% of Indians in urban areas and 3-4% in rural areas have CAD [1-4]. Dedicated Heart Attack Treatment Centre (HAC) was established at SKY Hospital and Research Centre Pvt. Ltd., Imphal, India in July, 2016 providing 24x7 services, early ECG, loading dose of dual anti-platelet (DAP) drugs, timely administration of thrombolytic therapy for acute STEMI, and early patients transfer to ICCU. Bedside Echocardiogram is performed at the time of admission in ICCU. Our HAC Team consists of Consultant Cardiologist/middle grade Cardiologist on site, other Emergency Medical Officers and well trained nurses. International guidelines are clear in specifying that patients with acute STEMI should receive urgent Coronary reperfusion with either primary percutaneous coronary intervention (pPCI) or thrombolysis [5].

The pPCI is available to less than 10% of STEMI patients in India (CREATE registry) [6]. Consequently, local recommendation on STEMI management exists to promote timely administration of thrombolysis within 30 minutes of patient arrival [7, 8] and then within 10 minutes [9, 10]. Here we present 3 cases in which restoration of complete or near

complete patency of the culprit vessel was observed after treatment at HAC of our hospital.

Case 1

A 57 years old man with a history of smoking was admitted to the ER on November 19, 2021, by his family 1 hour 30 minutes after onset of chest pain and breathlessness. On examination, blood pressure was 150/110 mmHg; heart rate of 93 beats per minute. He was resuscitated immediately and intensively. An ECG was obtained on admission which revealed acute extensive antero-lateral STEMI, Figure.1(a). Serum Troponin T was found raised at 2000 ng/L (normal value < 40 ng/L). Loading Double Antiplatelet Drugs, Tab. Ecosprin, 300 mg and Tab.

Ticagrelor, 180 mg were administered. Immediate thrombolytic therapy with inj. Reteplase 18 mg in 2 minutes as first dose followed by 18 mg after 30 minutes. Inj. Enoxaparin 30 mg was given intravenously within 10 minutes of the patient's arrival at ER (Table 1). An Echocardiogram examination revealed akinetic apex involving 25% of left ventricle, dilated left ventricle with reduced LVEF (47.94%), mild mitral regurgitation, mild left ventricular hypertrophy, minimal tricuspid regurgitation, no Pulmonary Arterial Hypertension (PAH), mild pulmonary regurgitation, normal pericardium. Further investigation revealed that he had dyslipidaemia.

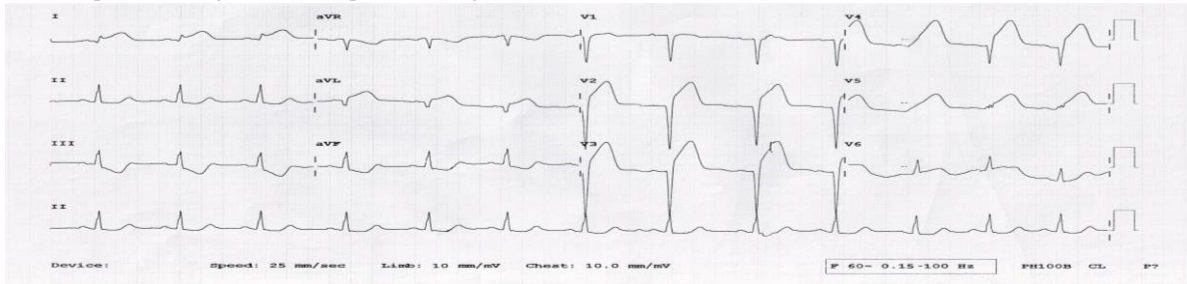


Figure:1(a): ECG on admission

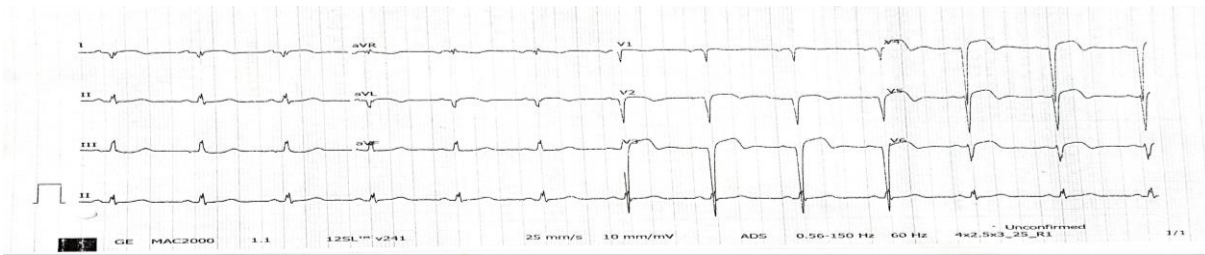
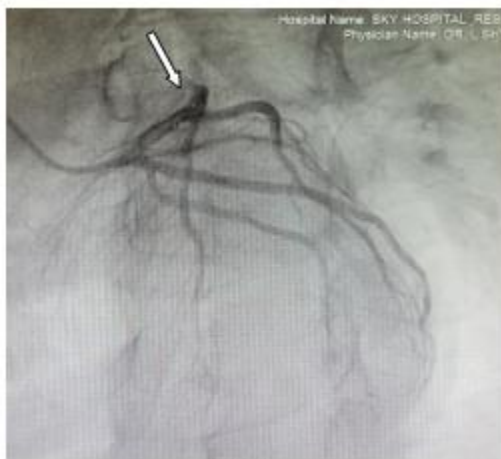

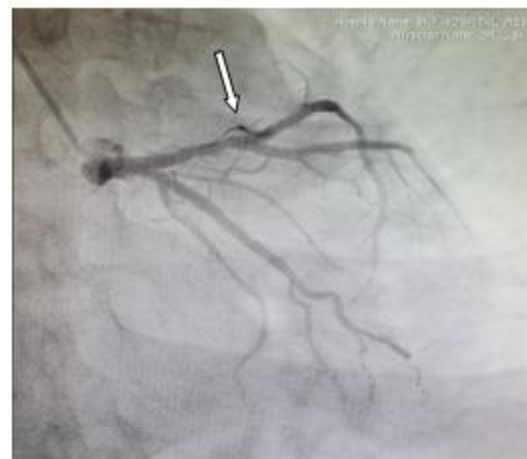Figure:1(b): ECG post thrombolysis

Post-Thrombolytic therapy coronary angiogram revealed recanalised proximal LAD with only 30% residual stenosis Figure:1(c): Patient's

condition improved and was stable at the time of discharge on November 29, 2021.



LAO



RAO

Figure:1(c): Case 1 patient's CAG photos showing recanalised proximal LAD with 30 % residual stenosis only.

Case 2

A 46 years old man with a history of hypertension, CVA (ischaemic, 2020 with left Grade 4 hemiparesis), smoking, history of Covid-19 (2020) was admitted to the ER on November 12, 2023, by his family with chief complaints of chest pain and breathlessness. On examination, blood

pressure was 180/110 mmHg; heart rate of 90 beats/min. An ECG was obtained on admission which revealed acute extensive antero-lateral STEMI, Fig.2(a). Serum Troponin T was found raised at 668 ng/L (normal value < 40 ng/L). Immediate treatment started to resuscitate the patient. Intravenous Glyceryl trinitrate infusion was started to control the accelerated hypertension which was gradually weaned off. Loading

Double Antiplatelet Drugs, Tab. Ecosprin, 300 mg and Tab. Ticagrelor, 180 mg were administered. Immediate thrombolytic therapy with inj. Tenecteplase 35 mg was given over 2 seconds. Inj. Enoxaparin, 30 mg was given intravenously within 10 minutes of the patient’s arrival at ER (Table 1). An Echocardiogram examination revealed apical akinesia involving 25% of left ventricle, dilated left ventricle with moderate left

ventricular systolic dysfunction (LVEF=43.5%), mild left ventricular hypertrophy, mild left ventricular diastolic dysfunction, mild mitral regurgitation, minimal tricuspid regurgitation, no PAH (PASP = 17.0 mmHg), intact interatrial septum and interventricular septum and minimal pericardial effusion. On further investigation, he was found to suffer from Type II Diabetes Mellitus.

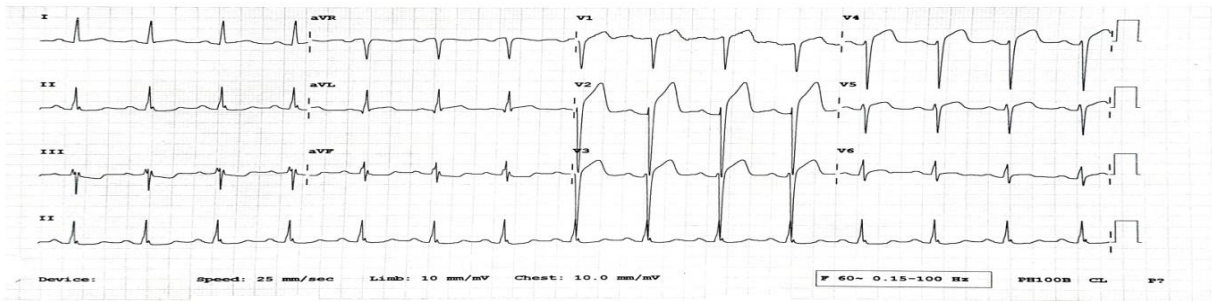


Figure:2(a): ECG on admission.

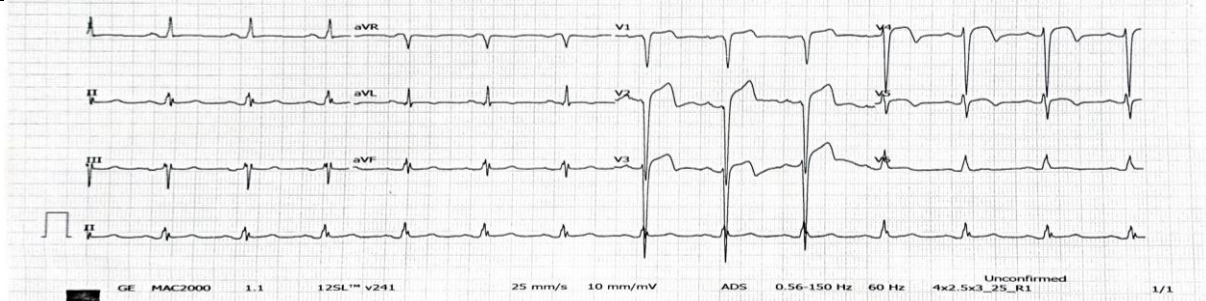


Figure:2(b): ECG post thrombolysis

Post-Thrombolytic therapy coronary angiogram revealed recanalised LAD with 30 % residual stenosis Figure:2(c). Patient was stable at the time of discharge on November 24, 2023.

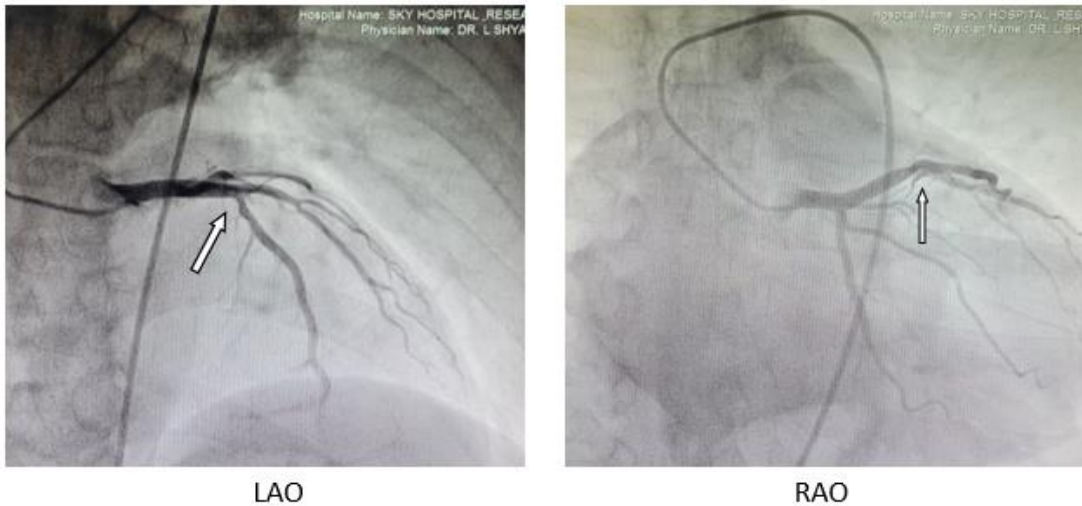


Figure: 2(c): Case 2 patient’s CAG photos showing CAD with recanalised LAD with 30 % residual stenosis only.

Case 3

A 50 years old woman was admitted to the ER on April 6, 2024 transferred from another hospital with acute anterior wall STEMI and hypoxia. On examination, blood pressure was 110/70 mmHg; heart rate of 58beats/min. She was resuscitated immediately. On admission, ECG revealed Acute extensive antero-lateral STEMI, Figure.3(a). Serum

Troponin T was found raised at 264 ng/L (normal value < 40 ng/L). Loading Double Antiplatelet Drugs, Tab. Ecosprin, 300 mg and Tab.

Ticagrelor, 180 mg were administered. Immediate thrombolytic therapy with inj. Tenecteplase 35 mg was administered over 2 sec. Inj. Enoxaparin, 30 mg was given intravenously within 10 minutes of the patients arrival at ER (Table 1). An Echocardiogram examination revealed akinetic left ventricular apex involving 1/3rd of left ventricle, dilated left ventricle with reduced LVEF (51.6%), mild mitral regurgitation, moderate tricuspid regurgitation and mild PAH (PASP=38.2 mmHg).

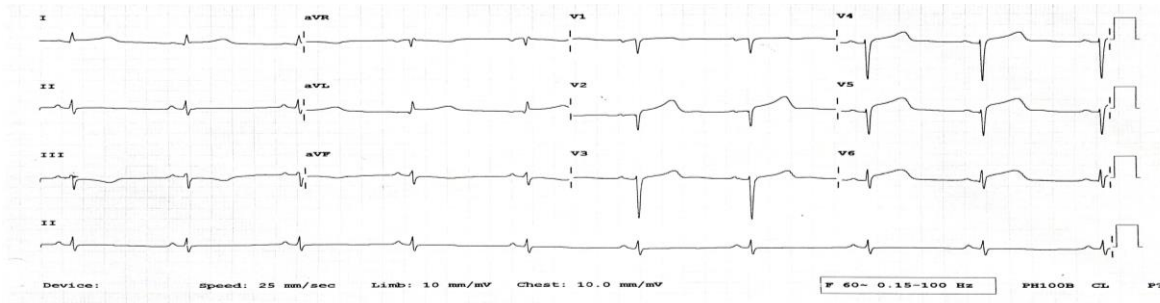


Figure:3(a): ECG on admission.

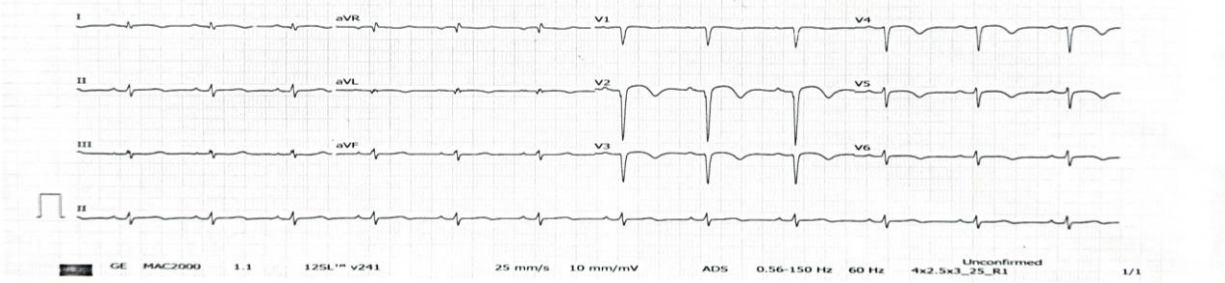
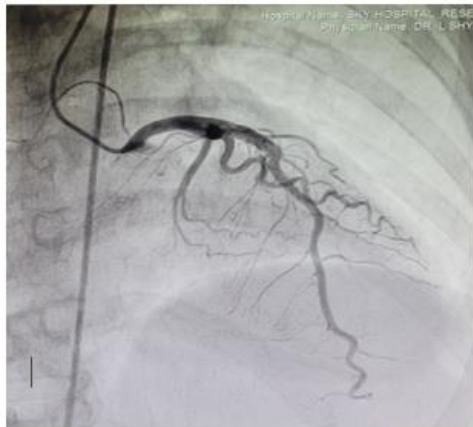
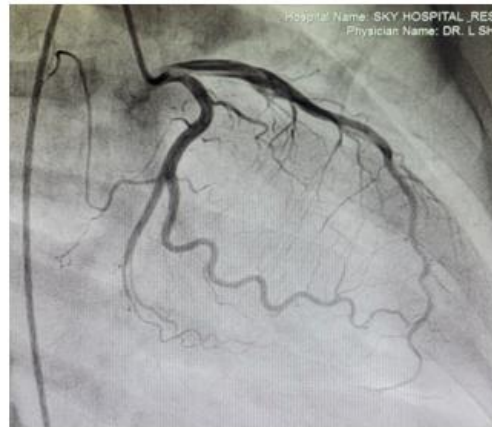


Figure:3(b): ECG post thrombolysis.

Post-Thrombolytic therapy coronary angiogram revealed fully recanalised the LAD Figure:3(c). Patient’s condition improved. She was mobilized and stable at the time of discharge on April 18, 2024.



LAO



RAO

Figure:3(c): Case 3 patient’s CAG photos showing fully recanalised LAD.

Characteristics	Case 1	Case 2	Case 3
Demographic characteristics			
Age (years)	57	46	50
Sex	Male	Male	Female
Medical history	Dyslipidaemia	<ul style="list-style-type: none"> ▪ Dyslipidaemia ▪ Hypertension ▪ Cerebrovascular Accident ▪ Type II Diabetes Mellitus 	<ul style="list-style-type: none"> ▪ Dyslipidaemia ▪ Impaired Glucose Tolerance
Clinical Characteristics			
Chief Complaints	Chest pain Shortness of Breath on exertion	Chest pain Breathlessness	Chest pain
DTE	2 minutes	1 minute	2 minutes
DTD	3 minutes	3 minutes	3 minutes
Loading dose of DAP	5 minutes	4 minutes	4 minutes
DNT	10 minutes	10 minutes	5 minutes

Post-Thrombolysis CAG	Recanalised proximal LAD with 30% residual stenosis	Recanalised proximal LAD with 30% residual stenosis	Fully recanalised the LAD
LVEF at the time of admission	47.9%	43.5%	51.6%
LVEF at 7days post discharge	49.2%	44.4%	52.5%
Days of hospital stay	10	12	12
Activities- Walk independently without symptoms (Telephone follow up post-thrombolysis on 13-11-2024)	1 kilometer	500 meters	400 meters
Health status post-thrombolysis	Asymptomatic	Asymptomatic	Asymptomatic

Table 1: Demographic, clinical characteristics and laboratory findings at the time of the thrombotic event.

Results:

Of the 3 patients, 2 were males and 1 was female. The age groups range from 46 years to 57 years. All patients received intravenous thrombolysis between the 10 minutes of presentation at ER. CAG shows that revascularization was successful in 100% of cases and good clinical outcomes were achieved. Early administration of thrombolytic therapy in acute STEMI reduced mortality by the time of hospital discharge and better functional outcomes at 6 months.

Discussion:

Any model of acute STEMI care in India should have the principal objectives of improving the speed of reperfusion, and reducing the time from symptom onset to treatment [11]. These can be achieved by ensuring a quick response time (QRT) to perform an ECG at the point of FMC, a prompt initiation of bolus DAP drugs, thrombolytic therapy and intravenous Enoxaparin or other approved anticoagulants. Reperfusion therapy is also recommended in acute STEMI patients with evidence of ongoing ischemia within 12–24 hrs of symptom onset [12].

For our case, all received loading DAP drugs, bolus intravenous anticoagulants and third generation thrombolytic agent within 10 minutes of diagnosis of acute STEMI. Post lysis CAG for all patients showed normal or near normal restoration of patency of culprit arteries.

Conclusion:

Thrombolytic therapy along with loading dose of DAP and bolus Enoxaparin, all given within 10 minutes of diagnosis of acute STEMI may be a viable alternative to primary percutaneous coronary intervention when the later is not available or not possible within DTB of 120 minutes [10, 13]. Larger randomized controlled trials will be necessary to substantiate our finding.

References:

- Rawles JM. (1997). Quantification of the benefit of earlier thrombolytic therapy: Five year results of the Grampian Region Early Anistreptase Trial (GREAT). *J Am Coll Cardiol.*; 119-177.
- Negi PC, Merwaha R, Panday D, Chauhan V, Guleri R. (2016). Multicenter HP ACS registry. *Indian Heart J.*; 68: 118-127.
- Kumar S, Gurpreet SW, Singh B, Kansal M, Mohan B, Aslam M et al. (2019). Evaluation of intracoronary blood from obstructive vessel in patients of ST-elevation myocardial infarction undergoing PPCI. *Indian Heart J.*: 71.
- Srinath Reddy K, Shah B, Varghese C, Ramadoss (2005). A. Responding to the threat of chronic diseases in India. *Lancet.*; 366: 1744-1749.
- Mark Jordan, Jenny Caesar. (2020). Improving door-to-needle times for patients presenting with ST-elevation myocardial infarction at a rural district general hospital. *J Am College of Cardiol.*; 5: 1.
- Xavier D, Pais P, Devereaux PJ, Xie C. (2008). Treatment and outcomes of acute coronary syndromes in India (CREATE): a prospective analysis of registry data. *Lancet.*; 371: 1435-1442.
- Anderson JL, Karagounis LA, Califf RM. Meta-analysis of five reported studies on the relation of early coronary patency grades with mortality and outcomes after acute myocardial infarction. *Am J Cardiol.* 1996; 78: 1.
- O'Gara PT, Kushner FG, Ascheim DD, Casey DE Jr, Chung MK et al. (2013). American College of Cardiology Foundation/American Heart Association Task Force on Practice Guidelines. 2013 ACCF/AHA guideline for the management of ST-elevation myocardial infarction: a report of the American College of Cardiology Foundation/American Heart Association Task Force on Practice Guidelines. *Circulation* Jan 29;127(4):e362 -425.
- Borja Ibanez, Stefan James. (2017). The ESC STEMI Guidelines. *Eur. Heart J.* 2018 Jan; 39(2):79–82.
- Robert A Byrne, Xavier Rossello, J J Coughlan, Emanuele Barbato, et al. (2023). ESC Guidelines for the management of acute coronary syndromes: Developed by the task force on the management of acute coronary syndromes of the European Society of Cardiology (ESC). *Eur. Heart J.* Oct;44(38):3720–3826.
- Karthikeyan G, Mantoo MR, Bhargava B. (2022). Choosing the right model for STEMI care in India - Focus should remain on providing timely fibrinolytic therapy, for now. *Indian J Med Res.* Jul;156(1):17-20.
- Mizuguchi Y, Shibutani H, Hashimoto S, Yamada T, Taniguchi N, Nakajima S, Hata T, Takahashi (2018). A. Examination of the appropriate timing of reperfusion therapy for recent myocardial infarction: a Japanese single-center retrospective study. *Indian Heart J.* Jan-Feb;70(1):4-9.
- Lawton JS, Tamis-Holland JE, Bangalore S, Bates ER, Beckie TM, Bischoff JM, Bittl JA, Cohen MG et al. (2022). ACC/AHA/SCAI Guideline for Coronary Artery Revascularization: A Report of the American College of Cardiology/American Heart Association Joint Committee on Clinical Practice Guidelines. *Circulation.* Jan 18;145(3):e18-e114.



This work is licensed under Creative Commons Attribution 4.0 License

To Submit Your Article Click Here: [Submit Manuscript](#)

DOI:[10.31579/2641-0419/436](https://doi.org/10.31579/2641-0419/436)

Ready to submit your research? Choose Auctores and benefit from:

- fast, convenient online submission
- rigorous peer review by experienced research in your field
- rapid publication on acceptance
- authors retain copyrights
- unique DOI for all articles
- immediate, unrestricted online access

At Auctores, research is always in progress.

Learn more <https://auctoresonline.org/journals/clinical-cardiology-and-cardiovascular-interventions>