

# Mediastinal Teratoma with Pyothorax and Axillary Fistula: A Case Report

M. Rhaouti <sup>1\*</sup>, F. Lamouime <sup>1</sup>, I. Arramach <sup>1</sup>, M. Lakranbi <sup>1,2</sup>, Y. Ouadnoui <sup>1,2</sup>, M. Smahi <sup>1,2</sup>

<sup>1</sup>Department of Thoracic Surgery, Fes university hospital

<sup>2</sup>Sidi Mohammed Ben Abdellah university, Faculty of Medicine and Pharmacy of Fes

\*Corresponding Author: M. Rhaouti, Department of Thoracic Surgery, Fes university hospital.

Received date: **January 01, 2024**; Accepted date: **January 15, 2024**; Published date: **January 24, 2024**

**Citation:** M. Rhaouti, F. Lamouime, I. Arramach, M. Lakranbi, Y. Ouadnoui, et al, (2024), "Copper" Coins as an Anti-Inflammatory agent, *J Thoracic Disease and Cardiothoracic Surgery*, 5(5); DOI:[10.31579/2693-2156/084](https://doi.org/10.31579/2693-2156/084)

**Copyright:** © 2024, M. Rhaouti. This is an open access article distributed under the Creative Commons Attribution License, which permits unrestricted use, distribution, and reproduction in any medium, provided the original work is properly cited.

## Abstract

Mediastinal teratomas are rare and complex tumours that derive from germ cells. They represent a unique diagnostic and therapeutic challenge. We report the case of a 29-year-old pregnant woman who was diagnosed with a mature mediastinal teratoma that was complicated by left pyothorax and axillary fistula.

The article explores the diagnostic, clinical, and surgical characteristics of this case.

**Keywords:** diagnostic; clinical; left pyothorax

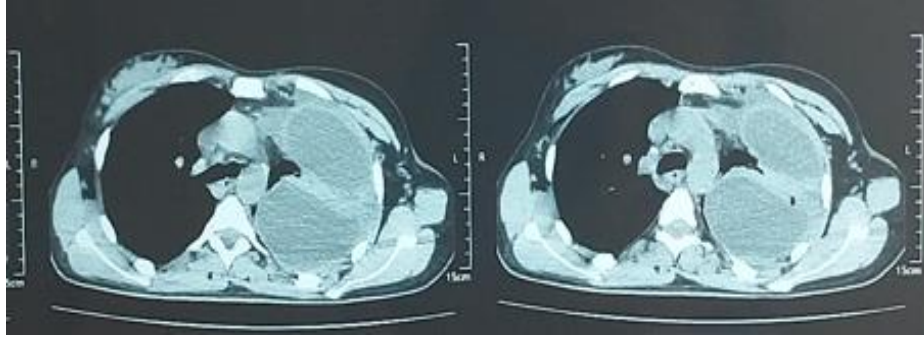
## Introduction

Mature teratomas are neoplasms characterized by the presence of well-differentiated cells derived from the three types of embryonic tissue: ectoderm, mesoderm, and endoderm. They are the most frequent among primitive germ cell tumours of the mediastinum. Although teratomas can occur in various locations in the body, their presence in the mediastinum is of particular interest due to the proximity of these tumours to vital anatomical structures such as the heart, large blood vessels, and lungs. These anatomical considerations add substantial complexity to the management of these mediastinal teratomas.

Up to 36% of all mediastinal teratomas are complicated by rupture, which is a significant and serious outcome. Teratomas most commonly rupture into the lungs and bronchi but also into the pleura, pericardium, and large vessels [1].

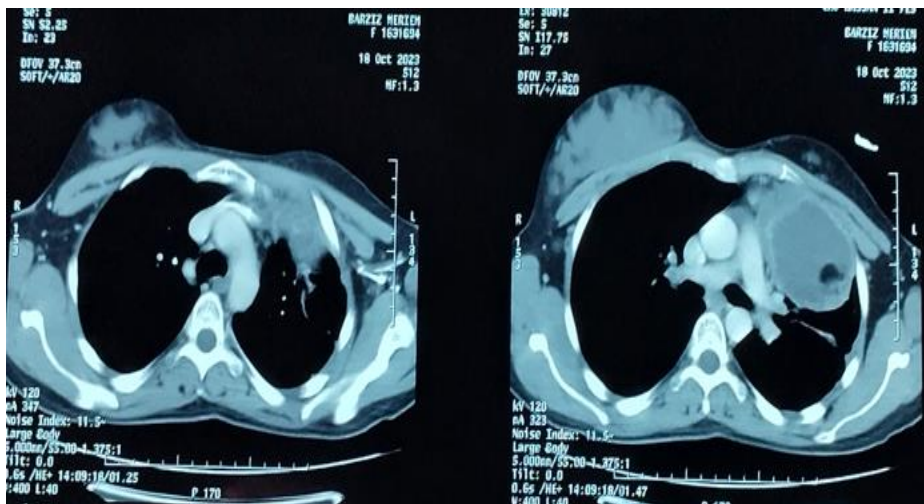
## Case report:

Our patient is a 29-year-old woman in her 22nd week of gestation. She had a right pyothorax for which a thoracic tube was inserted. The patient also benefited from antibiotic therapy, leading to significant clinical improvement (Figure 1).



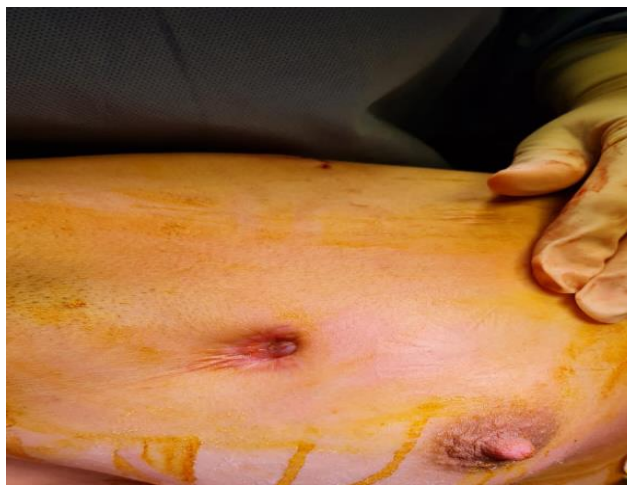**Figure 1:** Thoracic CT scan showing two left pulmonary collections.

The patient underwent a follow-up thoracic CT scan after delivery and after the removal of the chest tube. It revealed a left anterosuperior mediastinal lesion measuring 85mm, and composed of fleshy, fatty and cystic tissue without calcification. The lesion is highly evocative of a mature teratoma. The lesion was in contact with the pulmonary artery trunk and cardiac cavities (Figure 2).



**Figure 2:** Mature teratoma in contact with the pulmonary artery trunk and cardiac cavities.

Physical examination noted the presence of a left axillary fistula (Figure 3) with pus discharge.



**Figure 3:** Axillary fistula.

The case was discussed in a multidisciplinary consultation meeting, and surgery was deemed the appropriate course of treatment. The

patient underwent an almost complete excision of the lesion. We left parts of the tumour around the innominate vein trunk, and we marked them with clips.

Pathological examination revealed a mature teratoma with many small acini resembling pancreatic tissue. There was extensive tissue remodelling due to inflammation with areas of suppuration.

### Discussion:

Mediastinal teratomas are rare and complex tumours posing a unique diagnostic and therapeutic challenge. Radiology, particularly computed tomography (CT), plays a fundamental role in diagnosing mediastinal teratomas. Many imaging features are often indicative of this diagnosis, such as the presence of cystic, fleshy, fatty, and calcified tissue.

The teratoma in our case was ruptured, resulting in a pleural pus pocket, requiring careful scrutiny of the CT images to distinguish the pyothorax from the tumour.

Several hypotheses have been proposed to explain the tendency that mediastinal teratomas have for rupture [1]. Tumour components, such as pancreatic, salivary gland, or intestinal tissue, can release digestive enzymes and induce inflammation. The presence of pancreatic tissue is common in benign mediastinal teratomas which explain their increased tendency for rupture compared with other types of teratomas [2].

Sebaceous gland secretion in cyst tissue can also cause inflammation. Sebaceous secretions induce macrophagic response and the formation of foreign bodies inside the tumour capsule, a phenomenon well-documented in ruptured epidermoid cysts [3]. Another hypothesis suggests that rupture can result from the rapid growth of the tumour, resulting in decreased blood supply, ischemic changes and necrosis [2]. Infection is also considered a rupture factor through the weakening of the tumour wall. However, most teratoma ruptures are spontaneous [4].

This unusual presentation added additional challenges in terms of management, requiring a multidisciplinary approach to address both the pyothorax and the mediastinal tumour. Surgery is generally the cornerstone of managing mediastinal teratomas. However, specific considerations must be taken into account, especially when the tumour is in contact with vital structures such as the innominate vein trunk. In such cases, it may be necessary to leave part of the tumour in place to avoid damaging these important vessels and prevent potential postoperative complications [5].

In our case, surgery was rendered difficult due to the presence of adhesions (scar tissue) bridging the tumour with neighbouring anatomical structures. Adhesions are the result of the pyothorax and they made the dissection and excision of mediastinal tumours particularly complex. They increase the risk of perioperative complications and influence the surgeon's decision on how to proceed.

The combination of surgery and radiotherapy may also be considered to ensure complete eradication of the tumour and minimize the risk of recurrence. This approach can be particularly relevant when adhesions limit the ability to safely perform total resection. Radiotherapy can also be used to treat areas where the tumour is in contact with critical anatomical structures [6].

### Conclusion:

The surgical management of mediastinal teratomas requires meticulous planning and a multidisciplinary approach, especially when involving adhesions, and when the lesions are in proximity of vital anatomical structures. The goal is to ensure complete and safe tumour excision while minimizing the risk of complications.

### References

1. Sasaka K., Kurihara Y., Nakajima Y., et. al.: Spontaneous rupture: a complication of benign mature teratomas of the mediastinum. *AJR Am J Roentgenol* 1998; 170: pp. 323-328.
2. ommerland B.C., Cleland W.P., Yong N.K.: Physiological activity in mediastinal teratoma. *Thorax* 1975; 30: pp. 510-514.
3. Marston J.L., Cooper A.G., Ankeney J.L.: Acute cardiac tamponade due to rupture of a benign mediastinal teratoma into the pericardial sac. *J Thorac Cardiovasc Surg* 1966; 51: pp. 700-706.
4. Matsubara K., Aoki M., Okumura N., et. al.: Spontaneous rupture of mediastinal cystic teratoma into the pleural cavity: report of two cases and review of the literature. *Pediatr Hematol Oncol* 2001; 18: pp. 221-227.
5. Patel P, Ibrahim A, Zhang J, Nguyen J, Lin S, Lee B. Accessory Breast Tissue. [www.ePlasty.com](http://www.ePlasty.com), Interesting Case, 2012.
6. Madej B, Balak B, Winkler I, et al. Cancer of the accessory breast—a case report. *Adv Med Sci.* 2009; 54:308-10.



This work is licensed under Creative Commons Attribution 4.0 License

To Submit Your Article Click Here: [Submit Manuscript](#)

DOI: [10.31579/2693-2156/084](https://doi.org/10.31579/2693-2156/084)

**Ready to submit your research? Choose Auctores and benefit from:**

- ❖ fast, convenient online submission
- ❖ rigorous peer review by experienced research in your field
- ❖ rapid publication on acceptance
- ❖ authors retain copyrights
- ❖ unique DOI for all articles
- ❖ immediate, unrestricted online access

At Auctores, research is always in progress.

Learn more <http://www.auctoresonline.org/journals/journal-of-thoracic-disease-and-cardiothoracic-surgery>