

# Comparative, Prospective, Randomized, and Blind Study on the Incidence of Ecchymosis in Postoperative Varicose Vein Surgery with and without Prior Local Tumescence

Vinícius Bertoldi, Ana Luíza Maneira, Rafael de Athayde Soares \*, Soo Lim, André Passalacqua, Manoel Augusto dos Santos Filho, Walter Campos

Rafael de Athayde Soares, Barão de Jaceguai Street, 908, Campo Belo, São Paulo, SP, Brazil.

\*Corresponding Author: Rafael de Athayde Soares, Barão de Jaceguai Street, 908, Campo Belo, São Paulo, SP, Brazil.

Received date: **May 30, 2024**; Accepted date: **August 08, 2024**; Published date: **August 26, 2024**

**Citation:** Vinícius Bertoldi, Ana Luíza Maneira, Rafael de Athayde Soares, Soo Lim, André Passalacqua, et al, (2024), Comparative, Prospective, Randomized, and Blind Study on the Incidence of Ecchymosis in Postoperative Varicose Vein Surgery with and without Prior Local Tumescence, *J Clinical Cardiology and Cardiovascular Interventions*, 7(9); DOI: [10.31579/2641-0419/376](https://doi.org/10.31579/2641-0419/376)

**Copyright:** © 2024, Rafael de Athayde Soares. This is an open access article distributed under the Creative Commons Attribution License, which permits unrestricted use, distribution, and reproduction in any medium, provided the original work is properly cited.

## Abstract

**Objective:** To evaluate if the previous tumescence of the adrenaline solution changes the incidence and intensity of bruising as a complication of surgical treatment of varicose veins.

**Method:** A comparative, blind, prospective, randomized study was conducted at 14 patients whose lower limbs were divided into anterior, posterior and lateral areas.

**Results:** Out of the 40 studied areas, 30% had a higher incidence of ecchymosis in the limb where the previous tumescence was performed, and 20% had a lower incidence and among the areas where tumescence was performed, 55% (11) had ecchymoses considered mild, 40% (8) had moderate ecchymoses, and 5% (1) had severe ecchymosis. In areas where the previous tumescence was not performed, the results were similar, 60% (12) mild, 40% (8) moderate, and 0% (none).

**Conclusion:** The tumescent solution performed before the varicose vein surgery did not prevent or reduce the intensity of ecchymosis.

**Keywords:** varicose veins; surgery; tumescence; ecchymosis; hematoma

## Introduction

Chronic Venous Disease (CVD) is a common condition in the global adult population. It is estimated that 40% of the population suffers from CVD, and 60% to 70% have some degree of CVD according to the CEAP classification<sup>1</sup>.

The diagnosis of CVD is primarily clinical, considering patient complaints and the duration of symptoms, coupled with a physical examination focused on the lower limbs. Anamnesis often reveals symptoms such as leg fatigue, cramps, a sensation of heaviness and burning, and edema that worsens throughout the day. They become more evident in periods of heat and after prolonged periods in orthostasis and they may or may not be associated with itching. Through ectoscopy, it is possible to identify trophic alterations in the skin, telangiectasias, reticular or varicose veins, and the presence of healed or active stasis ulcers. During the physical examination, it is mandatory for the patient to be evaluated in an upright position, preferably maintaining this position for a few minutes, to make varicose veins more evident. 2,3

Clinical appearance is the most commonly used factor in the classification of chronic venous insufficiency, known as CEAP. It is divided based on the severity of the physical examination presentation of the lower limb into six stages as previously described in literature.<sup>4</sup> It is important to note that, although quite useful, the CEAP classification does not consider symptoms and/or the impact of venous disease on patients' quality of life.

Varicose vein surgery is performed for the treatment of symptomatic superficial tributaries or those with significant aesthetic compromise. The surgery involves the mechanical extraction of the vessel through micro-incisions in the skin using a needle or blade. The procedure may or may not be preceded by local tumescence with a diluted solution of adrenaline at a ratio of 1:100,000. Tumescence, previously widely used in plastic surgery procedures such as liposuction and facelifts,<sup>5,6</sup> was first described in vascular treatment by Cohn et al. in 1995.<sup>7</sup> The procedure involves the serial

infiltration of the solution into the perivascular region, guided or not by ultrasound. The solution causes vasoconstriction to reduce blood extravasation into the subcutaneous tissue during vessel extraction, as well as hemostasis of the stumps through mechanical compression. Tumescence separates the vessel from adjacent structures to decrease inadvertent injuries, and if well-executed, brings the vessel closer to the skin to facilitate avulsion. Adverse effects exclusive to infiltration are rare and are more commonly related to inadvertent intravenous administration or association with local anesthetic overdose.<sup>8</sup> Therefore, the main objective of this paper was to evaluate if the previous tumescence of the adrenaline solution changes the incidence and intensity of bruising as a complication of surgical treatment of varicose veins.

## Materials and Methods

A comparative, prospective, randomized, and blinded study was conducted aiming to compare the results obtained in the surgical extraction of varicose veins with and without prior local tumescence. The study focused on the occurrence and intensity of postoperative ecchymosis, as well as the evaluation of other potential complications such as local ischemia, ulceration, and edema.

Fourteen patients were selected during the years 2019 and 2020 who presented lower limb venous disease, CEAP C2 and C3, and were candidates for surgical treatment of varicose veins without involvement of the saphenous veins. The inclusion criteria were age 18 or older, BMI < 40, and no severe comorbidities. The study commenced after obtaining approval from the Research Ethics Committee.

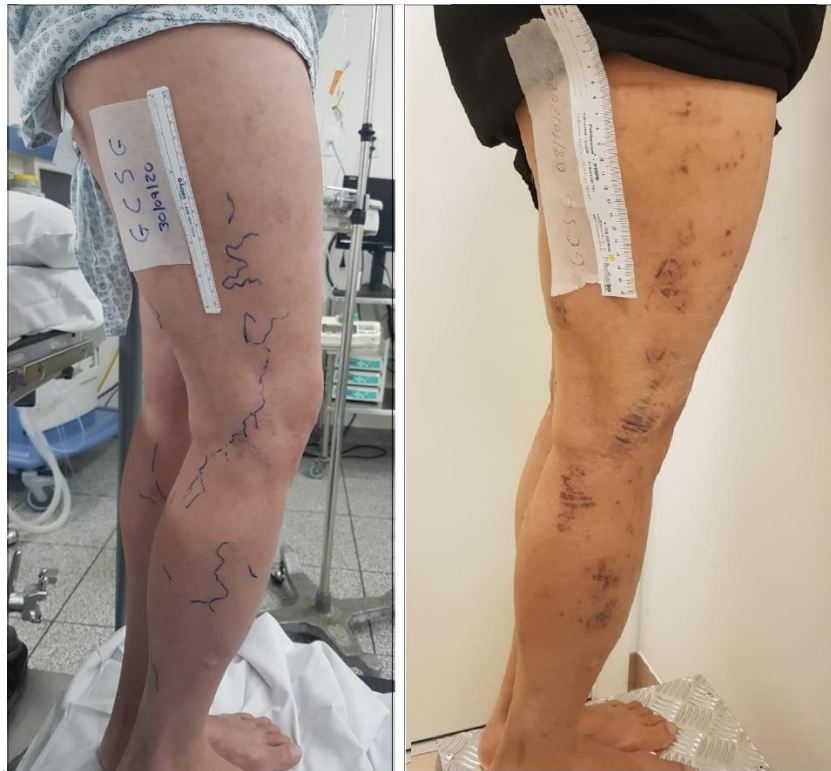The participants were identified through initials and coded for confidentiality. Patients were informed about the proposed procedure, potential complications, and the study's objective, and they were invited to sign the informed consent form. Following this, physical examinations, vital sign assessments, and evaluation of family history were conducted by the investigating physician. Subsequently, the clinical assessment was performed using the Aberdeen questionnaire. The Aberdeen Varicose Veins Questionnaire (AVVQ). It is an easily administered instrument, even self-applicable, addressing the physical, socio-functional, and psychological aspects of the patient.<sup>9</sup>

After an approximately 7-day period (+/- 2 days), the patients returned to the research center for the proposed procedure. A standardized photographic record of the patient was then taken by the vascular surgeon. Each affected area was photographed separately in the anterior, lateral, and posterior views of both limbs, totaling 84 photographs at this stage.

## Standardization of Photo Recording and Evaluation

Photo records were taken with a single camera following the same parameters: 60 cm distance at 50 cm above the ground, without flash, with artificial lighting (ceiling light), and without zoom. All generated images were saved in JPEG format, downloaded within 5 days after recording, and stored in a protected virtual platform.

All images were encoded as follows: participant code in the study + Date of photo recording (00/00/0000), visible in each record. A ruler was left visible in each record for software calibration.



Analyzed Areas: Anterior, Lateral, and Posterior of Both Limbs. Each area was identified in the study by code as follows: Anterior = 1, Lateral = 2, Posterior = 3 Image 1: Example - Preoperative control photograph (left). Control photograph of bruising on the 7th postoperative day (right).

Preoperative and postoperative care was conducted identically for all participants. Patients were required to fast for 8 hours before the surgery.

The procedures were performed in the operating room under anesthesia, at the discretion of the anesthesiologist after case analysis. The anesthesia method could include spinal anesthesia with sedation or general anesthesia.

Each patient underwent the surgical procedure on both lower limbs. However, prior local tumescence was performed on one of the limbs, chosen through simple randomization. Therefore, each patient participated in both study groups, acting as their own control.

#### Surgical Technique for Varicose Vein Extraction

##### Infiltration

- Preparation of the solution with 1000ml of saline solution + 1ml adrenaline (1mg/ml)
- Infiltration of the solution with a fine needle adjacent to the varicose vessels

##### Surgical Technique:

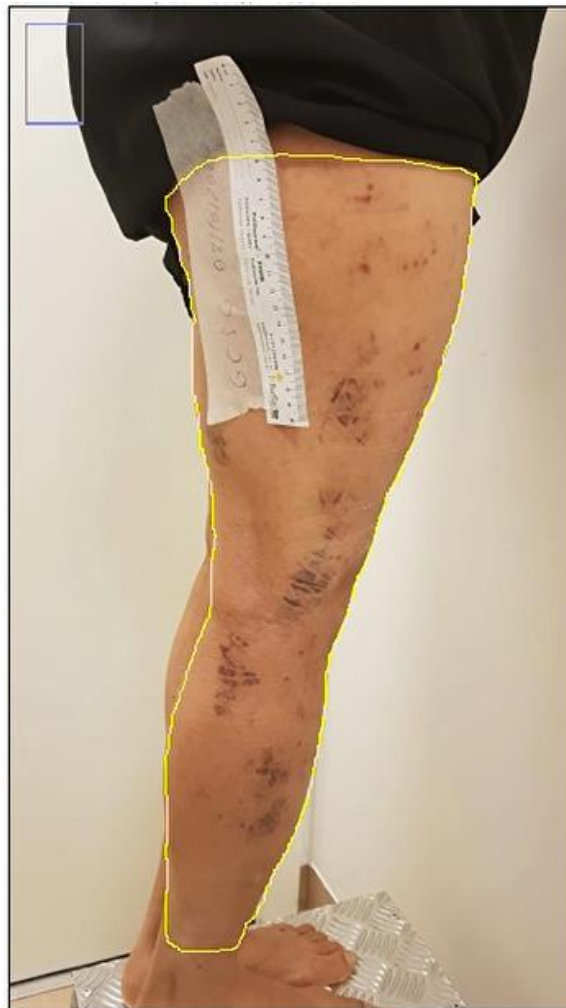- Marking of varicose veins with the aid of a portable phleboscope
- Aseptic technique, placement of sterile drapes
- Gradual micro-incisions adjacent to varicose vessels

- Excision of collateral varicose veins with a crochet needle
- Compressive bandaging


After the procedure, the patient was kept under hospital observation for 1 day. During this period, clinical evaluation, physical examination, and withdrawal criteria analysis were conducted. Any deviation from the normal pattern was documented in the medical records.

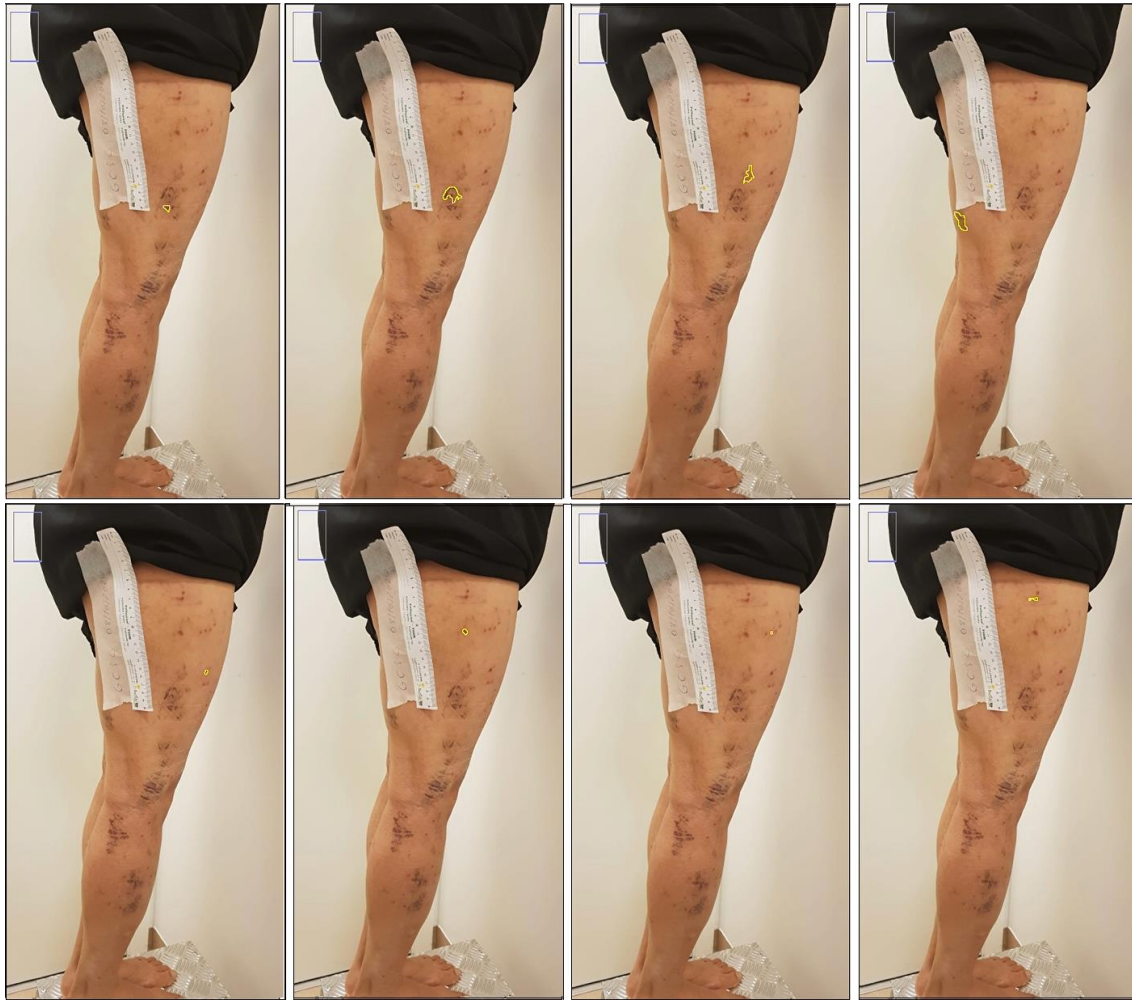After 7 days (+/- 2 days), the participant returned to the research center for clinical evaluation. At this point, a new standardized photographic record of the patient was taken by the vascular surgeon, including anterior, lateral, and posterior views, totaling another 84 photographs. All withdrawal criteria were verified, as well as adherence to postoperative care.

After all records were made, a blinded physician excluded areas without varicose veins, resulting in a total of 40 analyzed areas. Each affected area was analyzed using the ImageJ® software, and measurements of the affected areas were taken. Initially, the program was calibrated to a standard measure for each photograph, using a ruler visible in each record as a reference. The area of each limb was then calculated, as well as the corresponding bruised areas in cm<sup>2</sup>, which were included in comparative tables.



**Figure 1:** Example - Calculation of the total area of the right lateral side of the patient's limb using ImageJ® software





**Figure 2:** Example – calculation of bruise areas on the right lateral side using ImageJ® software.

In addition, the bruised areas were classified by the blinded physician according to the severity of the total area involvement and subsequently analyzed according to the following scale.

Involvement	Percentage of the affected limb
Absense	0%
Light	0-10%
Moderate	10-25%
Severe	> 25 %

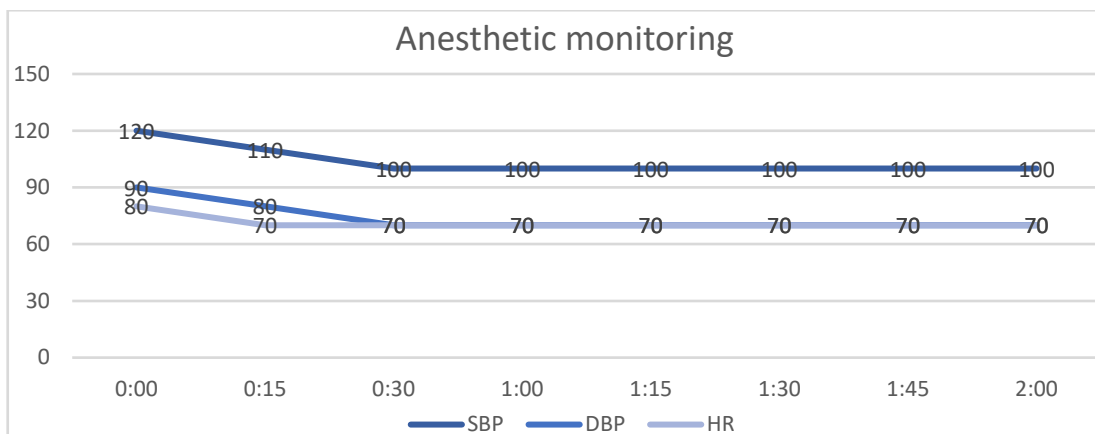
**Table 1:** Scale of severity of bruising in comparison to the total area.

### 3.Results

Out of the 14 patients studied, 168 photographs were taken, with 88 excluded as they did not represent areas with varicose vein involvement. Therefore, a total of 80 photographs were analyzed (pre and postprocedural), representing 40 areas affected by varicose veins in the studied patients.

Among these, 9 were subjected to tumescence in the area of the left limb, and 11 in the right limb. No patients were excluded from the study due to non-adherence to treatment or loss of follow-up.

The anesthetic records of each patient were analyzed and documented to observe possible changes in vital signs. Heart rate and systolic and diastolic blood pressure were monitored, and the averages of their values are illustrated in the graph below.



**Graph 1:** Mean Values of Vital Signs During the Surgical Procedure.

SBP = Systolic Blood Pressure. DBP = Diastolic Blood Pressure. HR = Heart Rate.

Throughout the study, no other complications such as edema, ulceration, intense pain, bleeding, or venous thrombosis were identified.

The data collected by the blinded physician from the bruised areas studied by the software are described in the following table for analysis (Table 2).

Code	Tumescence	Total area (Right)	Bruised areas (Right)	% Right	Total area (Left)	Bruised areas (Left)	% Left
RFOC	Right	661	50	7,56%	579	17	2,94%
AGC 1	Right	653	35	5,36%	684	54	7,89%
AGC 2	Right	662	135	20,39%	657	80	12,18%
AGC 3	Right	667	76	11,39%	648	56	8,64%
SFC	Right	550	80	14,55%	572	44	7,69%
BCG	Right	466	59	12,66%	437	79	18,08%
FCP	Right	612	85	13,89%	494	65	13,16%
VJSD	Right	530	116	21,89%	623	92	14,77%
SMS	Right	393	34	8,65%	414	60	14,49%
SML 1	Left	528	29	5,49%	497	58	11,67%
SML 2	Left	503	6	1,19%	460	5	1,09%
VRSL	Left	835	114	13,65%	728	200	27,47%
VAGA1	Left	395	10	2,53%	392	13	3,32%
VAGA 2	Left	448	56	12,50%	434	37	8,53%
VAGA 3	Left	256	21	8,20%	634	68	10,73%
CAU	Left	705	71	10,07%	694	45	6,48%
VLGCS 1	Left	485	52	10,72%	322	16	4,97%
VLGCS 2	Left	235	12	5,11%	309	17	5,50%
GCSG	Left	439	20	4,56%	596	21	3,52%
EXK	Left	673	44	6,54%	729	58	7,96%

**Table 2:** Description of collected data. Areas (cm2)

Tumescense	Variables	N	Mean	Standard deviation	Median	Interquartile range	Minimum	Maximum
Right	Total area (Right)	9	577,11	99,06	612,00	498 - 661,5	393,00	667,00
	Bruised areas (Right)	9	74,44	34,58	76,00	42,5 - 100,5	34,00	135,00
	% Right	9	12,93	5,55	12,66	8,11 - 17,47	5,36	21,89
	Total area (Left)	9	567,56	98,29	579,00	465,5 - 652,5	414,00	684,00
	Bruised areas (Left)	9	60,78	22,25	60,00	49 - 79,5	17,00	92,00
	% Left	9	11,09	4,66	12,18	7,79 - 14,63	2,94	18,08
Left	Total area (Right)	11	500,18	182,32	485,00	395 - 673	235,00	835,00
	Bruised areas (Right)	11	39,55	32,52	29,00	12 - 56	6,00	114,00
	% Right	11	7,32	4,05	6,54	4,56 - 10,72	1,19	13,65
	Total area (Left)	11	526,82	157,20	497,00	392 - 694	309,00	729,00
	Bruised areas (Left)	11	48,91	54,42	37,00	16 - 58	5,00	200,00
	% Left	11	8,29	7,12	6,48	3,52 - 10,73	1,09	27,47

**Table 3.** Descriptive statistics for the two tumescense groups

Out of the 20 areas studied, 60% (12 areas) had a higher incidence of bruising in the limb where prior tumescense was performed, and 40% (8 areas) had a lower incidence.

All areas where the procedure was performed had some degree of bruising. According to the severity scale, in the areas where tumescense was performed, 55% (11) had bruises considered mild, 40% (8) had moderate bruises, and 5% (1) had severe bruising. In areas where prior tumescense was not performed, the results were similar, with 60% (12) having mild bruises, 40% (8) having moderate bruises, and 0% (none) having severe bruising.

The observed data were characterized using descriptive statistics, including mean, standard deviation, median, interquartile range, minimum and maximum scores. Non-parametric tests were used for hypothesis testing.

Table 3 displays descriptive statistics for the variables of involvement for both limbs of the patient in both groups. It can be observed that, for the group with tumescense in the right limb, the median percentage of involvement in the right limb was 12.66%, and in the left limb, it was 12.18%. For the group with tumescense in the left limb, the median percentage of involvement in the left limb was 6.48%, while in the right limb, it was 6.54%.

The Wilcoxon signed-rank test (Table 4) showed that there were no significant differences in the percentage of affected area between limbs, both in the group with right tumescense ( $T = 13$ ,  $p = 0.26$ ) and in the group with left tumescense ( $T = 29$ ,  $p = 0.72$ ).

Tumescence		T	p
Right	Total area	21,00	0,86
	Bruised areas	10,00	0,14
	% Involvement	13,00	0,26
Left	Total area	33,00	1,00
	Bruised areas	23,50	0,40
	% Involvement	29,00	0,72

**Table 4.** Results of the Wilcoxon signed-rank tests

## Discussion

Varicose vein extraction surgery is widely performed worldwide and involves the mechanical removal of the vessel through micro-incisions in the skin using a needle or blade. Literature describes that the procedure may or may not be preceded by local tumescence with a diluted solution of adrenaline in a ratio of 1:100,000, aiming to reduce bruising as a side effect of this mechanical extraction, considering its vasoconstrictor effect, along with the possible compressive effect due to the local volume increase. Therefore, it is logically expected that there would be a reduction in the bruise area in a limb subjected to such tumescence.

There are no studies in the literature that evaluated the relationship between the infiltration of tumescent solution and the incidence of bruising in varicose vein removal surgery alone. The majority of studies already conducted with prior local tumescence in vascular procedures are in surgeries for varicose veins associated with both mechanical and thermal ablation of saphenous veins.<sup>9,10,11</sup> Another commonly studied type of procedure involves the assessment of the incidence of side effects, including bruising, in the extraction of varicose veins guided by transillumination, where prior tumescence is also performed.<sup>25,26,27</sup>

In a Brazilian study from 2016, Erzinger et al<sup>10</sup> compared groups that underwent varicose vein surgery with saphenectomy with and without prior local tumescence, obtaining similar results. In this study, hematomas occurred in all groups within 7 days. In groups without tumescence, they occurred in less than half of the patients, with the smaller hematomas being more frequent (considered by the study to be up to 25%). In the tumescence group, hematomas occurred in 73.33% of patients, with smaller hematomas accounting for 63.33% of cases ( $p=0.003$ ). Those findings are similar to those found in this present study, whereas tumescence prior to varicose veins surgery did not prevent the incidence of Ecchymosis and bruises postoperative. Furthermore, the Erzinger et al<sup>10</sup> study evaluated patients submitted to saphenectomy regarding tumescence and bruise, while in our study the main analysis was made in patients submitted to varicose veins stripping, without saphenectomy involvement.

Despite the expected vasoconstrictor effect, there is no evidence in the literature, as confirmed by the present study, that the performance of tumescence itself reduces the incidence or intensity of bruising in the postoperative period.

One hypothesis for this discrepancy between the expected and actual effects is a possible rebound effect of adrenaline vasodilation after the initial vasoconstrictor effect, which can lead to blood extravasation sometimes

greater than without the use of tumescence. Lawrence et al,<sup>11</sup> reported good results using a technique where vein removal using the modified crochet hook and mosquito clamp under direct visualization limited bruising and hematoma formation, specially with a tumescence solution, which contains a mixture of 1 L of 0.9% saline, 40 mL of 2% lidocaine, and 2 mg of 1:1000 epinephrine, which was infused at 400 mm Hg pressure until the varicose veins were easily visualized. Those results differ from this present cohort, which can be explained by specially regarding the solution that was used and the use of a light-assisted stab phlebectomy performed by Lawrence et al.<sup>11</sup> Similarly, Vardanian et al<sup>12</sup> reported satisfactory results with a technique using light-assisted stab phlebectomy (LASP). The authors showed that immediate postoperative complications were infrequent, occurring in 10% of patients, and included unresected or missed veins, hematoma, and cellulitis. Moreover, they concluded that LASP provides improved visualization of branch veins and allows varicose veins to be removed with a short operating room time and minor postoperative complications, as well as the use of lower-than-necessary amounts of tumescent solution due to the risk of side effects.<sup>12,13,14</sup>

Other methods have been studied to reduce bruising in patients undergoing vascular procedures. In 2013, Hernández Osma E,<sup>13</sup> conducted a study with 232 patients, comparing those undergoing laser saphenous vein ablation, with one group subjected to

prior local tumescence with adrenaline solution and the other to an external cooling process. Among other effects studied, the tumescence group had an incidence of bruising of 55% ( $p<0.05$ ), while the cooling group had no patients with bruising. However, further studies are needed to validate this technique.

There are indeed other benefits of prior local infiltration described in the literature, especially when associated with anesthetic substances. One benefit is the reduction of postoperative pain, significantly decreasing pain scores in patients undergoing tumescence and reducing the incidence of nerve injury in cases of saphenectomy.<sup>15,16,17</sup>

Harlock et al<sup>16</sup> in an important meta-analysis of nontumescent-based versus tumescent-based endovenous therapies for patients with great saphenous insufficiency and varicose veins showed no overall difference between the groups on a number of outcomes. Those data are similar to those found in this present study, whereas tumescent solution performed prior to varicose vein excision did not prevent or reduce the intensity of bruises. In contrast, there is a case report in the literature of a catastrophic necrotizing fasciitis, an infection with a mortality rate of 30% to 50%, after ambulatory phlebectomy and stripping of the long saphenous vein with use of tumescent



anesthesia, demonstrating that the tumescence is not a harmless and complication-free procedure.<sup>18</sup>

This present study has some limitations: it is a small cohort with short-term analysis, despite being prospective and randomized. Further studies with larger cohorts and long-term analysis should be done in order to properly evaluate the effects of tumescence in the incidence of Ecchymosis in postoperative varicose vein surgery.

### Conclusion

The tumescent solution performed prior to varicose vein excision did not prevent or reduce the intensity of bruises. However, it also did not bring local or systemic complications to the patients.

### Acknowledgments

None

### Declaration of conflicting interests

The authors declare that they have no conflicts of interest.

### Funding

None

### References:

- Rabe E, Berboth G, Pannier F. Epidemiology of chronic venous diseases. *Wien Med Wochenschr* 2016;166:260–263.
- Gloviczki P, Gloviczki ML. Guidelines for the management of varicose veins. *Phlebology* 2012;27 Suppl 1:2–9. D 3. Raffetto JD, Mannello F. Pathophysiology of chronic venous disease. *Int Angiol*. 2014 Jun;33(3):212-21. Epub 2014 Apr 23
- Eklof B, Rutherford RB, Bergan JJ et al. Revision of the CEAP classification for chronic venous disorders: consensus statement. *J Vasc Surg*. 2004; 40:1248-52
- Klein JA. The Tumescent technique: anesthesia and modified liposuction technique. *Dermatol Clin* 1990; 8:439-4350
- Lillis PJ. The Tumescent technique for liposuction surgery. *Dermatol Clin* 1990;8:439-435
- Cohn, MS et al. Ambulatory phlebectomy using the tumescent technique for local anesthesia. *Dermatol Surg*. 1995 Apr;21 (4): 315-318
- Timothy D; Parish MD. A Review: The Pros and Cons of Tumescent Anesthesia in Cosmetic and Reconstructive Surgery. *The American Journal of Cosmetic Surgery*. 2001;18: 83-93.
- Leal FJ et al. Translation and cultural adaptation of Aberdeen Varicose Veins Questionnaire. *J Vasc Bras*. 2012;11(1): 34-42.
- Erzinger, FL et al. Estudo comparativo da termoablação da veia safena magna na coxa, com e sem tumescência. *J. vasc. bras*. 2016, vol.15, n.3 [cited 2021-01-21], pp.217-223
- Lawrence PF, Vardanian AJ. Light-assisted stab phlebectomy: report of a technique for removal of lower extremity varicose veins. *J Vasc Surg*. 2007 Nov;46(5):1052-1054.
- Vardanian AJ, Cao HL, Lawrence PF. Light-assisted stab phlebectomy: early postoperative experience. *Am Surg*. 2007 Oct;73(10):1067-70. PMID: 17983083
- Aremu MA, Mahendran B, Butcher W, Khan Z, Colgan MP, Moore DJ, Madhavan P, Shanik DG. Prospective randomized controlled trial: conventional versus powered phlebectomy. *J Vasc Surg*. 2004 Jan;39(1):88-94. doi: 10.1016/j.jvs.2003.09.044. PMID: 14718823.
- S R Smith 1, M P Goldman. Tumescent anesthesia in ambulatory phlebectomy. *Dermatol Surg*. 1998 Apr;24(4):453-456.
- Hernández Osmá E, Mordon SR, Marqa MF, Vokurka J, Trelles MA. A comparative study of the efficacy of endovenous laser treatment of the incompetent great saphenous under general anesthesia with external air cooling with and without tumescent anesthesia. *Dermatol Surg*. 2013;39(2):255–262
- John A Harlock 1, Fadi Elias 2, Mohammad Qadura 3, Luc Dubois. Meta-analysis of nontumescent-based versus tumescent-based endovenous therapies for patients with great saphenous insufficiency and varicose veins. *J Vasc Surg Venous Lymphat Disord*. 2018 Nov;6(6):779-787.e6.
- Hirsch T. Varicose vein therapy and nerve lesions. *Vasa*. 2017 Mar;46(2):96-100. Epub 2016 Dec 16. PMID: 27981883
- Martin G HubmerHorst KochFranz M HaasMichael HornOliver SankinErwin Scharnagl. Necrotizing fasciitis after ambulatory phlebectomy performed with use of tumescent anesthesia. *Journal of Vascular Surge*



This work is licensed under Creative Commons Attribution 4.0 License

To Submit Your Article Click Here: **Submit Manuscript**

DOI:[10.31579/2641-0419/376](https://doi.org/10.31579/2641-0419/376)

**Ready to submit your research? Choose Auctores and benefit from:**

- fast, convenient online submission
- rigorous peer review by experienced research in your field
- rapid publication on acceptance
- authors retain copyrights
- unique DOI for all articles
- immediate, unrestricted online access

At Auctores, research is always in progress.

Learn more <https://auctoresonline.org/journals/clinical-cardiology-and-cardiovascular-interventions>