

# A Case Presenting a Novel Treatment of Palmoplantar Eczema: Dopaminergic Drugs

Jacquelyn J. Torikashvili <sup>1</sup>, Jerome H. Check, MD, Ph.D. <sup>2,3\*</sup>, Megan McDonald O'Neil, MS <sup>3</sup>, Madison Neulander BS <sup>3</sup>

<sup>1</sup> Brandeis University, Waltham, MA, USA.

<sup>2</sup> Department of Obstetrics/Gynecology. University Camden, NJ, USA.

<sup>3</sup> Division of Reproductive Endocrinology and Infertility at Cooper, Medical School of Rowan University Camden, NJ, USA.

<sup>4</sup> Research Assistant for Cooper Institute for Reproductive Hormonal Disorders, Mt Laurel, NJ, USA.

**\*Corresponding Author:** Jerome H Check, Department of Obstetrics/Gynecology. Division of Reproductive Endocrinology and Infertility at Cooper Medical School of Rowan University, Camden, NJ.

**Received Date:** December 16, 2024 | **Accepted Date:** January 03, 2025 | **Published Date:** January 09, 2025

**Citation:** Jacquelyn J. Torikashvili, Jerome H. Check, MD, Ph.D., Megan McDonald O'Neil, MS, Madison Neulander BS, (2025), A Case Presenting a Novel Treatment of Palmoplantar Eczema: Dopaminergic Drugs, *International Journal of Clinical Case Reports and Reviews*, 22(2); DOI:10.31579/2690-4861/631

**Copyright:** © 2025, Jerome H. Check. This is an open-access article distributed under the terms of the Creative Commons Attribution License, which permits unrestricted use, distribution, and reproduction in any medium, provided the original author and source are credited.

## Abstract:

Palmoplantar eczema is a pruritic, painful condition presenting with clear fluid filled intraepidermal vesicles involving the lateral aspects of the fingers frequently extending into the palms, and also frequently involving the soles of the feet and tends to be recurrent. There are many topical and systemic immunosuppressive agents that have been tried, but treatment has not produced great results in either causing quick resolution of the rash nor prevention of frequent recurrence. Increased cellular permeability allowing infusion of irritants into various tissues leading to inflammation has been proposed as a common etiologic factor in a large variety of inflammatory and "autoimmune" pathological entities including various dermatologic conditions. Most of these conditions have responded well to dopaminergic drugs especially dextroamphetamine despite being refractory to standard therapy. Dopamine diminishes cellular permeability. A case is presented of using dextroamphetamine to eradicate palmoplantar eczema and prevent recurrences.

**Key words:** palmoplantar eczema, dyshidrotic eczema, dopamine, amphetamines, increased cellular permeability syndrome

## Introduction

One of the conditions that can cause a dermatitis of the hands and feet is known as palmoplantar eczema which usually involves both hands (frequently involving the lateral aspects of the fingers sometimes extending to the palms) and the soles of the feet. In contrast to dry, patchy skin seen with typical types of eczema, in this case, the rash is manifested by vesiculobullous lesions sometimes giving the appearance of "tapioca pudding" [1]. This appearance seems to be related to an intraepidermal spongiosis of the thick epidermis in which accumulation of edema causes the formation of clear fluid filled vesicles that are small but tense [2].

The precise etiology is unknown. The diagnosis is generally made based on the characteristic type of vesicles and their location, and the fact that though there is an acute onset, it is frequently recurrent [3]. There are many different treatments including topical corticosteroids and calcineurin inhibitors for acute cases, or immunosuppressive agents for recurrent cases, including systemic corticosteroids, mycophenolate mofetil, azathioprine, cyclosporine, dupilimab, methotrexate, and

upadacitinib [4,5]. One of the newest treatments for dyshidrotic palmoplantar eczema is tralokinumab, which is a fully human monoclonal antibody injection aimed at neutralizing interleukin 13, a major cytokine involved in the cellular permeability defects leading to pruritic skin conditions [6]. These treatments have only had a modest beneficial effect in preventing recurrent episodes of this hand and sole dermatitis which has multiple names including dyshidrotic eczema, pompholyx, and acute palmoplantar eczema. Dyshidrotic eczema is one of the older terms, but it is probably a misnomer because originally it was thought to be a pathological condition of the sweat glands, but this is not known to be true [4]. However, one possible precipitation factor is hyperhidrosis [2, 4].

A case is presented of an 18-year-old female who has had a complete long-lasting remission from palmoplantar eczema with a novel therapy. Most inflammatory conditions are treated by medications that suppress inflammation. The novel aspect of this treatment is that this medication targets the potential cause of most inflammatory conditions, i.e., increased

cellular permeability. In some cases, this is related to a relative dopamine deficiency leading to infiltration of irritants into tissues causing inflammation and pain. The dopaminergic drugs work by releasing more dopamine from sympathetic nerve fibers leading to inhibition of infiltration of these irritants into tissues [7-9]

**Case Report**

An 18-year-old female developed irritation of the fingers and palms bilaterally and the lateral sides of both feet. She soon developed blisters in the areas of irritation. Besides blisters, the affected areas were erythematous. The textures of her hands had become rough, sweaty, and sticky. She found it difficult to even hold a pencil.

She noticed that sweating of the hands and feet, or not completely drying them after washing, would make the rash and discomfort even worse with the development of more blisters. She had the typical “tapioca pudding” appearance of the palmar blisters. The condition had been present for months when she sought our opinion as to the cause and therapy. The patient herself from searching the internet had self-diagnosed herself, and

based on the history, location of the lesions, and appearance, we confirmed her diagnosis. Based on successful therapy of other dermatological conditions that had been refractory to conventional therapy with the dopaminergic drug dextroamphetamine sulfate, she was treated with 20mg amphetamine sulfate tablets providing 12.5mg dextroamphetamine sulfate. She quickly responded to therapy within one week. She now has been taking dextroamphetamine sulfate for 14 months and remains in complete remission.

**Discussion**

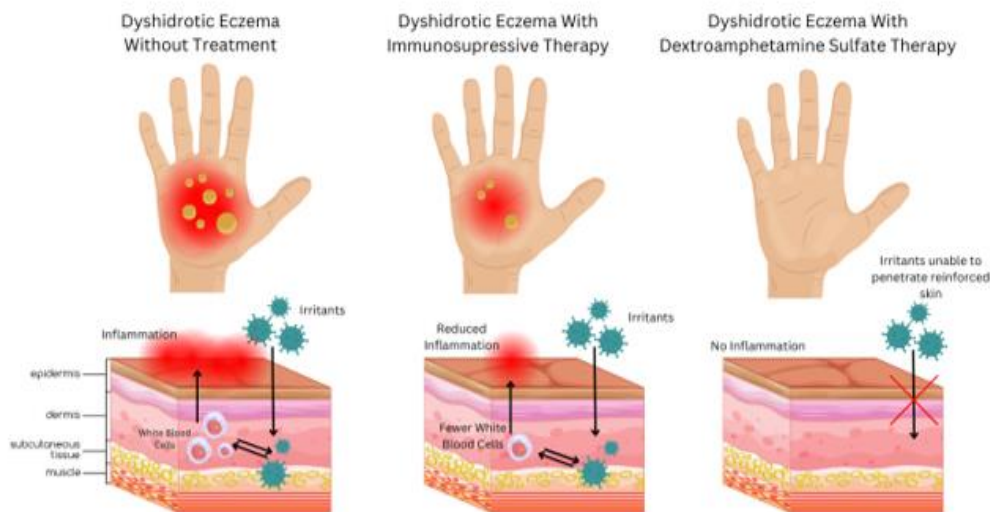
There are several anecdotal reports demonstrating significant correction of various treatment refractory dermatologic conditions that have responded to the dopaminergic drug dextroamphetamine sulfate as seen in table 1 [10-19]. Dextroamphetamine has also been successful for neurologic implications following skin lesions, e.g., post-herpetic neuralgia [18]. Dextroamphetamine sulfate has also been highly effective for blister lesions on mucosal surfaces e.g., recurrent aphthous stomatitis [20].

Condition	Reference Number
1. chronic or premenstrual urticaria	9, 10, 12, 17
2. chronic eczema	14
3. chronic keratosis pilaris	14
4. chronic generalized pruritus	15, 16
5. bullous pemphigoid	17
6. cutaneous discoid lupus erythematosus	18
7. resistant post-herpetic neuralgia	19

**Table 1:** Dermatologic Conditions That Have Been Treated with the Dopaminergic Drug Dextroamphetamine Sulfate

The mechanism seems to be related to increased cellular permeability allowing irritants to infuse into certain tissues causing inflammation. Dopaminergic drugs e.g., dextroamphetamine, act to diminish cellular permeability thus inhibiting irritants from entering the dermis. There are actually a multitude of various conditions that do not respond well to

conventional therapy but respond to dopaminergic therapy [7-9]. Figure 1 shows the differences in the target location for dopaminergic drugs vs. anti-inflammatory drugs for palmoplantar eczema and other skin disorders.



**Figure 1:** Differences in the Target of Location for Dopaminergic Drugs vs. Anti-inflammatory Drugs for Skin Disorders

Though we have used dextroamphetamine for over 40 years in thousands of patients without any addiction or serious consequences, nevertheless, amphetamines have been classified as a drug in the same category as opiates e.g., fentanyl. For that reason, there have been many restrictions placed on it even though it is commonly used for children with attention

deficit hyperactivity disorder without serious consequences. It certainly has far less side effects than glucocorticoids and immunosuppressants that can also be immensely expensive and can lead to serious complications, e.g., infection and even cancer. Nevertheless, other dopaminergic drugs could be considered e.g., cabergoline which has also demonstrated

efficacy in certain treatment resistant conditions [20, 21]. The most recent drug showing efficacy in treating palmoplantar eczema is tralokinumab, which was recently approved for atopic dermatitis [6]. Because this condition is rare and both treatments are measured in single case studies, we cannot state which treatment is more effective. Because of the rarity of the condition, it is unlikely a randomized controlled comparison will be made. While generally well tolerated, the reported side effects of tralokinumab include conjunctivitis, eosinophilia, and keratitis [23]. Our 45-year experience with dextroamphetamine sulfate has shown few side effects and no major complications.

## Conclusion

Since this was only a single case, possibly the very good response to dextroamphetamine could have been fortuitous. Nevertheless, the excellent response in this case should warrant a larger clinical trial of dopaminergic drugs for this relatively rare condition.

## Contribution

Jacquelyn Torikashvili, Megan McDonald O'Neil, and Madison Neulander all contributed to researching pertinent references and in the writing of the introduction and case report. JT slightly contributed more than MMO and MN. Jerome H. Check initiated the idea to treat the patient with dextroamphetamine. He also wrote the large majority of the discussion. Jerome H. Check provided the concept for Figure 1 whereas Jacquelyn Torikashvili and Madison Neulander designed Figure 1 using Canva.

## References

1. Agner T, Aalto-Korte K, Andersen KE, Foti C, Gimenez-Arnau A, et al. (2015). Classification of hand eczema, *J Eur Acad Dermatol Venerol*, 29(12): 2417-2422.
2. Wollina U. (2010). Pompholyx: a review of clinical features, differential diagnosis, and management. *Am. J Clin Dermatol*, 11:305-314.
3. Fox T. (1876). Dyshidrosis: "cheiro-pompholyx" [letter]. *Lancet*, 1:651.
4. Lofgren SM, Warshaw EM. (2006) Dyshidrosis: epidemiology, clinical characteristics, and therapy. *Dermatitis*, 17(4): 165-181.
5. Kiszla BM, Orlowski TJ, Kole LC. (2023). Efficacy and tolerance of upadacitinib in the treatment of dyshidrotic eczema. *JAAD Case Reports*, 38: 141-143.
6. Parmar NV, Hammadi AA. (2024). Successful treatment of dyshidrotic palmoplantar eczema with tralokinumab. *Australas J Dermatol*, 65(6): e176-e177.
7. Check JH. (2017). Changing the name of a syndrome: sympathetic neural hyperalgesia edema syndrome becomes – the increased cellular permeability syndrome. *Clin. Exp. Obstet. Gynecol*, 44(6): 819–823.
8. Check DL, Check JH. (2020). Various presentations of the increased cellular permeability syndrome in males responding very well to sympathomimetic amine therapy – possible treatment for end-stage Covid-19 complications. *J Med Clin Res & Rev*, 4(7): 1-7.
9. Check JH. (2024). Most chronic conditions in women are related to increased cellular permeability and most can be effectively treated with dopaminergic drugs. *J Biomed Res Environ Sci*, 5(4): 373-386.
10. Check JH, Gentlesk MJ, Falanga V. (1984). Sympathomimetic amines in the treatment of chronic urticaria: Two reports. *Cutis*, 34: 388-390.
11. Check JH, Amadi C, Kaplan H, Katsoff D. (2006). The treatment of idiopathic edema, a cause of chronic pelvic pain in women: effectively controlled chronic refractory urticaria – case reports. *Clin Exp Obstet Gynecol*, 33:183-184.
12. Check JH, Dougherty MP. (2019). Use of sympathomimetic amines to correct premenstrual urticaria and anaphylaxis. *Clin Exp Obstet Gynecol*, 46:309-312.
13. Check JH, Cohen R., Check D. (2010). Idiopathic edema, a condition associated with pelvic pain and other symptoms in women, as a remedial cause of chronic cold induced urticaria. *Clin Exp Obst Gyn*, 37: 235-236.
14. Check JH, Chan S. (2014). Complete eradication of chronic long-standing eczema and keratosis pilaris following treatment with dextroamphetamine sulfate. *Clin Exp Obstet Gynecol*, 1:202-204.
15. Check JH, Cohen R. (2017). Amelioration of severe generalized idiopathic pruritus in an estrogen deficient woman taking an aromatase inhibitor for breast cancer following treatment with amphetamine salts. *Clin Exp Obstet Gynecol*, 44:934-935.
16. Lombardi G, Check JH. (2024). A novel effective therapy for chronic generalized pruritus without presence of skin lesions. *J Med Clin Res & Rev*, 8(5): 1-4.
17. Check JH, Neumann BA, Check DL. (2024). Dopaminergic drugs for the successful treatment of bullous pemphigoid (BP). *J Med Clin Res&Rev*, 8(3): 1-3.
18. Check JH, Neumann BA, Check DL. The use of dopaminergic drugs for treating cutaneous discoid lupus erythematosus: a case study. *J Med Clin Res&Rev*, 8(3): 1-3.
19. Check JH, Dougherty MP, Check DL. (2019). Long standing post-herpetic neuralgia resistant to standard anti-neuropathy medication showing quick dramatic improvement following treatment with sympathomimetic amines. *Clin Exp Obstet Gynecol*, 46: 335-336.
20. Present SI, Check JH. (2016). Hypofunction of the sympathetic nervous system as a possible etiologic cause of recurrent aphthous stomatitis. *Compend Contin Educ Dent*, 37(6): 381-385.
21. Check JH, Check DL, Neumann B. (2024). Marked improvement of severe treatment resistant migraine headaches with the dopaminergic drug cabergoline. *J Med-Clin Res&Rev*, 8(3):1-5.
22. Check JH, Check D. (2023). Improvement of severe chronic pelvic pain and dysmenorrhea following treating with cabergoline. *Gynecol Reprod Health*, 7(1):1-6.
23. Blair H. A. (2022). Tralokinumab in Atopic Dermatitis: A Profile of Its Use. *Clinical drug investigation*, 42(4):365–374.



This work is licensed under Creative Commons Attribution 4.0 License

To Submit Your Article Click Here:

[Submit Manuscript](#)

DOI:10.31579/2690-4861/631

**Ready to submit your research? Choose Auctores and benefit from:**

- fast, convenient online submission
- rigorous peer review by experienced research in your field
- rapid publication on acceptance
- authors retain copyrights
- unique DOI for all articles
- immediate, unrestricted online access

At Auctores, research is always in progress.

Learn more <https://auctoresonline.org/journals/international-journal-of-clinical-case-reports-and-reviews>