

Results of Retrograde Intramedullary Osteosynthesis in Femur Fractures, Analysis of 196 Consecutive Cases

Horacio Tabares Neyra *, Horacio Tabares Sáez

Havana Medical University

*Corresponding Author: Horacio Tabares Neyra, Havana Medical University.

Received Date: 17 November 2024; Accepted Date: November 25 2024; Published Date: 02 December 2024

Citation: Horacio T. Neyra, Horacio T. Sáez, (2024), Results of Retrograde Intramedullary Osteosynthesis in Femur Fractures, Analysis of 196 Consecutive Cases, *J. Clinical Orthopedics and Trauma Care*, 6(8); DOI:10.31579/2694-0248/112

Copyright: © 2024, Horacio Tabares Neyra. This is an open access article distributed under the Creative Commons Attribution License, which permits unrestricted use, distribution, and reproduction in any medium, provided the original work is properly cited.

Abstract

Introduction: Fractures of the femoral shaft have a high annual incidence. Factors that determine surgical management include fracture location, degree of comminution, concomitant injuries, and preoperative functional status. The retrograde femoral nail has been shown to be a safe alternative, especially in bilateral or distal femur fractures, ipsilateral femoral neck or tibia fractures, obesity, and abdominal and pelvic trauma. The purpose of this study was to evaluate the indications, surgical technique, investigate the incidence and severity of knee pain after retrograde intramedullary nailing of femur fractures and thus better understand the functional results using osteosynthesis with retrograde nails in femoral shaft fractures.

Methods: All patients undergoing retrograde intramedullary nailing for femoral shaft fractures between June 2017 and August 2023 at a level 1 trauma center were reviewed. One year of follow-up or documented fracture healing were required. Records were reviewed for documentation of septic arthritis of the ipsilateral knee during the follow-up period.

Results: The fractures were classified, according to AO/OTA, as: 80 type 32A (42 - 32A1, 20 - 32A2 and 18 - 32A3); 60 type 32B (33 - 32B2, 27 - 32B3) and 56 type 32C (29 - 32AC2 and 27 - 32AC3). The average time to union was 19,5 weeks. There was one case of delayed union. The average knee range of motion was 130° of flexion (minimum 100° and maximum 150°). Eight patients (4,08%) reported knee pain.

Conclusions: The retrograde nail for the treatment of femur diaphyseal fractures achieves consolidation results similar to those of the antegrade femur nail. Its possible advantages are the simple technique, shorter surgical time and the possibility of operating without the use of a traction table.

Keywords: femur shaft fracture; retrograde nailing; results

Introduction

Fractures of the femoral shaft have a high incidence. Most occur due to high-energy mechanisms, but they can also occur from low-energy falls, especially in older populations. These fractures may be associated with additional injuries or multisystem trauma, posing many challenges to the treating orthopaedic surgeon[1].

Femoral shaft fractures have an annual incidence of 10 to 21 per 100,000 persons, with a bimodal distribution that peaks among younger men and older women. These injuries demonstrate peak incidences among younger men (15-35 years) and older women (over 60 years).[2-4]

Femoral shaft fractures in young men are often attributed to high-energy trauma, including motor vehicle collisions, falls from height, and gunshot wounds. In contrast, older women sustain this injury secondary to low-energy mechanisms, such as falls from height, often in the setting of underlying osteoporosis. [1]

There are numerous treatment options to stabilize femoral shaft fractures. The most common method is intramedullary nailing via an antegrade approach at the hip or retrograde approach at the knee. Intramedullary nailing is a proven and effective method for the treatment of femoral shaft fractures. The appropriate entry site can facilitate nail insertion, affect fracture reduction, and prevent complications. [5-7]

Although either end of the femur is suitable, there is debate in the literature regarding antegrade versus retrograde entry and, in antegrade nailing, the choice of the piriform fossa versus the greater trochanter as the entry point. [5-9]

Antegrade nailing is useful for the treatment of proximal femoral fractures; however, studies have found that it causes damage to the hip abductors and sometimes the pudendal nerve if the patient is supine on a fracture table.[5,10]

Retrograde nailing is advantageous for patients with multiple injuries, patients with ipsilateral femoral neck and shaft fractures, and obese patients; However, it may be associated with higher rates of knee pain and lower union rates.[11-12]

The retrograde femoral nail has gained popularity since its original description by Swiontowski in which an extra-articular approach to the distal femur was described. It was subsequently modified to an intra-articular and intracondylar approach, as described by Patterson in 1995. Retrograde placement of a femoral nail initially emerged as an attractive alternative in supracondylar or low diaphyseal femoral fractures to minimize complications associated with antegrade intramedullary nailing and simplify the procedure. Later, its indication was extended to diaphyseal fractures in the previously described scenarios; due to the relative ease of the procedure, its indications were expanded.[13]

Factors that determine surgical management include fracture location, degree of comminution, concomitant injuries, and preoperative functional status. The retrograde femoral nail has been shown to be a safe alternative, especially in bilateral or distal femur fractures, ipsilateral femoral neck or tibia fractures, obesity, and abdominal and pelvic trauma.[14]

Considering the controversial aspects regarding the indication of surgical treatment by means of retrograde intramedullary nail osteosynthesis for

femoral shaft fractures, we posed the hypothesis that “Performing surgical treatment consisting of retrograde intramedullary osteosynthesis in patients diagnosed with femoral shaft fracture produces results classified as good, with a low incidence of complications”. In order to respond to our hypothesis in the solution of the aforementioned scientific problem, we planned a prospective longitudinal intervention research, type of case series, with elderly patients diagnosed with femoral shaft fracture and treated by surgical treatment with retrograde intramedullary osteosynthesis in the orthopedics and traumatology service of the “Calixto García” University Hospital.

Purpose

Characterize the sample according to biomedical variables; Evaluate the indications, incidence and severity of knee pain after retrograde intramedullary nailing of femur fractures and thus better understand the functional results using osteosynthesis with retrograde nails in femoral shaft fractures and demonstrate the results obtained through the application of evaluation instruments.

Material & Methods

All patients undergoing retrograde intramedullary nailing for femoral shaft fractures between June 2017 and August 2023 at a level 1 trauma center were reviewed.

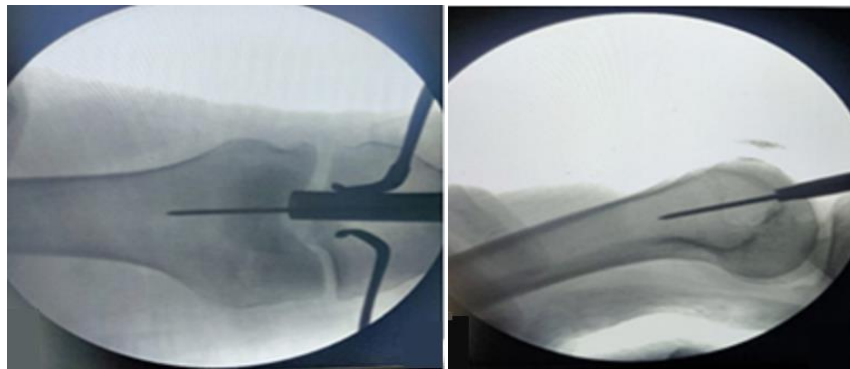


Figure 1. Guide for placing the guide wire for retrograde nailing of the femur.

Source: Garg A, Saini A, Gupta A, Sharma R, Mishra RK.

One year of follow-up or documented fracture healing were required. Records were reviewed for documentation of septic arthritis of the ipsilateral knee during the follow-up period.

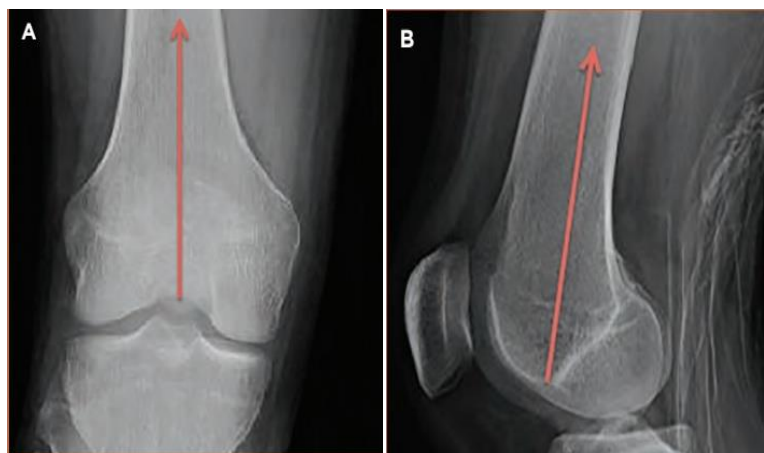


Figure 2. Recommended trajectory in AP and Lateral views, for retrograde intramedullary nailing of the femur.

Source: DeCoster ThA, Patti BN. Retrograde Nailing for Treating Femoral Shaft Fractures: A Review. UNMORJ 2018; 7:46-54.

Results

A total of 230 potentially eligible patient, The sample was limited to 196 patients after the application of inclusion and exclusion criteria. Of them, 82

were women (41.8%) and 114 men (58.2%) with a mean age of 37.7 ± 1.5 years. It was decided to determine the body mass index, due to its relationship with the possibility of performing the reduction and placement

of the retrograde intramedullary nail in a closed manner; the mean body mass index found was $27 \pm 3.7 \text{ Kg/m}^2$.

There were 20 open fractures (seven grade I, six grade II and seven grade III). There was a predominance of associated injuries in the musculoskeletal

system (MSS), with a mean surgical time of just over an hour, little blood loss and a mean period until consolidation of 19.5 weeks. All of this is visible in Table 1.

Variable	Records	%
Age	Mean $37,7 \pm 1,5$	
Sex		
Male	N = 114	58,2%
Female	N = 82	41,8%
Body mass index	Average value $27 \pm 3,7 \text{ Kg/m}^2$	
AO/OTA Classification		
32A	N = 80	40,8%
32B	N = 60	30,6%
32C	N = 56	28,6%
Open fracture (N = 20) Gustilo-Anderson classification		
I	N = 7	35,0%
II	N = 6	30,0%
III A	N = 4	20,0%
III B	N = 3	15,0%
Associated injuries		
From SOMA	N = 92	46,9%
From other organs/ systems	N = 27	13,77%
Cause of fracture		
Car crash	N = 122	62,2%
Other causes	N = 74	37,8%
Surgical time	Mean 74 ± 15 minutes	
Surgical blood loss	Mean 205 ± 23 ml	
Time to consolidation	Mean 19,5 weeks (14 - 28)	

Table 1. Biomedical variables of the sample.

Source: Data collection form.

We think that the type of fracture according to the AO/OTA classification can influence both the consolidation time and the possible complications that could arise. It should be noted that there was no predominance of any of the types studied. The fractures were classified, according to AO/OTA, as: 80

type 32A (42 - 32A1, 20 - 32A2 and 18 - 32A3); 60 type 32B (33 - 32B2, 27 - 32B3) and 56 type 32C (29 - 32AC2 and 27 - 32AC3). The method used to perform fracture reduction is shown in Table 2, where the clear predominance of the closed reduction option can be seen.

Classification	reduction	screw	clamp	reduction
AO/OTA	Closed	Poller	Percutaneous	Open
32A	56(70,0)	4(5,0)	7(8,6)	13(16,4)
32B	38(63,3)	3(5,0)	8(13,4)	11(18,3)
32C	36(63,2)	2(3,5)	10(17,5)	8(15,8)

Table 2. Fracture reduction technique.

Shown as: count (percentage)

Source: Data collection form.

Note: % of the total of each type of fracture.

ANOVA Kruskal Wallis $H = 4.821$; 1 df $p = 0.017$

In relation to the complications encountered, the X-rays taken at one year of follow-up showed that four patients had a slight varus deviation ($< 10^\circ$), another four with a posterior angulation of $10^\circ - 20^\circ$. In no case did these residual deformities affect walking and knee mobility.

Only on three occasions, open fractures classified as IIIA and IIIB, developed superficial infections that required a greater number of healing sessions, and administration of antibiotics, but the final result was the cure of these infections. In no case was there a process of septic arthritis of the knee. One patient with a bilateral fracture developed a deep vein thrombosis in the immediate postoperative period, which was treated with the administration of anticoagulants, achieving healing.

Regarding the postoperative pain variable, with the use of the visual analog scale, it was found that 188 patients were placed in category 0 (95.9%), another six were placed in category 1 (3,08%) and the remaining two was classified as 2 (1,02%).

Those who oppose retrograde nailing of fractures of the diaphysis of the femur, refer to the possible limitation of postoperative mobility of the knee and the presence of pain at that level. In this work, the modified HSS knee scoring system was used to determine the quality of knee mobility one year after surgery in our 196 patients. We show the results of the application of this scale in relation to the types of fractures, taking into account the feasibility of individual rehabilitation guided by a rehabilitation technician.

Classification (AO/OTA)	Total
-------------------------	-------

Scale modified "Knee scoring system"	32A		32B		32C			
	No	%	No	%	No	%	No	%
Excellent	76	94,7	55	91,7	51	91,0	182	92,9
Good	3	3,8	3	5,0	3	5,4	9	4,6
Border line	1	1,5	2	3,3	2	3,6	5	2,5
Bad	-	-	-	-	-	-	-	-
Total	80	100	60	100	56	100	196	100
Total %	40,8		30,6		28,6		100,0	

Source: Data collection form.

Table 3. Results of the modified HSS "knee scoring system" scale-AO/OTA classification.

Discussion

Fractures of the diaphysis of the femur occur in older patients (after suffering mild or moderate trauma and with poor bone quality) and in young patients (due to high-energy trauma and after suffering traffic and work accidents). The diagnosis is based on the general symptomatology of the fractures and on the plain radiograph; a computed axial tomography (CT) scan is often necessary in order to visualize intercondylar lines not visible on the plain radiograph, the existence of which may modify the therapeutic suitability.

As reported by most of the authors reviewed, in this study there was a predominance of men over women with fractures of the femoral shaft.

The type of treatment is conditioned by the patient's bone quality, the patient's functional capacity and the type of fracture that occurs, with the most commonly used classification being AO/OTA. All the studies reviewed use the AO/OTA classification to determine the type of fracture to which retrograde interlocking is performed; Breyer found that all of them could be classified as OTA 32 or 33 (supracondylar) in his 53 femur fractures.⁴ Gill reported seven patients 33A1, 10 type 33A2 and three type 33A3.¹⁰ In this study, of the 196 fractures of the femoral shaft treated, 80 corresponded to type 32A, 60 to 32B and 56 to type 32C of the AO/OTA classification.

One of the recognized advantages of the retrograde approach for intramedullary nailing of femur fractures is the comfort in the supine position, to treat other associated injuries. The findings of this study were that in 119 fractures, there were lesions that indicated the use of the retrograde approach, 47 fractures of the pelvis, seven of the acetabulum, 28 of the ipsilateral tibia shaft causing floating knee (five of them open), 10 fractures of the contralateral femur (two open), as well as 27 injuries of other systems (skull, chest and abdomen).

In our series, 18 patients with bilateral fractures were found, 106 were in the right lower limb and 72 in the left.

The main cause of fractures in this study was automobile accidents (N = 122, 62,24%), while Shafiq found 100 fractures (71.43%) due to this cause, 30 fractures (21.43%) due to falls and the rest due to other causes.¹⁹ It is evident that there is similarity among most of the authors consulted in that traffic accidents are the main cause of fractures of the femoral shaft.

Regarding surgical time and transsurgical blood loss; Salphale reported a mean surgical time of 60 ± 10 minutes and a mean surgical blood loss of 80 ml.¹⁶ Garg in his work found an operative time of 125 ± 10.15 minutes and a blood loss of 230 ± 20.5 ml.¹³ Gill reported a surgical time of 102.3 ± 20.6 with a blood loss of 323.0 ± 74.3.¹⁰ For Neubauer the mean surgical time was 86.2 min (minimum 26 min/maximum 219 min).¹⁷ According to Gurkan, their mean surgical time was greater than 131 min when fracture reduction was performed open, and 127.5 min on percutaneous reduction occasions, while the mean blood loss was 720 mL (range 300-1200) for open approaches, and 357 mL (range 250-500) for percutaneous approaches.¹⁸ In this study, the mean surgical time was 74 ± 15 min with an operative blood loss of 205 ± 23 ml.

The vast majority of the authors report similar indices of bone consolidation between the anterograde and retrograde approaches. Our average time to bone healing was 19.5 weeks with a range between 14 and 28 weeks.

In fact, the complications found in this study were few, which is related to what was found by other authors.

In this study, the modified "knee scoring system" scale of the Hospital de Cirugía Especiales was used, finding that one year after surgical treatment 182 knees (92,9%) were classified as EXCELLENT, nine (4,6%) as GOOD and five knee (2,5%) as BORDERLINE.

Conclusions

The retrograde nail for the treatment of femur diaphyseal fractures achieves consolidation results similar to those of the anterograde femur nail. Its possible advantages are the simple technique, shorter surgical time and the possibility of operating without the use of a traction table.

Bibliography

1. Bailey RS, Nwadike BA, Revak Th (2023). A retrospective review of the rate of septic knee arthritis after retrograde femoral nailing for traumatic femoral fractures at a single academic institution. *OTA International* 2023:e264.
2. Denisiuk M, Afsari A. National Library of Medicine: StatPearls. Femoral Shaft Fractures.
3. Brewster J, Grenier G, Taylor BC (2020). Long-term Comparison of Retrograde and Antegrade Femoral Nailing. *Orthopedics*. 2020; 43(4):e278-e282.
4. Breyer G, Usmani K, Hwang R, Begley B, Mashru RP, Gutowski ChJ (2023). Knee Pain and Functional Outcomes after Retrograde Femoral Nailing: A Retrospective Review. *Arch Bone Jt Surg*. 2023; 11(3):218-24
5. Hussain N, Naz Hussain F, Sermer C, Kamdar H, Schemitsch EH, et.al (2017). Antegrade versus retrograde nailing techniques and trochanteric versus piriformis intramedullary nailing entry points for femoral shaft fractures: a systematic review and meta-analysis. *Can J Surg*. 2017; 60(1).
6. Winqvist RA, Hansen ST, Clawson DK (1984). Closed intramedullary nailing of femoral fractures: A report of five hundred and twenty cases. *J Bone Joint Surg Am* 1984; 66(4):529-39. PMID: 11741073
7. Kale SP, Patil N, Pilankar S (2006). Correct anatomical location of entry point for antegrade femoral nailing. *Injury* 2006; 37:990-3.
8. Starr AJ, Hay MT, Reinert CM (2006). Cephalomedullary nails in the treatment of high-energy proximal femur fractures in young patients: a prospective, randomized comparison of trochanteric versus piriformis fossa entry portal. *J Orthop Trauma* 2006; 20:240-6.
9. Ricci WM, Schwappach J, Tucker M (2006). Trochanteric versus piriformis entry portal for the treatment of femoral shaft fractures. *J Orthop Trauma* 2006; 20:663-7.
10. Gill SP, Mittal A, Raj M, Singh P, Singh JR, kumar S (2017). Extra Articular Supracondylar Femur Fractures Managed with Locked Distal Femoral Plate or Supracondylar Nailing: A Comparative Outcome Study. *Journal of Clinical and Diagnostic Research*. 2017; 11(5):RC19-RC23.

11. Marecek GS, Nicholson LT, Broghammer FH (2018). Risk of knee sepsis after treatment of open tibia fractures: a multicenter comparison of suprapatellar and infrapatellar approaches. *J Orthop Trauma*. 2018; 32:88-92.
12. Mitchell PM, Weisenthal BM, Collinge CA (2017). No incidence of postoperative knee sepsis with suprapatellar nailing of open tibia fractures. *J Orthop Trauma*. 2017; 31:85-9.
13. Garg A, Saini A, Gupta A, Sharma R, Mishra RK (2021). Retrograde Intramedullary Nailing in Femoral Fractures. *Ortho & Rheum Open Access J* 2021; 19(2): OROAJ.MS.ID.556009.
14. Kim JW, Oh CW, Oh JK, Park KH, Kim HJ (2018). Treatment of infraisthmal femoral fracture with an intramedullary nail: Is retrograde nailing a better option than antegrade nailing? *Arch Orthop Trauma Surg* 2018; 138(9):1241-7.
15. Shafiq M, Akram R, Ahmed A, Ullah K, Ahmad I, et.al (2018). Retrograde fémur nail; outcome of retrograde fémur nail, is it implant of choice for distal shaft of fémur fracture? *Professional Med J* 2018; 25(3):364-70.
16. Salphale Y, Mahadeo Shinde G, Rajesh Sharma A, Gadegone P, Mahadeo Gadegone W (2023). Retrograde Intramedullary Interlocking Nailing in Fractures of the Distal Femur: A Review of 20 Cases with an Average Follow Up of One Year. *J Med Res Surg*. 2023; 4(2):27-30.
17. Neubauer Th, Ritter E, Potschka Th, Karlbauer A, Wagner M (2018). Retrograde Nailing of Femoral Fractures. *Acta Chirurgiae Orthopaedicae et Traumatologiae Čechosl*. 2018; 75:158-66. PMID: 18601812
18. Gurkan V, Orhun H, Doganay M, Salioglu F, Ercan T, et.al (2009). Retrograde intramedullary interlocking nailing in fractures of the distal femur. *Acta Orthop Traumatol Turc* 2009; 43(3):199-205.



This work is licensed under Creative Commons Attribution 4.0 License

To Submit Your Article Click Here:

[Submit Manuscript](#)

DOI:10.31579/2694-0248/116

Ready to submit your research? Choose Auctores and benefit from:

- fast, convenient online submission
- rigorous peer review by experienced research in your field
- rapid publication on acceptance
- authors retain copyrights
- unique DOI for all articles
- immediate, unrestricted online access

At Auctores, research is always in progress.

Learn more <https://auctoresonline.org/journals/journal-of-thoracic-disease-and-cardiothoracic-surgery>