

# Gall Bladder Perforation in a 15 days old Infant, an Extremely Rare Case: A Case Report

Ahmad Reza Shahraki

General Surgeon, Assistant professor, Department of Surgery, Medical Faculty, Zahedan University of Medical Sciences and Health Services, Zahedan, Iran.

**\*Corresponding Author:** Ahmad Reza Shahraki, General Surgeon, Assistant professor, Department of Surgery, Medical Faculty, Zahedan University of Medical Sciences and Health Services, Zahedan, Iran.

**Received Date:** 06 September 2024; **Accepted Date:** 13 September 2024; **Published Date:** 20 September 2024

**Citation:** Ahmad R. Shahraki, (2024), Gall Bladder Perforation in a 15 days old Infant, an Extremely Rare Case: A Case Report, *Clinical Medical Reviews and Reports*, 6(6); DOI:10.31579/2690-8794/230

**Copyright:** © 2024, Ahmad Reza Shahraki. This is an open access article distributed under the Creative Commons Attribution License, which permits unrestricted use, distribution, and reproduction in any medium, provided the original work is properly cited.

## Abstract

Neonatal perforated gallbladder is a rare and implausible surgical emergency. Pneumoperitonium and neonatal intestinal obstruction are the main clinical presentations. Many cases of neonatal perforated gallbladder had no clear pathology. Most proper treatment is cholecystectomy during formal exploration. Gallbladder perforation due to cholecystitis is usually seen in the elderly population but is uncommon among the pediatric population. Mortality rate can be as high as 26 % hence early diagnosis is vital. Management is mostly surgical as seen in the index case.

Our case is a 15 days old infants after falling from hand of parents more less 1 meter from earth admit with crying, abdominal sensitivity and Us shows liquids and pneumoperitonium, in laparotomy we find rupture of gall bladder and do cholecystectomy for her, and discharge her healthy.

Although perforated gallbladder is a rare entity and in most of cases does not cause pneumoperitonium, but perforated gallbladder should be taken in account of all cases of pneumoperitonium.

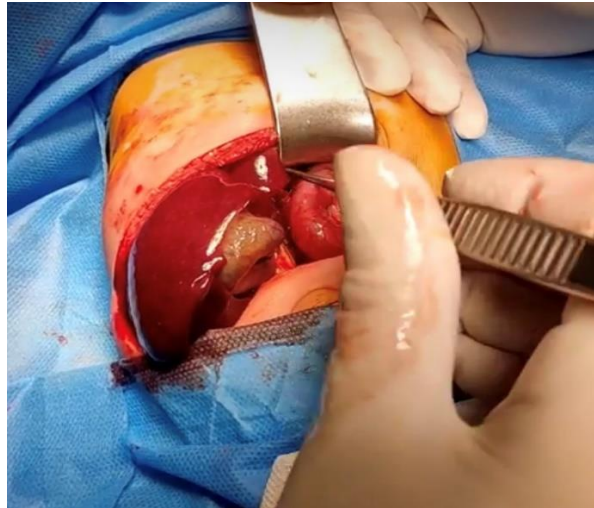
**Keywords:** perforated gallbladder; pneumoperitonium; neonatal jaundice; surgery, infants

## Introduction

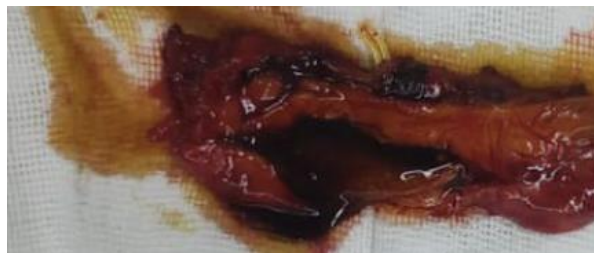Spontaneous bile duct perforation in infants has been reported in the literature; however, gallbladder perforation in infants is extremely rare [2-3]. In the vast majority of cases, the underlying etiology still seems to be unknown, vascular and metabolic compromise were accused on its occurrence [3]. It has insidious presentations in the form of neonatal intestinal obstruction manifestations including billous vomiting, constipation, abdominal distention, abdominal tenderness and pneumoperitonium, making preoperative diagnosis challenging [4]. Perforated gallbladder is also uncommon in adults. It occurs in 2 % to 10 % of adult patients with acute cholecystitis, it could be diagnosed through computerized tomography, and on the other hand in neonates the diagnosis is elusive due to multiplicity of differential diagnosis [5]. With this data we report this case that shows it is a complications of infants.

## Case presentation:

Our case is a 15 days old infants after falling from hand of parents more less 1 meter from earth one hours before and admit with crying, abdominal sensitivity , nausea and vomiting . We start lab data and Us perform for her that shows liquids and pneumoperitonium,in abdomen. Laparotomy planed for her (figure1) we check liver,spleen,stomach and bowels and finally we find rupture of gall bladder(figure2) and do cholecystectomy (Figure2) for her, After surgery we observe her and after2 days she starts water and then milk eating and discharge her healthy after3 days.



**Figure 1:** Laparotomy



**Figure 2:** Perforated gall bladder

### Discussion:

Rupture of the bladder is extremely rare in the newborns. Neonatal gallbladder perforation is rare, just 1.5 neonates every 1,000,000 live births [6-7]. The fundus is the least vascularized area supplied by blood, so it is the most susceptible area in the gallbladder to perforation [8]. Niemeier classified perforation in gallbladder into three categories in 1934: type I, acute perforation in the free peritoneal cavity which agreed with reported case; type II, subacute perforation with abscess formation; and type III, chronic perforation with fistula formation between the gallbladder and other organs [9-10]. Open cholecystectomy is the treatment of choice in this condition where some surgeons preferred a tube cholecystostomy [11-12]. Surgical exploration and cholecystectomy was done in this case with no intraoperative complications [13-14]. Gallbladder perforation due to cholecystitis is usually seen in the elderly population but is uncommon among the pediatric population. Mortality rate can be as high as 26 % hence early diagnosis is vital. Management is mostly surgical as seen in the index case [15]. Traumatic gallbladder perforations are exceeding rare and consist of only 1.9 to 2 % of all abdominal traumas [16-17]. The diagnosis is made through the clinical presentation, with patients presenting with localized or diffuse abdominal pain owing to biliary peritonitis and often diagnosed intra-operatively as seen in our case and most cases of GBP published [18]. Imaging modalities include USS and abdominal CT scans which are more sensitive as confirmed in the index case. More recently, contrast-enhanced ultrasound (CEUS) has been developed with a diagnostic accuracy for detecting solid organ injuries comparable to that of CT-scans, and has the capability of giving a more detailed description of traumatic cases [16]. Other modalities include Magnetic Resonance Cholangiopancreatography (MRCP) and drip-infusion cholangiography (DIC-CT) depending on the availability. Most cases are managed according to the cause, mostly through a surgical approach than conservative as a means of clearing the biliary peritonitis as well as cholecystectomy as seen in our case. Moving forward in medicine, the use of artificial intelligence (AI) will aid clinicians to detect pathologies more accurately and hence come up with an accurate diagnosis, therefore, avoiding delays in management. Currently, the use of robotic

surgery is rising to perform surgeries like cholecystectomy and microsurgery. This benefits both surgeons and patients, however, challenges include projecting an overlay on markerless deformable organs and tissue deformation therefore sensors and algorithms need to be advanced and updated regularly [19]. Patients diagnosed with acalculous cholecystitis can be managed conservatively with analgesics and antibiotics and close monitoring of clinical symptoms and signs [20].

### Conclusion:

Neonatal perforated gallbladder is a rare and implausible surgical emergency. Pneumoperitonium and neonatal intestinal obstruction are the main clinical presentations. Many cases of neonatal perforated gallbladder had no clear pathology. Most proper treatment is cholecystectomy during formal exploration [1]. Gallbladder perforation although rare, but a life-threatening clinical condition with high mortality and should always be suspected in patients with acute abdomen, early diagnosis via imaging modalities and early management prompted to reduce ongoing morbidity and enhance recovery [15].

### Highlights:

- The proportion of occurrence of gallbladder perforation is very rare
- No specific pathology is cause of perforation of gallbladder
- Pneumoperitonium is one of most important signs of gallbladder perforation.
- Gallbladder perforation is classified into three types according the site of perforation.
- Surgical excision of gallbladder is most proper surgical option in perforated gallbladder.

### Declarations:

Ethical Approval and Consent to participate:

The content of this manuscript are in accordance with the declaration of Helsinki for Ethics. No committee approval was required. Oral and written consent to participate was granted by her parents.

### Consent for publication:

“Written informed consent was obtained from the patient's legal guardian for publication of this case report and any accompanying images. A copy of the written consent is available for review by the Editor-in-Chief of this journal.”

### - Availability of supporting data

It is available.

- Competing interests:

The author declares that they have no competing financial interests and nothing to disclose.

### - Funding: There is no funding.

### - Authors' contributions:

Ahmad Reza Shahraki is the surgeon of patient and writes this paper.

The author declares that they have no competing financial interests and nothing to disclose.

### - Acknowledgements:

Neonatal perforated gallbladder is a rare and implausible surgical emergency. Pneumoperitonium and neonatal intestinal obstruction are the main clinical presentations. Many cases of neonatal perforated gallbladder had no clear pathology. Most proper treatment is cholecystectomy during formal exploration. Gallbladder perforation although rare, but a life-threatening clinical condition with high mortality and should always be suspected in patients with acute abdomen, early diagnosis via imaging modalities and early management prompted to reduce ongoing morbidity and enhance recovery.

### References:

1. Takrouney MH, Abdelmohsen SM, Ali AK, Osman MA, Ibrahim IA (2023). Perforated gallbladder in neonates with review of literature. *Int J Surg Case Rep.* 2023 Jul;108:108363.
2. Jeniga Shravya K., Reddy Ramesh Kumar, Krishnamurthy Brig P., Prabhakar V (2022). A rare case of gall bladder perforation in a neonate resulting in pericholecystic abscess secondary to biliary calculi. *Int. J. Sci. Res. Publ.* October 2022;11(10):883–886.
3. Tavakoli Iran, Bigam David, Sergi Consolato, Dicken Bryan (2019). Spontaneous perinatal gallbladder perforation. *J Pediatr Surg Case Rep.* 2019;46
4. Ying-Yi Lu, Hong-Shiee Lai, Wu-Shiun Hsieh, Wen-Ming Hsu (2008). Ischemic gallbladder perforation in a premature infant. *J. Pediatr. Surg.* 2008;43(6): E31–E32.

5. Rhoads K., Snyder J., Lee H (2002). Cholelithiasis and perforated gallbladder in an infant. *J. Pediatr. Surg.* 2002 Sep;37(9):1374–1375.
6. Suleman Mujaheed, Sadiq Adnan, Amsi Patrick, Lodhia Jay (2022). Gallbladder perforation: an uncommon cause of peritonitis in a child. *Int. J. Surg. Case Rep.* 2022;100
7. Reyna-Sepúlveda F., Esparza-González A., Govea-Ortiz V., Martínez-Flores G., Montes-Tapia F., et.al (2016). Neonatal spontaneous biliary perforation: case report. *Med. Univ.* 2016;18(72):163–164.
8. Estevão-Costa J., Soares-Oliveira M., Lopes J.M., Carvalho J.L (2002). Idiopathic perforation of the gallbladder: a novel differential diagnosis of acute abdomen. *J. Pediatr. Gastroenterol. Nutr.* 2002 Jul;35(1):88–89.
9. Date Avindra S., Thrumurthy Sri G., Whiteside Sigrid, Umer Mohammed A., Pursnani Kishore G., et.al (2012). Gallbladder perforation: case series and systematic review. *Int. J. Surg.* 2012;10(2):63–68.
10. Niemeier O.W (1934). Acute free perforation of the gall-bladder. *Ann. Surg.* 1934 Jun;99(6):922–924.
11. Sheets N.W., Maxwell D (2015). Spontaneous gallbladder perforation in a preterm neonate. *J. Pediatr. Neonatal Care.* 2015;2(4):00081.
12. Nambirajan L., Chandrasekharam V.V., Gupta A.K., Bhatnagar V (2000). Spontaneous neonatal gall bladder perforation. *Trop. Gastroenterol.* 2000 Oct-Dec;21(4):190–191.
13. Naik Ajay Madhukar, Makan Apoorva (2018). Spontaneous idiopathic perforation of gall bladder in neonates. *Glob. J. Res. Anal.* 2018 (n. pag).
14. Ying-Yi Lu, Hong-Shiee Lai, Wu-Shiun Hsieh, Wen-Ming Hsu (2008). Ischemic gallbladder perforation in a premature infant. *J. Pediatr. Surg.* 2008;43(6):E31–E32.
15. Suleman M, Sadiq A, Amsi P, Lodhia J (2022). Gallbladder perforation: An uncommon cause of peritonitis in a child. *Int J Surg Case Rep.* 2022 Nov;100:107765.
16. Le MT Herrmann J., Groth M., Reinshagen K., Boettcher M (2021). Traumatic Gallbladder Perforation in Children—Case Report and Review. In *RöFo-Fortschritte auf dem Gebiet der Röntgenstrahlen und der bildgebenden Verfahren.* 2021 Aug;193(08):889–897. *Georg Thieme Verlag KG.*
17. Balde F.B., Mukengue T., Oualili I., Benmassaoud Z., Khatalla K.(2020). Post-traumatic gallbladder injury in children: case rapport. *Open Journal of Pediatrics.* 2020 Jul 7;10(3):570–575.
18. Badru F., Litton T., Puckett Y., Bansal S., Guzman M., et. al (2016). Spontaneous gallbladder perforation in a child secondary to a gallbladder cyst: a rare presentation and review of literature. *Pediatr. Surg. Int.* 2016 Jun;32(6):629–634.
19. Taher H., Grasso V., Tawfik S., Gumbs A (2022). The challenges of deep learning in artificial intelligence and autonomous actions in surgery: a literature review. *Artificial Intelligence Surgery.* 2022 Sep 23;2(3):144–158.
20. Hamid R., Zackria R., Sharma J.S (2021). A curious case of acute acalculous cholecystitis. *Cureus.* 2021 May 10;13(5).



This work is licensed under Creative Commons Attribution 4.0 License

To Submit Your Article Click Here:

**Submit Manuscript**

DOI: [10.31579/2690-8794/223](https://doi.org/10.31579/2690-8794/223)

**Ready to submit your research? Choose Auctores and benefit from:**

- fast, convenient online submission
- rigorous peer review by experienced research in your field
- rapid publication on acceptance
- authors retain copyrights
- unique DOI for all articles
- immediate, unrestricted online access

At Auctores, research is always in progress.

Learn more <https://auctoresonline.org/journals/clinical-medical-reviews-and-reports>