

Xanthogranulomatous Cholecystitis with Gallstones: A Case Report

Imane BOUJGUENNA ^{1*}, Hichame Krimou ², Fatima BOUKIS ³

¹Guelmim Faculty of Medicine and Pharmacy - Ibnou Zohr Agadir University.

²Guelmim Military Hospital Moulay El Hassan General Surgery Department.

³Al AMAL Pathological Anatomy Laboratory, Guelmim.

*Corresponding Author: Imane BOUJGUENNA. Guelmim Faculty of Medicine and Pharmacy - Ibnou Zohr Agadir University.

Received date: December 06, 2024; Accepted date: December 12, 2024; Published date: December 17, 2024

Citation: Imane BOUJGUENNA, Hichame Krimou, Fatima BOUKIS, (2024), Xanthogranulomatous Cholecystitis with Gallstones: A Case Report, *J Cancer Research and Cellular Therapeutics*, 8(9); DOI:10.31579/2640-1053/224

Copyright: © 2024, Imane BOUJGUENNA. This is an open access article distributed under the Creative Commons Attribution License, which permits unrestricted use, distribution, and reproduction in any medium, provided the original work is properly cited.

Abstract :

Xanthogranulomatous cholecystitis (XGC) is a rare, destructive inflammatory disease of the gallbladder, considered a variant of chronic cholecystitis. Its prevalence ranges from less than 1% to 9%. XGC is often mistaken for gallbladder carcinoma prior to histological analysis. We report a case of a 69-year-old patient presenting with chronic hepatic colic, diagnosed with lithiasic xanthogranulomatous cholecystitis confirmed by histopathological examination.

Keywords: Xanthogranulomatous cholecystitis; gallstones; chronic cholecystitis; histopathology; differential diagnosis

Introduction:

Xanthogranulomatous cholecystitis (XGC) is a rare, destructive inflammatory disease of the gallbladder, considered a variant of chronic cholecystitis. Its prevalence varies between less than 1% and 9% (1). XGC is an aggressive form of chronic cholecystitis, often mistaken for gallbladder carcinoma before histological examination.

Case Report:

A 69-year-old male patient, with no significant medical history, presented with chronic hepatic colic persisting for several months. Physical examination revealed a lithiasic gallbladder. A cholecystectomy was performed. Microscopic examination showed a gallbladder measuring 6 cm in length and 2.6 cm in width at the fundus. The wall was thickened but supple. Upon opening, the mucosal surface was extensively abraded with the presence of gallstones. Microscopic analysis revealed a hypertrophic gallbladder wall. The surface epithelial lining was largely ulcerated and replaced by polymorphic granulation tissue composed of lymphocytes, plasma cells, numerous foamy histiocytes, and multinucleated giant cells of the Müller type, with the presence of neutrophils indicating an acute phase. This inflammatory infiltrate was pan-parietal with areas of fibrosis (Figures 1, 2, and 3). The final diagnosis was lithiasic xanthogranulomatous cholecystitis in the acute phase without signs of malignancy. Postoperative recovery was uneventful.

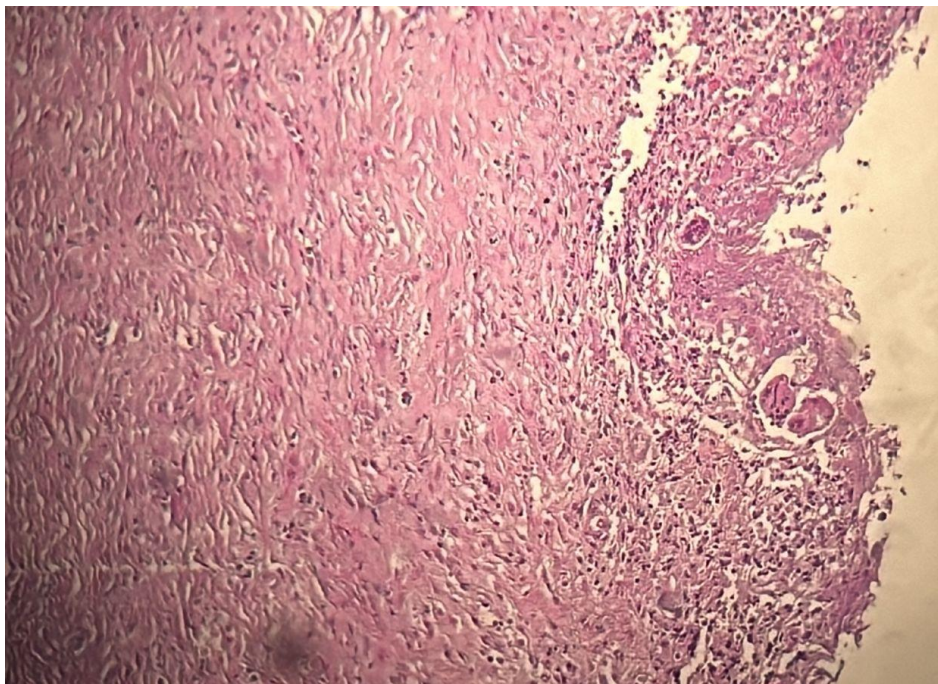


Figure 1: Surface epithelial lining was largely ulcerated and replaced by polymorphic granulation

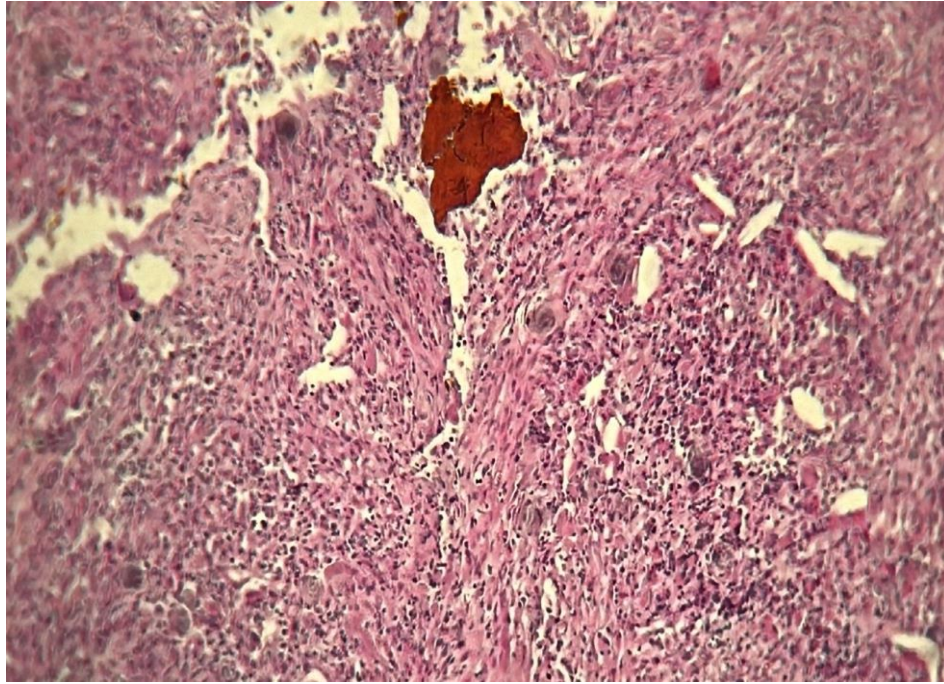


Figure 2 : Polymorphic granulation

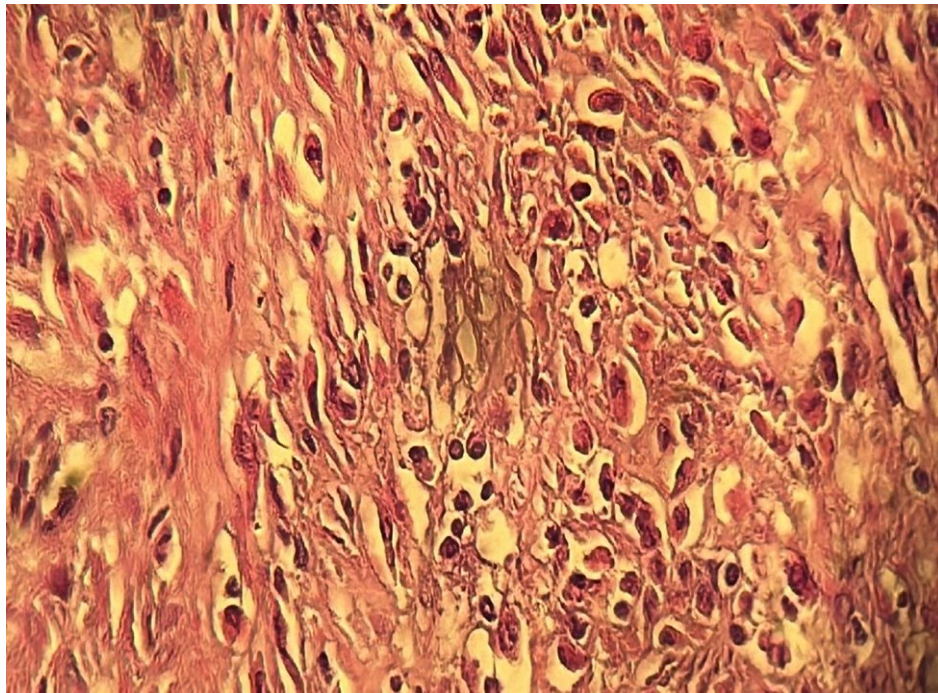


Figure 3 : Histiocytes in the gallbladder wall and fibrosis

Discussion:

Xanthogranulomatous cholecystitis is a rare variant of chronic cholecystitis. XGC is a benign but sometimes aggressive disease resulting from chronic inflammation of the gallbladder wall. Its prevalence ranges from 1% to 9%. It typically occurs in individuals over 50 years of age, with no sex predilection [1-4]. Clinically, it presents with signs of chronic or acute cholecystitis. Ultrasound imaging shows diffuse thickening of the gallbladder wall, intramural hypoechoic nodules, an indistinct liver-gallbladder interface, and the presence of gallstones in most cases. Similar findings are observed on CT and MRI, with involvement of surrounding structures [5-7]. The main differential diagnosis at this stage is neoplastic pathology. Histologically, there is the presence of xanthogranulomas with foamy histiocytes in the gallbladder wall and fibrosis without signs of malignancy. Histological differential diagnoses include gallbladder adenocarcinoma with signet ring cells, marked by anti-cytokeratin antibodies, and malakoplakia, characterized by histiocytes with Michaelis-Gutmann bodies positive on PAS and von Kossa special stains [8-10].

Conclusion:

Xanthogranulomatous cholecystitis is a rare benign condition that can be mistaken for neoplastic pathology. Definitive diagnosis is histological, and optimal management relies on anatomic-clinical correlation.

Ethics approval and consent to participate

Yes

Consent for publication

Yes

Availability of data and material

Data availability.

Competing interests

The authors declare no conflicts of interest.

Funding

No funding

Authors' contributions

All the authors contributed to the conduct of this work.

Acknowledgments

To anyone who has participated in the care of this patient directly or indirectly

References:

1. Christensen AH, Ishak KG. (1970), Benign tumors and pseudotumors of the gallbladder: report of 180 cases. *Arch Pathol*; 90:423-432.
2. Takahashi K, Oka K, Hakoziaki H, Kojima M. (1976), Ceroidlike histiocytic granulomas of gallbladder. A previously undescribed lesion. *Acta Pathol Jpn*; 26:25-46.
3. Mehrotra ML, Bhatnagai BNS. (1982), Biliary granulomatous cholecystitis. *J Indian Med Assoc* ; 79:144-145.
4. McCoy JJ, Vila R, Petrossian G, McCall RA, Reddy KS. (1976), Xanthogranulomatous cholecystitis: report of two cases. *J S C Med Assoc*; 72:78-79.
5. Goodman ZD, Ishak KG. (1981), Xanthogranulomatous cholecystitis. *Am J Surg Pathol*; 5: 653-659.
6. Roberts KM, Parsons MA. (1987), Xanthogranulomatous cholecystitis: clinicopathological study of 13 cases. *J Clin Pathol*; 40:412-417.
7. [Hanada Y, Hajime N, Takashi N et al. \(1987\). Résultats radiologiques dans la cholécystite xanthogranulomateuse. AJR Am J Roentgenol.; 148: 727-730.](#)
8. [Parra JA, Acinas O, Bueno J et al. \(2000\). Cholécystite xanthogranulomateuse: résultats cliniques, échographiques et tomographiques chez 26 patients. AJR Am J Roentgenol.; 174 : 979-983.](#)
9. Bebow EW. (1989), Xanthogranulomatous cholecystitis associated with carcinoma of gallbladder. *Postgrad Med J*; 65:528-531.
10. Albores-Saavedra J, Alcantra-Vazquez A, Cruz-Ortiz H, Herrera-Goepfert R. (1980), The precursor lesions of invasive gallbladder carcinoma. Hyperplasia, atypical hyperplasia and carcinoma in situ. *Cancer*; 45:919-927.