

Forrest Mastectomy and immediate Reconstruction Through Latissimus Dorsi Flap with Breast Implants and Contralateral Simetrization

Juan Ricciardi V^{1*}, Nilyan Rincón², Otto González³, Carianda Ramírez⁴, Natalia Solórzano⁵, Rebeca Cadena⁶, Holbert Torres⁷

¹Cirujano General. Residente de Cirugía Plástica y Reconstructiva, Servicio Oncológico Hospitalario Padre Machado Caracas. Venezuela.

²Cirujano Plástico y Reconstructivo, Jefe de Servicio de Cirugía Plástica y Reconstructiva del Servicio Oncológico Hospitalario Padre Machado Caracas. Venezuela.

^{3,4,5,6}Cirujano Plástico y Reconstructivo, Cirujano Oncoplástico, Servicio Oncológico Hospitalario Padre Machado Caracas. Venezuela.

⁷Cirujano Plástico y Reconstructivo, Fellow Cirugía Oncoplástica, Servicio Oncológico Hospitalario Padre Machado Caracas. Venezuela.

***Corresponding Author:** Juan Ricciardi V., Cirujano General. Residente de Cirugía Plástica y Reconstructiva, Servicio Oncológico Hospitalario Padre Machado Caracas. Venezuela.

Received Date: 02 September, 2024 | **Accepted Date:** 19 September, 2024 | **Published Date:** 01 October, 2024

Citation: Juan Ricciardi V, Nilyan Rincón, Otto González, Carianda Ramírez, Natalia Solórzano, et al, (2024) Forrest Mastectomy and in mediate Reconstruction Trough Latissimus Dorsi Flap with Breast Implants and Contralateral Simetrization, *Journal of Clinical Surgery and Research*, 5(7); DOI:10.31579/2768-2757/138

Copyright: © 2024, Juan Ricciardi V. This is an open access article distributed under the Creative Commons Attribution License, which permits unrestricted use, distribution, and reproduction in any medium, provided the original work is properly cited.

Abstract:

The demand for breast reconstruction is increasing constantly, which leads plastic surgeons to look for new methods to obtain a more natural and aesthetically pleasing appearance of the reconstructed breasts. The latissimus dorsi (LD) muscle has been adopted as one of the workhorse flaps for breast reconstruction.

Objective: Report a breast immediate reconstruction through a latissimus dorsi muscle flap with breast implants and contralateral simetrization.

Clinical Case: 47 years old female with a right ductal invasive breast carcinoma with a partial oncological response after neoadjuvant treatment and Forrest total right mastectomy and immediate reconstruction by the Plastic and Reconstructive service using a hybrid technique.

Discussion And Conclusion: Among all the surgical methods, modified mastectomy is adopted most commonly in China; however, it has been found to have negative psychological effects on women's emotion and affects their quality of life. The latissimus dorsi (LD) flap is a commonly used technique in reconstructive surgery. It is an autologous tissue that can cover a large area, for defects due to trauma, wide excision, or tumors. It is one of the most commonly used flaps in reconstruction of small to moderate breast volumes. The latissimus dorsi muscle flap with breast implants and contralateral simetrization are both an excellent reconstructive alternative to the breast reconstruction after Forrest mastectomy defects in the same surgical time.

keywords: latissimus dorsi; reconstructive breast surgery; hybrid reconstruction

Introduction

Breast cancer is the most common malignancy in women, with a global incidence of 2,088,849 new cases and 626,679 related deaths reported in 2018 [1] and according to the American Cancer Society, about 2,710 new cases of invasive breast cancer will be diagnosed in the United States in 2022. [2] The percentage of U.S. women who opted to undergo breast reconstruction after breast cancer was estimated at 43.3% based on data from NSQIP 2014. [1] The latissimus dorsi (LD) muscle has been adopted by plastic surgeons as one of the workhorse flaps for breast

reconstruction. Its use was first described by Iginio Tansini in 1896 as a cutaneous flap to cover a defect secondary to breast cancer surgery. He then renewed the procedure to incorporate the LD muscle in the flap in 1906. [3] Its resurgence has been attributed to its ability to be enhanced using implant or high-volume fat grafting, rendering it a primary option for selected patients. [3] In some cases, adjuvant lipofilling is performed after tissue expansion or at the time of expander/implant substitution, but also in autologous breast reconstruction [4]

Case Report

Female 47 years old, without oncological antecedents, who reports the beginning of current illness 14 months earlier characterized by self-detected nodular mammary lesion between the upper mammary quadrants (12 o'clock) of the right breast with irregular edges, 5 x 4 cm non-mobile and attached to deep planes, so she went to a medical consultation where they request a mammography and bilateral breast ultrasound with a core needle biopsy who reports a ductal invasive breast carcinoma, immunohistochemistry reports Her2/neu (+++) so after the adequate stadification process she went first to a neoadjuvant treatment with a partial oncological response (50% lower lesion) and after that appropriate elective surgery was planned at the "Padre Machado" Oncological Hospitalary Service. Therefore, under general anesthesia, on the first surgical time the Breast surgery service it performs a right Forrest total mastectomy, on a second time immediate reconstruction by the Plastic and Reconstructive service through a latissimus dorsi flap with breast implants and contralateral simetrization using a superior pedicle mastopexy. Adequate postoperative functional and aesthetic results and continue follow up with an Oncology and Breast Surgery service.

Discussion

Breast cancer is the most common malignancy for women. The treatment of choice for early-stage breast cancer is surgery. (5) Among all the surgical methods, modified mastectomy is adopted most commonly in China; however, it has been found to have negative psychological effects on women's emotion and affects their quality of life. Therefore, it is vital to consider other surgical approaches such as breast reconstruction and oncoplastic conservation surgery. [6]

The latissimus dorsi (LD) flap is a commonly used technique in reconstructive surgery. It is an autologous tissue that can cover a large area, for defects due to trauma, wide excision, or tumors. [7] It is one of the most commonly used flaps in reconstruction of small to moderate breast volumes [8]

According to Sood R, Easow J, et al; [9] there are several specific indications for the latissimus dorsi flap (LDF). For autogenous breast cancer reconstruction, the LDF is first line for patients who are not candidates for the TRAM flap, due to previous abdominoplasty, prior TRAM, insufficient abdominal skin or fat, and high-risk comorbidities

such as diabetes, obesity, or tobacco use. [9] Having relation with our case, because the patient had an abdominal hysterectomy antecedent by huge uterine myomas treatment.

In the other hand, according the skin pattern design of the island flap, the work of Ho Lee J, Yeop Ryu J, et al [7] describe that the vertical latissimus dorsi flap is applicable in all partial breast reconstructions, regardless of the region of defect. It also showed a statistically significant decrease in admission and operation times with higher patient satisfaction than the mini-LD flap technique, however have not relation with the latissimus dorsi technique of our case because was made with a classic pattern after a total mastectomy instead a partial one.

According Lu Li, Yue Yang, Wang Li et al [10] neoadjuvant chemotherapy is an accepted treatment option for patients with locally advanced breast cancer, and the use of a latissimus dorsi musculocutaneous flap for post-mastectomy reconstruction may improve the patients' physical condition, having a strong relation with our case because the patient went to neoadjuvant treatment before the total mastectomy and the immediate reconstruction through the latissimus dorsi flap.

The demand for breast reconstruction is increasing constantly, which leads plastic surgeons to look for new methods to obtain a more natural and aesthetically pleasing appearance of the reconstructed breasts. For example, the work of Xun Ma J, Bi Li [11] describe a Latissimus dorsi muscle flap transfer through endoscopic approach combined with the implant after tissue expansion for breast reconstruction of mastectomy patients could effectively reduce visible scars, avoid the patch effect, while require short time for latissimus dorsi flap muscle harvest and present low incidence of complications. However, requires a huge aparatology, well trained center and training on minimal invasive reconstructive experience, a fact that have not relation yet in our country where we need to extend the plastic and reconstructive surgery programs in order to can learn and develop these complex techniques.

Conclusion

The latissimus dorsi muscle flap with breast implants and contralateral simetrization are both an excellent reconstructive alternative to the breast reconstruction after Forrest mastectomy defects in the same surgical time.

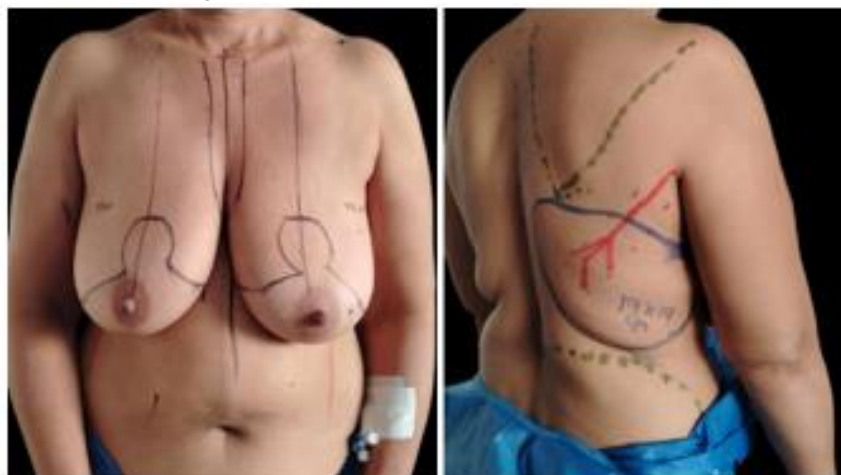


Figure 1.2: 1. Mastopexy bilateral pattern with a superior pedicle at the contralateral breast.
2. Latissimus dorsi muscle flap preoperative design.

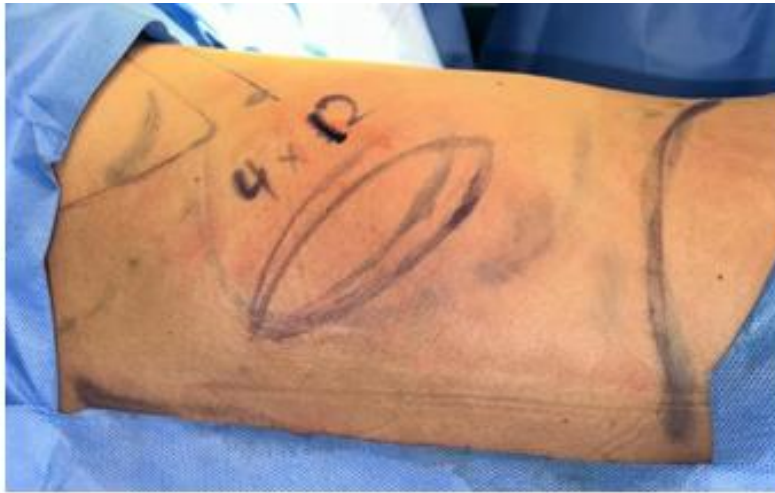

Figure 3. New LDMF design with the patient in left lateral position at the operation room.

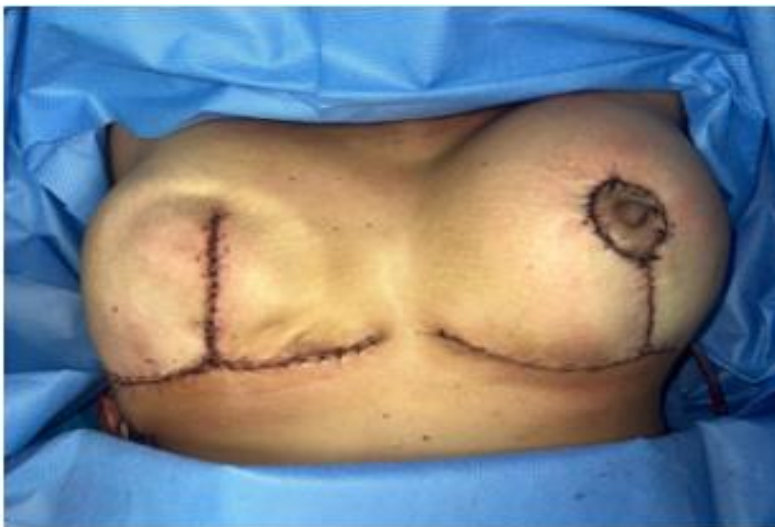

Figure 5. Result of the immediate right breast reconstruction through the latissimus dorsi muscle flap with breast implants and superior pedicle Mastopexy contralateral simetrization.

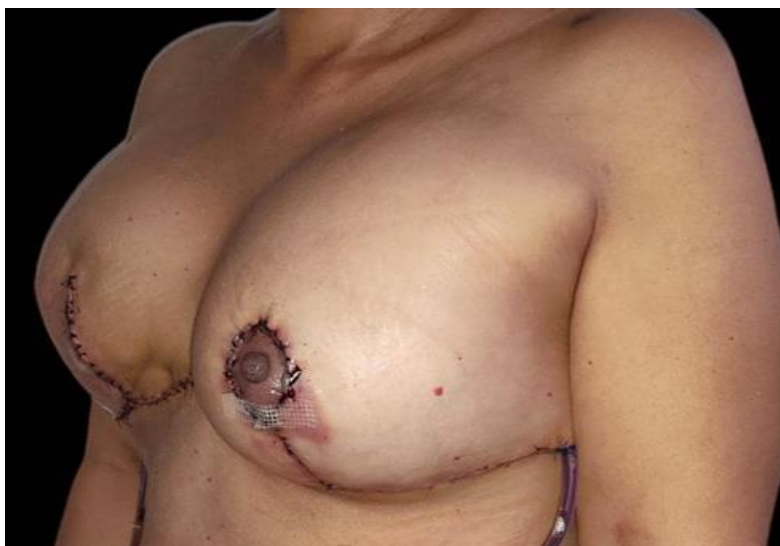

Figure 6: Result of the immediate right breast reconstruction through the latissimus dorsi muscle flap with breast implants and superior pedicle Mastopexy contralateral simetrization.

Acknowledgments

Plastic, Reconstructive and Oncoplastic Surgeons of the SOH Padre Machado, Caracas, Venezuela.

Conflicts of Interest

The author declare no conflicts of interest.

Ethical Approval

This research complies with the World Medical Association Declaration of Helsinki on medical protocols and ethics.

Reference

1. Bonetti A, Carbonaro R, Borelli F et al. (2022) Outcomes in Hybrid Breast Reconstruction: A Systematic Review; *Medicina*, 58, 1232;
2. Deldar R, Sayyed A, Towfighi P et al. (2022). Postmastectomy Reconstruction in Male Breast Cancer; *Breast J*: 2022:548226.
3. Escandón J, Manrique O, Christiano J et al. (2023). Breast reconstruction with latissimus dorsi flap: a comprehensive review and case series; *Ann Transl Med*;11(10):355.
4. Herly M, Ørholt M, Larsen A et al. (2018). Efficacy of breast reconstruction with fat grafting: A systematic review and meta-analysis. *J. Plast. Reconstr. Aesthet. Surg*, 71, 1740–1750.
5. Siegel R, Miller K, Jemal A. Clin. (2018). Cancer Statistics; *CA Cancer J*. 68:7–30.
6. Zheng H, Zhu G, Guan Q et al; (2021). A Retrospective Study of Latissimus Dorsi Flap in Immediate Breast Reconstruction. *Front. Oncol*. 11:598604.
7. Ho Lee J, Yeop Ryu J, Young Choi K et al. (2022). Useful vertical latissimus dorsi flap for partial breast reconstruction in every tumor location; *BMC Surgery*. 22:294.
8. Chang D, Youssef A, Cha S et al. (2002). Autologous breast reconstruction with the extended latissimus dorsi flap; *Plast Reconstr Surg*; 110:751–759.
9. Sood R, Easow J, Konopka G et al (2018). Latissimus Dorsi Flap in Breast Reconstruction: Recent Innovations in the Workhorse Flap; *Cancer Control*.
10. Lu Li, Yue Yang, Wang Li et al. (2022). Latissimus dorsi myocutaneous flap repair is effective after neoadjuvant chemotherapy for locally advanced breast cancer; *World Journal of Surgical Oncology*; 20:134
11. Xun Ma J, Bi Li, You Chen X et al. (2022). Latissimus dorsi muscle flap transfer through endoscopic approach combined with the implant after tissue expansion for breast reconstruction of mastectomy patients; *BMC Surgery*; 22:10



This work is licensed under Creative Commons Attribution 4.0 License

To Submit Your Article Click Here:

Submit Manuscript

DOI:10.31579/2768-2757/138

Ready to submit your research? Choose Auctores and benefit from:

- fast, convenient online submission
- rigorous peer review by experienced research in your field
- rapid publication on acceptance
- authors retain copyrights
- unique DOI for all articles
- immediate, unrestricted online access

At Auctores, research is always in progress.

Learn more <https://www.auctoresonline.org/journals/journal-of-clinical-surgery-and-research>