

# Yasser's Sphygmomanometer Procedure; a Newly Therapeutic Procedure for the Psychogenic Hemiplegia in the Emergency Medicine and Neuropsychiatry-Case Series

Yasser Mohammed Hassanain Elsayed<sup>1\*</sup>

Critical Care Unit, Kafr El-Bateekh Central Hospital, Damietta, Egyptian Ministry of Health (MOH), Egypt.

\***Corresponding Author:** Yasser Mohammed Hassanain Elsayed., Critical Care Unit, Kafr El-Bateekh Central Hospital, Damietta, Egyptian Ministry of Health (MOH), Egypt.

**Received Date:** November 01, 2024 | **Accepted Date:** November 15, 2024 | **Published Date:** December 02, 2024

**Citation:** Yasser M H Elsayed., (2024). Yasser's Sphygmomanometer Procedure; a Newly Therapeutic Procedure for the Psychogenic Hemiplegia in the Emergency Medicine and Neuropsychiatry-Case Series., *Journal of Clinical and Laboratory Research* 7(9); **DOI:**10.31579/2768-0487/155

**Copyright:** © 2024, Yasser Mohammed Hassanain Elsayed. This is an open-access article distributed under the terms of the Creative Commons Attribution License, which permits unrestricted use, distribution, and reproduction in any medium, provided the original author and source are credited.

## Abstract

**Introduction:** Psychogenic hemiplegia is a suggestive symptom of stroke but in reality, is of psychogenic origin. Psychogenic hemiplegia is an identical subgroup of pseudostroke, and psychogenic movement disorders, and mimics for differential diagnosis of stroke. Treatment of psychogenic hemiplegia is still challenging.

**The research objectives** aimed to evaluate the hypothesis that Yasser's sphygmomanometer procedure can regain movement and improvement of psychogenic hemiplegia.

**Method of study and patients:** The study was technical, prospective, observational, and interventional for 31 cases. This study was conducted in Kafr El-Bateekh Central Hospital, Fraskour Central Hospital, and a physician outpatient clinic. The author reported 31 cases of psychogenic hemiplegia over nearly 5 years and 3 months, starting on May 07, 2019, and, ending on August 12, 2024.

**Results:** A total of 31 patients are included in this study. There is a female sex predominance of 87.1%. The mean age of the cases was 35.29 years (range; 16-65). The most common occupation in the study was housewife; 54.84%. The most commonly associated hemiplegia was the left-side hemiplegia of cases; 90.32% vs. right-side; 6.45% and reversal; 3.23%. Latent tetany was the most predominant; 90.32% vs. the manifested; 9.68%. Wavy triple sign (WTS) was the most frequent ECG sign; 35.48%, then Wavy double sign (WDS); 22.58%, and combined WTS and WTS; 16.13%, WTS with Tee-Pee sign and Camel hump T-waves; 6.45%. Ionized hypocalcemia was detected in 32.26%. The response was complete but with a single recurrence.

**Conclusions:** The author concluded that Yasser's sphygmomanometer procedure is easy, available, quick, non-costive, time-saving, and extremely safe for psychogenic hemiplegia. There is a strong association between hypocalcemia (clinical, ECG, and ionized hypocalcemia) and psychogenic hemiplegia. There were no reported complications for this procedure encouraging the generalizing use in psychogenic hemiplegia. Further widening the research to include the cases of organic stroke is essential.

**Keywords:** psychogenic hemiplegia; regaining the movement; mimics; pseudostroke; psychogenic movement disorders; conversion disorder; motor functional neurological disorder

## Abbreviations

Ca<sup>++</sup>: Calcium

CHTW: Camel hump T-waves

ED: Emergency department

ECG: Electrocardiography

EEG: Electroencephalography

FND: Functional neurological disorder

GCS: Glasgow Coma Scale

HR: Heart rate

ICU: Intensive care unit

IHD: Ischemic heart disease

NSR: Normal sinus rhythm

O<sub>2</sub>: Oxygen

PMD: Psychogenic Movement Disorders

POC: Physician outpatient clinic

PS: Pseudostroke

PVCs: Premature ventricular complexes

TPS: Tee-Pee sign

WDS; Wavy double sign

WTS: Wavy triple sign

## **1. Introduction**

### **Psychogenic hemiplegia**

#### **1.1 Introduction and Significance**

Stroke is one of the most common diseases affecting 25% of people during their lifetime [1]. Most strokes are ischemic due to a reduction or interruption of blood flow (BF) to the brain. Approximately, 20–30% of strokes are hemorrhagic and result from damage to small or medium-size vessels [1]. Stroke is a medical emergency that presents with focal neurological deficits. Rapid assessment, confirmation of diagnosis, and treatment to re-establish BF leads to improvement in symptoms and prevention of brain damage [2].

#### **1.2 Mimics of Stroke and Psychogenic Pseudostroke are Included**

Mimics is about 25% of hospital admissions for suspected stroke [3]. The prevalence of stroke mimics is variable and depends on the focal diagnosis. It can be 20–50% of cases of acute suspected stroke depending on if the patients were assessed by the emergency or stroke physicians [4–6]. Psychogenic pseudostroke (PS) is a suggestive symptom of a stroke, but in reality, of psychogenic origin [7]. However, specific information regarding its management is deficient [7].

#### **1.3 Psychogenic Movement Disorders and Conversion Disorders are implicated**

Psychogenic Movement Disorders (PMD) are one of the most challenging neuropsychiatric disorders for both neurologists and psychiatrists. PMD has confounded the specialists of both these disciplines, time and again, over more than a century. These disorders cannot be fully accounted for by any known organic syndrome and have significant psychological and or psychiatric contributions [8]. The psychogenic neurological disorders include psychogenic hemiplegia, paraplegia, blindness, seizures, pain syndromes, a variety of movement disorders, and PMD. The latter include hyperkinetic syndromes of tremors, jerks, spasms (dystonias), gait disorders, and a hypokinetic extrapyramidal syndrome mimicking Parkinsonism [8]. Conversion disorder is an unconscious psychological response to a stressful situation [9,10].

#### **1.4 Prevalence in Mimics of Stroke and Pseudostroke**

Psychogenic symptoms reported in virtually all medicine specialties. Approximately 33% of outpatient's neurologic symptoms as being “nonorganic”. Most neurologists have encountered a case of such nature [7]. However, little information exists on psychogenic pseudostroke (PS). However, specific information regarding its prevalence, epidemiology, demographics, and psychopathology of PS is scarce [7]. The exact prevalence or incidence of PMD is idiopathic [8].

#### **1.5 Somatoform Disorders, Factitious Disorders, and Malingering in Differentiation**

According to the (DSM-IV-TR), physical symptoms due to psychological causes fall under three classes: somatoform disorders, factitious disorders, and malingering. Somatoform disorders, factitious disorders, and malingering fall among the most difficult differentiating issues for neuropsychologists [11]. It is essential to entertain stroke mimics in the differential diagnosis when treating an acute suspected stroke to avoid the inappropriate use of expensive and potentially harmful medications. This becomes particularly important with telestroke and hospitals with limited acute stroke experience [4]. The differential diagnosis of conversion disorder includes strokes, multiple sclerosis, and epilepsy [9,10]. Younger, females are commoner than males, altered level of consciousness, gradual in onset, fluctuations in severity, no vascular distribution, blood pressure usually not increased, sensory, vertigo (or dizziness) and visual, may have involuntary movements, unilateral facial twitching, lip-smacking, giveaway weakness, and arm drift/abrupt fall without pronation are considered in mimics of stroke and pseudostroke [3].

#### **1.6 Diagnosis with Clinical Manifestations and Fallacies**

Presentation is very varied and requires a high degree of suspicion. Stroke mimics may present as a functional (conversion) disorder or may be part of the symptomatology of a neurological or medical disorder. The diagnosis of acute ischemic stroke is however not always straightforward. Similar symptoms may develop in number of medical conditions commonly referred to as “stroke mimics” [3]. Diagnosis and management of PS are difficult. Factors that influence diagnosis (or misdiagnosis) and management of PS may be legal, ethical, moral, or financial. PS is when the acute symptoms are suggestive of a stroke but are of psychogenic origin. There are several challenges in the diagnosis and management of these patients. PS is unlike other psychogenic neurologic symptoms. Its presentation is acute and may be an isolated event. PS is and always should be a diagnosis of exclusion that requires concurrence of physical exam and diagnostic testing. Red flags suggest PS may be present, but caution is warranted to avoid a hasty diagnosis. Here are some of the potential indicators: previous history of psychogenic symptoms, history of other unexplained conditions that have undergone extensive work up to no avail, and coexisting, poorly-defined symptoms. PS is not only and simply a stroke mimicker, it is an entity in its own right [7]. Recent rates of stroke under-diagnosis (false-negative cases, “stroke chameleons”) range from 2-26% and 30-43% for stroke over-diagnosis (false-positive cases, “stroke mimics”) [6]. Functional mimics or conversion disorders are less frequent [12–15]. Some patients admitted to acute stroke units are diagnosed as stroke

mimics. A minority have a functional neurological disorder ('functional mimics') [13]. A common type of stroke mimic is a functional neurological disorder presenting with limb weakness, numbness, or speech disturbances (previously known as psychogenic or conversion disorder) [16]. The essential feature of conversion disorder is the presence of symptoms or deficits affecting voluntary sensory or motor activity. These symptoms are not intentionally produced. Motor deficits include impaired balance, paralysis, limb weakness, and urinary retention. According to the DMS-5 criteria, the following features are identified for psychogenic paralysis etiology: [1] Contradictory clinical findings such as normal muscle tone, normal deep reflex, or pyramidal signs; [2] Paradoxical behavior; [3] Normal electrophysiological features; and [4] Normal radiographic findings [10,17]. Conversion symptoms are often inconsistent. A "paralyzed" extremity will be moved inadvertently while dressing, or when attention is as conversion disorder. Individuals with this disorder may show label indifference or lack of concern about the nature or implications of their symptoms [18]. Clinical features of PMD include: 1] increase or become elaborate when examination is focused on the affected part, 2] decrease or resolve when not the clear focus of attention or inquiry and during tests requiring concentration or other tasks, 3] triggered or relieved with unusual non-physiological interventions (such as trigger points on the body, tuning fork), 4] deliberate slowness of movements, 5] rhythmical and often violent shaking, 6] changing characteristics of movements -severity, frequency, type, and distribution, 7] entrainment (see below), 8] selective disability, 9] demonstration of fatigue, 10] presence of multiple movement disorders, 11] presence of bizarre movements which are difficult to classify, 12] excessive startle response, 13] paroxysmal movement disorders, and 14) bizarre gait [8]. The absence of expected findings of disk herniation, epidural hematoma, or contusion of the spinal cord will suggest and support the diagnosis of Conversion Disorder [18]. Failure to diagnose stroke can preclude time-sensitive treatments and has been associated with poor outcomes [6]. Functional stroke mimics are an important subgroup admitted to acute stroke services and have a distinct demographic and clinical profile [13]. Hoover's sign, hip abductor sign, drift without pronation, and give-way weakness (collapsing) are helping signs in functional stroke mimics [16].

### **1.7 Risk Factors**

Stroke mimics may have systemic illness, psychological stress, younger, often had a previous history of migraines or seizures, and fewer vascular risk factors [3]. Psychogenic hemiplegia is prominent among multiple sclerosis, myasthenia gravis, and idiopathic or substance-induced dystonia [18].

### **1.8 Prognosis and Burden**

Generally, the prognosis of motor functional neurological disorder (FND) seems unfavorable [14] and considered poor [15]. Psychogenic paralysis after minor trauma presents a difficult medico-legal issue [18]. The prognosis for full recovery is unfortunately not very good with more than one-third of patients reporting the same or worse deficits during follow-up [20]. While many underlying conditions can be recognized rapidly by careful assessment, a significant proportion of patients unfortunately still receive thrombolysis and admission to a high-intensity stroke unit with inherent risks and unnecessary costs [3]. Additional strategies to improve the accuracy of stroke diagnosis should focus on rapid clinical reasoning in the time-sensitive setting of acute ischemic stroke and identifying imperfections in the healthcare system that may contribute to diagnostic error [6]. These rates of stroke mimic diagnosis pose a high burden on healthcare resources [3].

### **1.9 Workup**

Workup is aimed at reducing underdiagnoses in atypical stroke presentations [6]. Multi-modal CT or magnetic resonance imaging (MRI) may be helpful to confirm an acute ischemic stroke and is necessary if stroke mimics are suspected [3]. A diagnosis of Conversion Disorder should be made only after a thorough medical investigation has been performed to rule out a neurological or general medical condition [10,17]. There are no specific laboratory abnormalities associated with this condition [18]. Neurodiagnostic techniques measure brain and spinal cord dysfunction that might otherwise be missed with CT or MRI. They complement imaging techniques by providing a noninvasive measure of the existing physiology [21-23]. At times, physicians are faced with situations in which a patient's symptoms are not completely compatible with the description of the original accident or the physical examination [24-29]. In such cases, electrophysiological examination including modalities such as somatosensory evoked potentials (SSEPs) or transcranial motor evoked potentials (TcMEPs) confirms the psychogenic nature of the neurologic deficit [22,23,30].

### **1.10 Management**

Management of PS patients should begin with a prudent, respectful, yet truthful disclosure [7]. In contrast to the unconscious nature of symptoms in somatoform disorders, factitious disorder, and malingering suggest that the patient is purposely being deceptive [7]. Treatment of functional disorders can be challenging, is often incomplete, and requires early psychiatric intervention [3].

## **2. Method of study and patients**

My study was technical, prospective, and interventional for 31 cases. The study was conducted in the physician outpatient clinic (POC), Kafr El-Bateekh Central Hospital, and Fraskour Central Hospital. The author reported 31 cases of psychogenic hemiplegia over 5 years and 3 months, starting on May 07, 2019, and, ending on August 12, 2024 (Table 1). Complete clinical and specifically neurological examination was done for all cases. CBC, liver enzymes, RBS, renal function tests, and sometimes ABG were done

as routine investigations in most cases. ECG tracings were only provided. Ionized calcium was used in most cases. Clinical and laboratory data of all cases were collected (Tables 2 and 3).

• **Suggesting hypothesis and research objectives**

- **Suggesting hypothesis:** Yasser’s procedure can improve the psychogenic hemiplegia.
- **The research objectives** to evaluate this hypothesis might include: What is psychogenic hemiplegia? What is Yasser’s procedure? How can Yasser’s procedure improve psychogenic hemiplegia? Is the study supported by past publicized literature studies? Is there a relationship between Yasser’s procedure and the improvement of psychogenic hemiplegia? What is the magnitude of both psychogenic hemiplegia response and complications of Yasser’s procedure in the study?
- **Assessment of treatment response was done with** the presence of:
  - Entirely (**positive response**) recovery of the movement.
  - There was recurrent the same attack for one case had happened 17 months ago (**Recurrence**).
  - All the above criteria were assessed in parallel to the clinical status.
- **The patient's oral informed consent was taken.** Ethical issues were considered. But, unfortunately, there was no approval.

Issue	Definition
Title	Yasser’s Sphygmomanometer Procedure and Dramatic Recovery for the Psychogenic Hemiplegia; a New Maneuver in Emergency Medicine and Neuropsychiatry
Estimated enrollment	31 participants
Study type	Technical, observational, and interventional
Observational model	Case series
Time	Prospective
Study date	Started on May 07, 2019, and ended on August 12, 2024

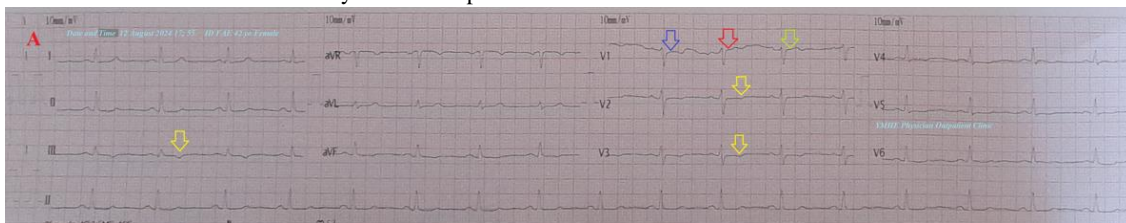
**Table 1:** Showing remarks on the study method and data.

• **Eligibility criteria:**

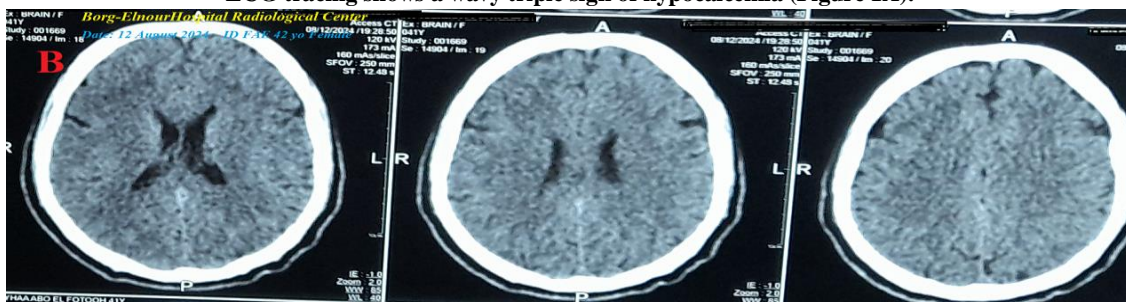- Inclusion criteria: All cases of psychogenic hemiplegia.
- Exclusion criteria:
  1. Evidence of organic stroke (not studied).
  2. Patient of peripheral arterial disease.
  3. Shock.
  4. Patient on B-blockers.

**Case presentations**

• **Case No. 1:** A 42-year-old married female Teacher, Egyptian patient was presented to the physician outpatient clinic (POC) after psychological stress due to a home burn with left side weakness, ipsilateral body aches, and ipsilateral facial weakness and numbness. She was tested for latent tetany which was positive.



**ECG tracing shows a wavy triple sign of hypocalcemia (Figure 1A).**

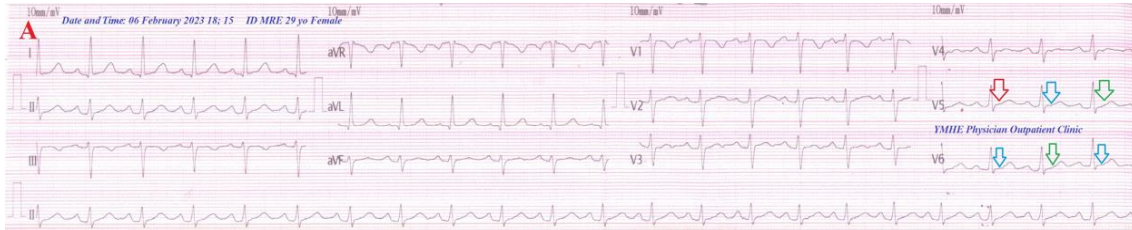


**There are laboratory hypocalcemia and vitamin D deficiency. Brain CT was normal (Figure 1B).**

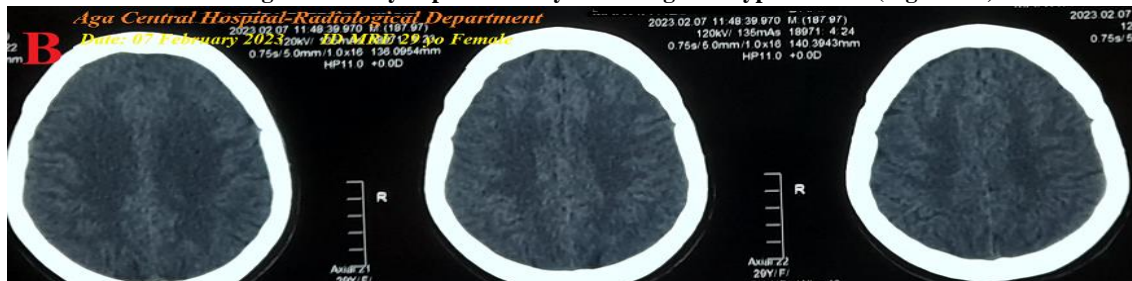Yasser's sphygmomanometer procedure was applied in both the left upper and lower extremities with a dramatically improving response. Complete clinical recovery had happened. An oral calcium-vitamin D tab was prescribed for two weeks.

Figure 1 A-ECG tracing on the day of the presentation shows a Wavy triple sign" in V1 (dark blue, red, and lime arrows) and superficial T-wave inversion in III, V2, and V3 leads. B-Brain CT sections were done on the day of the presentation showing no abnormalities. Red arrows =elevated beats, green arrows = isoelectric beats, and blue arrows =depressed beats.

• **Case No. 2:** A 29-year-old married female housewife Egyptian patient was presented to the POC after sadness with left side weakness, ipsilateral body aches, ipsilateral facial weakness, and hyperventilation syndrome. She was tested for latent tetany which was positive. There is laboratory hypocalcemia.



ECG tracing shows wavy triple and wavy double signs of hypocalcemia (Figure 2A).

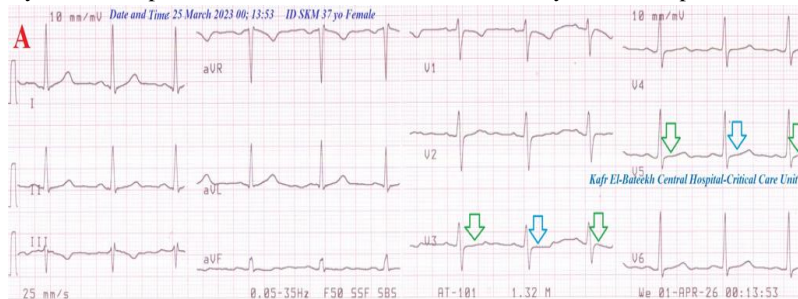


Brain CT was normal (Figure 2B).


Yasser's sphygmomanometer procedure was applied in both the left upper and lower extremities with a dramatically improving response. Complete clinical recovery had happened. An oral calcium-vitamin D tab was prescribed for two weeks.

Figure 2 A-ECG tracing on the day of the presentation shows a Wavy triple sign" in V5 (light blue, red, and green arrows) and a Wavy double sign" in V6 (light blue and green arrows). B-Brain CT sections were done on the second day of the presentation showing no abnormalities. Red arrows =elevated beats, green arrows = isoelectric beats, and blue arrows =depressed beats.

• **Case No. 3:** A 37-year-old Employee married female Egyptian patient was presented to the ICU after stress with left side weakness, ipsilateral body aches, and paresthesia. She was tested for latent tetany which was positive.



ECG tracing shows a wavy double sign of hypocalcemia (Figure 3A).

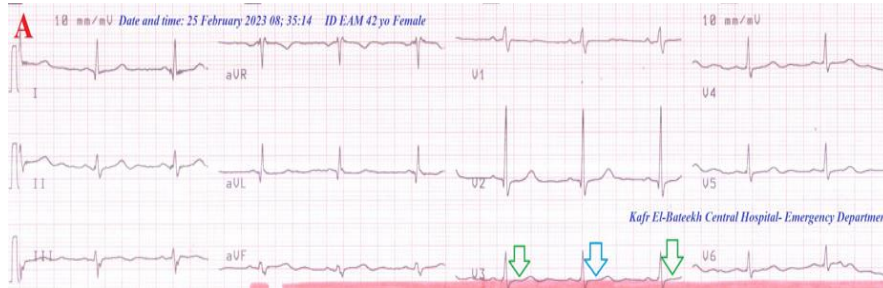


**Brain CT was normal (Figure 3B).**

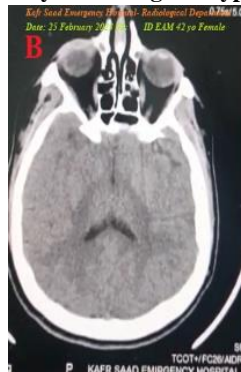
Yasser's sphygmomanometer procedure was applied in both the left upper and lower extremities with a dramatically improving response. Complete clinical recovery had happened. An oral calcium-vitamin D tab was prescribed for two weeks.

Figure 3 A-ECG tracing on the day of the presentation shows a Wavy double sign" in V3 and V5 (light blue and green arrows). B-Brain CT video section was done on the day of the presentation showing no abnormalities. Green arrows = isoelectric beats, and blue arrows =depressed beats.

• **Case No. 4:** A 42-year-old married Housewife female Egyptian patient was presented to the emergency department (ED) after stress with left side weakness, ipsilateral body aches, and numbness. She was tested for latent tetany which was positive.



**ECG tracing shows a wavy double sign of hypocalcemia (Figure 4A).**

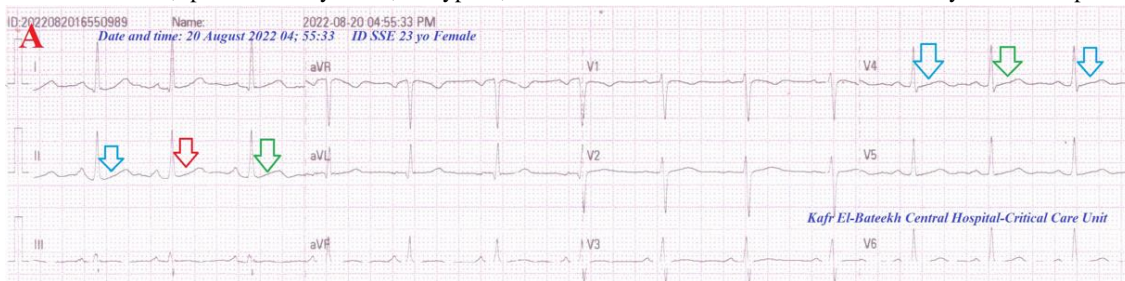


**Brain CT was normal (Figure 4B).**

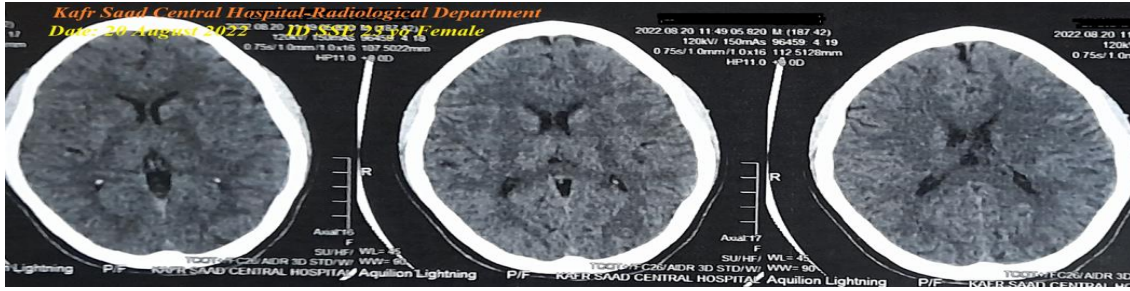
Yasser's sphygmomanometer procedure was applied in both the left upper and lower extremities with a dramatically improving response. Complete clinical recovery had happened. An oral calcium-vitamin D tab was prescribed for two weeks.

Figure 4 A-ECG tracing on the day of the presentation shows a Wavy double sign" in V3 (light blue and green arrows). B-Brain CT video section was done on the day of the presentation showing no abnormalities. Green arrows = isoelectric beats, and blue arrows =depressed beats.

• **Case No. 5:** A 23-year-old divorced housewife female Egyptian patient was presented to the ICU after psycho-familial troubles with left-side weakness, ipsilateral body aches, tachypnea, and numbness. She was tested for latent tetany which was positive.



**ECG tracing shows wavy triple and wavy double signs of hypocalcemia (Figure 5A).**

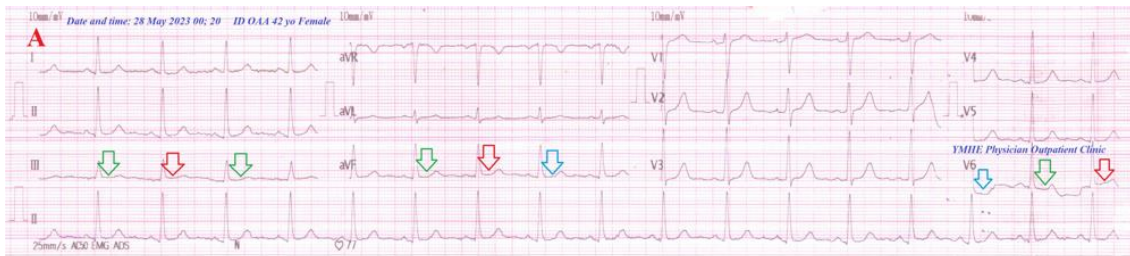


**There is laboratory hypocalcemia. Brain CT was normal (Figure 5B).**

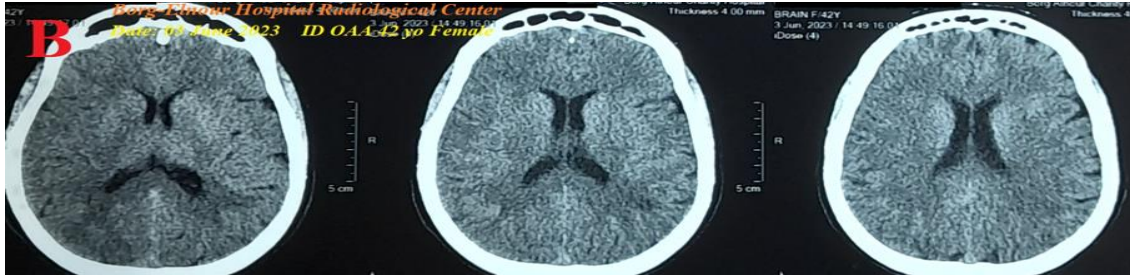Yasser's sphygmomanometer procedure was applied in both the left upper and lower extremities with a dramatically improving response. Complete clinical recovery had happened. An oral calcium-vitamin D tab was prescribed for two weeks.

Figure 5 A-ECG tracing on the day of the presentation shows a Wavy triple sign" in lead II (light blue, red, and green arrows) and a Wavy double sign" in V4 (light blue and green arrows). B-Brain CT sections were done on the second day of the presentation showing no abnormalities. Red arrows =elevated beats, green arrows = isoelectric beats, and blue arrows =depressed beats.

• **Case No. 6:** A 42-year-old married female housewife Egyptian patient was presented to the POC after psycho-familial troubles with right side weakness, ipsilateral body aches, ipsilateral facial weakness, and paresthesia. She was tested for latent tetany which was positive.



**ECG tracing shows Wavy triple and Wavy double signs of hypocalcemia (Figure 6A).**

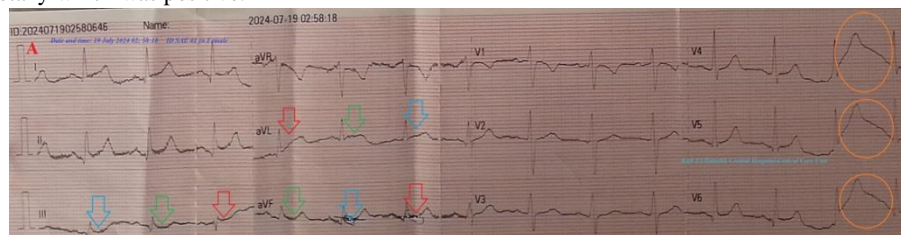


**There is laboratory hypocalcemia. Brain CT was normal (Figure 6B).**

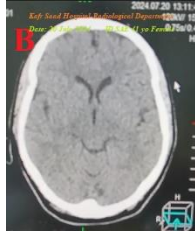
Yasser's sphygmomanometer procedure was applied in both the left upper and lower extremities with dramatic improving response. Complete clinical recovery had happened. An oral calcium-vitamin D tab was prescribed for two weeks.

Figure 6 A-ECG tracing on the day of the presentation shows the Wavy triple sign" in aVF and V6 leads (light blue, red, and green arrows) and the Wavy double sign" in lead II (red and green arrows). B-Brain CT sections were done on the second day of the presentation showing no abnormalities. Red arrows =elevated beats, green arrows = isoelectric beats, and blue arrows =depressed beats.

• **Case No. 7:** A 41-year-old married female housewife Egyptian patient was presented to the ICU after psychogenic stress with the left side weakness, ipsilateral body aches, ipsilateral facial weakness, hyperventilation, chest pain, and numbness. She was tested for latent tetany which was positive.



**ECG tracing showing Wavy triple sign, Tee-Pee sign, and Camel hump T-waves (Figure 7A).**

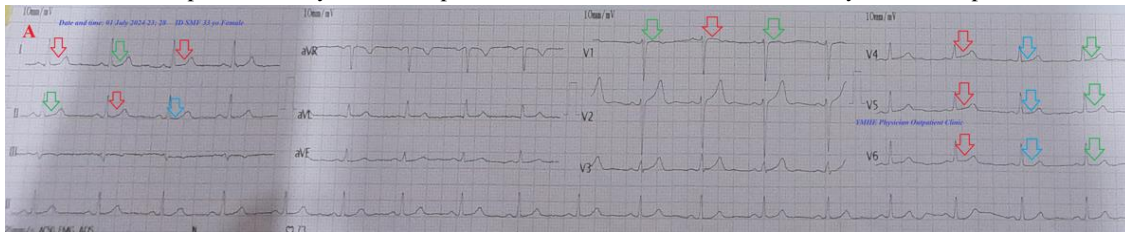


**There is no laboratory hypocalcemia. Brain CT was normal (Figure 7B).**

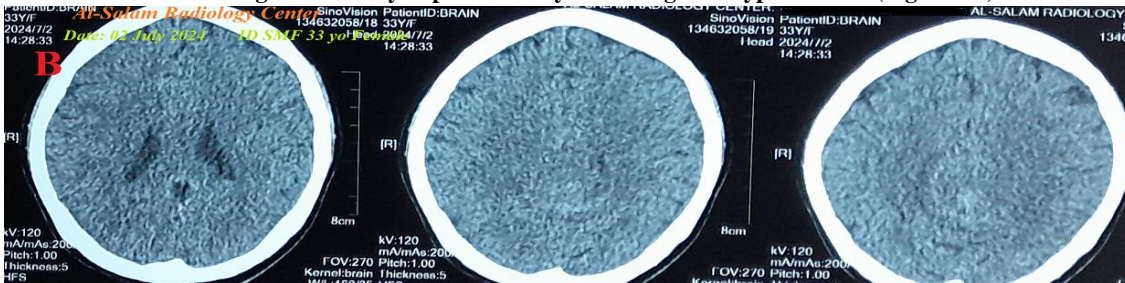
Yasser’s sphygmomanometer procedure was applied in both the left upper and lower extremities with a dramatically improving response. Complete clinical recovery had happened. An oral calcium-vitamin D tab was prescribed for two weeks.

Figure 7 A-ECG tracing on the day of the presentation shows Wavy triple sign” in III, aVL, and aVF leads (light blue, red, and green arrows), and Tee-Pee sign with Camel hump T-waves” in V4-6 leads (orange circles). B-Brain CT video section was done on the third day of the presentation showing no abnormalities. Green arrows = isoelectric beats, and blue arrows =depressed beats.

• Case No. 8: A 33-year-old married female housewife Egyptian patient was presented to the POC after psycho-familial troubles with left side weakness, ipsilateral body aches, and paresthesia. She was tested for latent tetany which was positive.



**ECG tracing shows Wavy triple and wavy double signs of hypocalcemia (Figure 8A).**

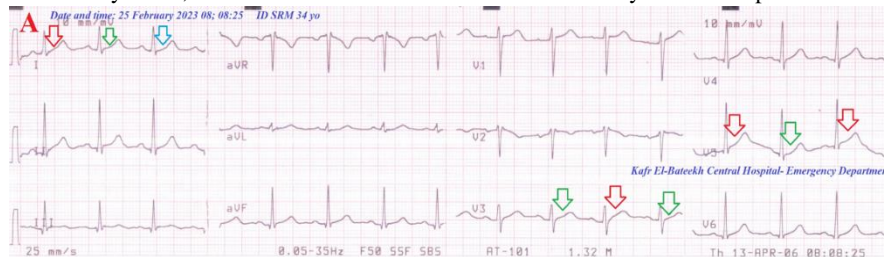


**There is laboratory hypocalcemia. Brain CT was normal (Figure 8B).**

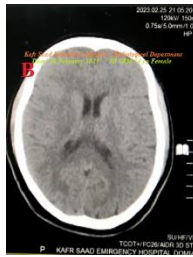
Yasser’s sphygmomanometer procedure was applied in both the left upper and lower extremities with a dramatically improving response. Complete clinical recovery had happened. An oral calcium-vitamin D tab was prescribed for two weeks.

Figure 8 A-ECG tracing on the day of the presentation shows Wavy triple sign” in II and V4-6 leads (light blue, red, and green arrows) and Wavy double sign” in lead I and V1 (red and green arrows). B-Brain CT sections were done on the second day of the presentation showing no abnormalities. Red arrows =elevated beats, green arrows = isoelectric beats, and blue arrows =depressed beats.

• Case No. 9: A 34-year-old married worker female Egyptian patient was presented to the ED after psychogenic stress with left-side weakness, ipsilateral body aches, and numbness. She was tested for latent tetany which was positive.





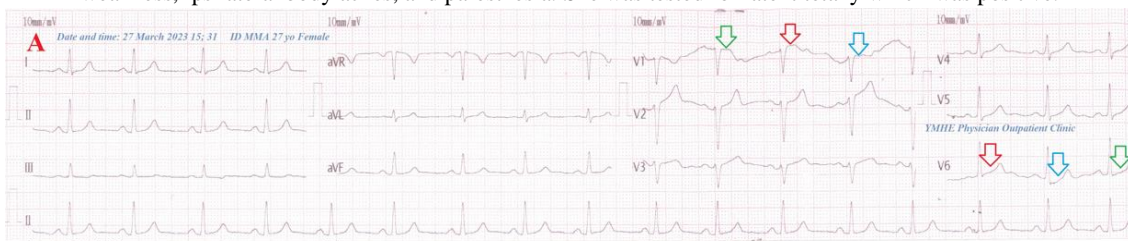


**ECG tracing shows Wavy triple and Wavy double signs of hypocalcemia (Figure 9B).**

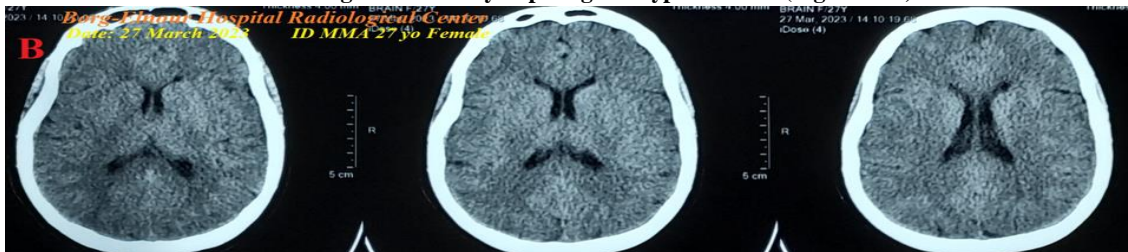
Yasser's sphygmomanometer procedure was applied in both the left upper and lower extremities with a dramatically improving response. Complete clinical recovery had happened. An oral calcium-vitamin D tab was prescribed for two weeks.

Figure 9 A-ECG tracing on the day of the presentation shows a Wavy triple sign" in lead I (light blue, red, and green arrows), and Wavy double sign" in lead I and V3, and V5 (red and green arrows). B-Brain CT video section was done on the second day of the presentation showing no abnormalities. Green arrows = isoelectric beats, and blue arrows =depressed beats.

- **Case No. 10:** A 27-year-old married female farmer Egyptian patient was presented to the POC after sadness with left side weakness, ipsilateral body aches, and paresthesia. She was tested for latent tetany which was positive.



**ECG tracing shows a wavy triple sign of hypocalcemia (Figure 10B).**



**There is laboratory hypocalcemia. Brain CT was normal (Figure 10B).**

Yasser's sphygmomanometer procedure was applied in both the left upper and lower extremities with a dramatically improving response. Complete clinical recovery had happened. An oral calcium-vitamin D tab was prescribed for two weeks.

Figure 10 A-ECG tracing on the day of the presentation shows a Wavy triple sign" in V1 and V6 leads (light blue, red, and green arrows). B-Brain CT sections were done on the second day of the presentation show no abnormalities. Red arrows =elevated beats, green arrows = isoelectric beats, and blue arrows =depressed beats.

- **Case No. 11:** A 21-year-old married female housewife Egyptian patient was presented to the POC after psycho-familial troubles with left side weakness, ipsilateral body aches, ipsilateral facial weakness, tachypnea, and paresthesia. She was pregnant. She was tested for latent tetany which was positive. ECG tracing shows a double sign of hypocalcemia. There is laboratory hypocalcemia. Brain CT was not done due to pregnancy. Yasser's sphygmomanometer procedure was applied in both the left upper and lower extremities with a dramatically improving response. Complete clinical recovery had happened. An oral calcium-vitamin D tab was prescribed for two weeks.

- **Case No. 12:** A 25-year-old divorced female housewife Egyptian patient was presented to the ICU after psycho-familial troubles with left side weakness, ipsilateral body aches, and numbness. The same attack happened 17 months ago. She was tested for latent tetany which was positive. ECG tracing showed a Wavy triple sign of hypocalcemia. Brain CT was normal. Yasser's sphygmomanometer procedure was applied in both the left upper and lower extremities with a dramatically improving response. Complete clinical recovery had happened. An oral calcium-vitamin D tab was prescribed for two weeks.

- **Case No. 13:** A 43-year-old married female housewife Egyptian patient was presented to the ICU after psycho-familial troubles with left side weakness, ipsilateral body aches, ipsilateral facial weakness, tachypnea, and paresthesia. She was tested for latent tetany which was positive ECG tracing showing a Wavy triple sign of hypocalcemia. There is laboratory hypocalcemia. Brain CT

was normal. Yasser's sphygmomanometer procedure was applied in both the left upper and lower extremities with a dramatically improving response. Complete clinical recovery had happened. An oral calcium-vitamin D tab was prescribed for two weeks.

• **Case No. 14:** A 35-year-old married male worker Egyptian patient presented to the ED after work troubles with left-side weakness, ipsilateral body aches, chest pain, and paresthesia. He was tested for latent tetany which was positive. ECG tracing showed a Wavy triple sign of hypocalcemia. Brain CT and brain MRI were normal. Yasser's sphygmomanometer procedure was applied in both the left upper and lower extremities with a dramatically improving response. Complete clinical recovery had happened. An oral calcium-vitamin D tab was prescribed for two weeks.

• **Case No. 15:** A 28-year-old married female housewife Egyptian patient presented to the POC after psycho-familial troubles with left-side weakness, ipsilateral body aches, and numbness. She was tested for latent tetany which was positive. ECG tracing showing Wavy triple sign, Tee-Pee sign, and Camel hump T-waves. Brain CT was normal. Yasser's sphygmomanometer procedure was applied in both the left upper and lower extremities with dramatic improving response. Complete clinical recovery had happened. An oral calcium-vitamin D tab was prescribed for two weeks.

• **Case No. 16:** A 43-year-old married female housewife Egyptian patient was presented to the POC after psycho-familial troubles with left-side weakness, ipsilateral body aches, ipsilateral facial weakness, tachypnea, and tetany. ECG tracing showed a Wavy triple sign of hypocalcemia. There is laboratory hypocalcemia. Brain CT was normal. Yasser's sphygmomanometer procedure was applied in both the left upper and lower extremities with a dramatically improving response. Complete clinical recovery had happened. Two IV calcium was initially given, and then an oral calcium-vitamin D tab was prescribed for two weeks.

• **Case No. 17:** A 65-year-old married housewife female Egyptian patient was presented to the POC after psycho-familial troubles with right-side weakness, ipsilateral body aches, ipsilateral facial weakness, and tetany. There is laboratory hypocalcemia. ECG tracing shows frequent PVCs. Brain CT was normal. Yasser's sphygmomanometer procedure was applied in both the left upper and lower extremities with a dramatically improving response. Complete clinical recovery had happened. Two IV calcium was initially given then, an oral calcium-vitamin D tab was prescribed for two weeks.

• **Case No. 18:** A 40-year-old married female housewife Egyptian patient was presented to the POC after psycho-familial troubles with left-side weakness, ipsilateral body aches, ipsilateral facial weakness, tachypnea, and paresthesia. She was tested for latent tetany which was positive. ECG tracing showed a Wavy triple sign of hypocalcemia. Brain CT was normal. Yasser's sphygmomanometer procedure was applied in both the left upper and lower extremities with a dramatically improving response. Complete clinical recovery had happened. An oral calcium-vitamin D tab was prescribed for two weeks.

• **Case No. 19:** A 40-year-old married female housewife Egyptian patient was presented to the ICU after sadness with left-side weakness, ipsilateral body aches, and numbness. She was tested for latent tetany which was positive. Brain CT was normal. Yasser's sphygmomanometer procedure was applied in both the left upper and lower extremities with a dramatically improving response. Complete clinical recovery had happened. An oral calcium-vitamin D tab was prescribed for two weeks.

• **Case No. 20:** A 25-year-old married female housewife Egyptian patient was presented to the POC after psycho-familial troubles with left upper limb weakness, ipsilateral body aches, ipsilateral facial weakness, tachypnea, chest pain, and numbness. She was tested for latent tetany which was positive. ECG tracing showed a Wavy triple sign of hypocalcemia. Brain CT was normal. Yasser's sphygmomanometer procedure was applied in both the left upper and lower extremities with a dramatically improving response. Complete clinical recovery had happened. An oral calcium-vitamin D tab was prescribed for two weeks.

• **Case No. 21:** A 36-year-old married male sweet worker Egyptian patient was presented to the ICU after sadness with left side weakness, ipsilateral body aches, ipsilateral facial weakness, and paresthesia. He was tested for latent tetany which was positive. ECG tracing and brain CT were normal. Yasser's sphygmomanometer procedure was applied in both the left upper and lower extremities with a dramatically improving response. Complete clinical recovery had happened. An oral calcium-vitamin D tab was prescribed for two weeks.

• **Case No. 22:** A 37-year-old married female housewife Egyptian patient was presented to the POC after stress with left side weakness, ipsilateral body aches, ipsilateral facial weakness, and paresthesia. She was tested for latent tetany which was positive. ECG tracing and brain CT were normal. Yasser's sphygmomanometer procedure was applied in both the left upper and lower extremities with dramatic improving response. Complete clinical recovery had happened. An oral calcium-vitamin D tab was prescribed for two weeks.

• **Case No. 23:** A 19-year-old single male student Egyptian patient was presented to the POC after psychological stress with left side weakness, ipsilateral body aches, ipsilateral facial weakness, and numbness. He was tested for latent tetany which was positive. ECG tracing showed a Wavy triple sign of hypocalcemia. Brain CT was normal. Yasser's sphygmomanometer procedure was applied in both the left upper and lower extremities with a dramatically improving response. Complete clinical recovery had happened. An oral calcium-vitamin D tab was prescribed for two weeks.

• **Case No. 24:** A 29-year-old married female farmer Egyptian patient was presented to the POC after psycho-familial troubles with left side weakness, ipsilateral body aches, ipsilateral facial weakness, tachypnea, and tetany. ECG tracing shows a Wavy double sign of hypocalcemia. Brain CT was normal. Yasser's sphygmomanometer procedure was applied in both the left upper and lower

extremities with a dramatically improving response. Complete clinical recovery had happened. Two IV calcium were initially, given then an oral calcium-vitamin D tab was prescribed for two weeks.

- **Case No. 25:** A 34-year-old married female teacher Egyptian patient was presented to the POC after sadness with left side weakness, ipsilateral body aches, ipsilateral facial weakness, tachypnea, and paresthesia. She was tested for latent tetany which was positive. ECG tracing showed a wavy triple sign of hypocalcemia. Brain CT was normal. Yasser's sphygmomanometer procedure was applied in both the left upper and lower extremities with a dramatically improving response. Complete clinical recovery had happened. An oral calcium-vitamin D tab was prescribed for two weeks.

- **Case No. 26:** A 42-year-old married female farmer Egyptian patient was presented to the POC after psychological stress with left side weakness, ipsilateral body aches, ipsilateral facial weakness, tachypnea, and paresthesia. She was tested for latent tetany which was positive. ECG tracing shows a wavy triple sign of hypocalcemia. Brain CT was normal. Yasser's sphygmomanometer procedure was applied in both the left upper and lower extremities with a dramatically improving response. Complete clinical recovery had happened. An oral calcium-vitamin D tab was prescribed for two weeks.

- **Case No. 27:** A 35-year-old married male farmer Egyptian patient was presented to the POC after sadness with left upper limb weakness, ipsilateral body aches, and paresthesia. The weakness suddenly reversed to the right lower limb. He was tested for latent tetany which was positive. ECG tracing shows a wavy triple sign of hypocalcemia with a repolarization pattern. Brain CT was normal. Yasser's sphygmomanometer procedure was applied in both the left upper and lower extremities with a dramatically improving response. Complete clinical recovery had happened. An oral calcium-vitamin D tab was prescribed for two weeks.

- **Case No. 28:** A 16-year-old single female student Egyptian patient was presented to the POC after psychological stress with left-side weakness, ipsilateral facial weakness, tachypnea, palpitations, and paresthesia. She was tested for latent tetany which was positive. ECG tracing shows a Wavy triple sign of hypocalcemia and sinus tachycardia. Brain CT was normal. Yasser's sphygmomanometer procedure was applied in both the left upper and lower extremities with dramatic improving response. Complete clinical recovery had happened. An oral calcium-vitamin D tab was prescribed for two weeks.

- **Case No. 29:** A 50-year-old married female housewife Egyptian patient was presented to the POC after sadness with left side weakness, ipsilateral body aches, ipsilateral facial weakness, dysarthria, and paresthesia. She was tested for latent tetany which was positive. ECG tracing and brain CT were normal. Yasser's sphygmomanometer procedure was applied in both the left upper and lower extremities with dramatic improving response. Complete clinical recovery had happened. An oral calcium-vitamin D tab was prescribed for two weeks.

- **Case No. 30:** A 47-year-old married female housewife Egyptian patient was presented to the POC after stress with left side weakness, ipsilateral body aches, ipsilateral facial weakness, tachypnea, and paresthesia. She was tested for latent tetany which was positive. ECG tracing shows a Wavy triple sign of hypocalcemia. Brain CT was normal. Yasser's sphygmomanometer procedure was applied in both the left upper and lower extremities with dramatic improving response. Complete clinical recovery had happened. An oral calcium-vitamin D tab was prescribed for two weeks.

- **Case No. 31:** A 34-year-old married female teacher Egyptian patient was presented to the POC after psychological stress with left side weakness, ipsilateral body aches, ipsilateral facial weakness, tachypnea, and paresthesia. She was tested for latent tetany which was positive. ECG tracing showed a Wavy triple sign of hypocalcemia. Brain CT was normal. Yasser's sphygmomanometer procedure was applied in both the left upper and lower extremities with a dramatically improving response. Complete clinical recovery had happened. An oral calcium-vitamin D tab was prescribed for two weeks.

### 3. Results

A total of 31 patients are included in this study. There is female sex predominance; 87.1% (n: 27) vs. 12.9% (n = 4) of the male patients. The mean age of the cases was 35.29 years (range; 16-65). The most commonly associated hemiplegia in the study was the left-side hemiplegia of the cases; 90.32% (n: 28) vs. right-side hemiplegia; 6.45% (n = 2) and reversal hemiplegia; 3.23% (n: 1). Latent tetany was the most predominant tetany; 90.32% (n: 28) vs. the manifested; 9.68% (n = 3). Wavy triple sign represents the most frequent sign in the ECG; 35.48% (n: 11) vs. Wavy double sign; 22.58% (n: 7), combined Wavy triple sign and Wavy double sign; 16.13% (n: 5), Wavy triple sign with Tee-Pee sign and Camel hump T-waves; 6.45% (n: 2), sinus tachycardia with Wavy triple sign; 3.23% (n: 1), Premature ventricular complexes; 3.23% (n: 1), normal; 9.68% (n: 3), and unavailable ECG; 3.23% (n: 1). Laboratory hypocalcemia for ionized calcium were detected in 32.26% (n: 10). The response to the Yasser's Sphygmomanometer Maneuver was 100%, but there was recurrence for one case (Case No. 5) after about 17 months. The most common occupations in the study were a housewife; 54.84% (17), farmer; 16.13% (n: 5), worker; 9.68% (n: 3), teacher; 9.68% (n: 3), student; 6.45% (n: 2), and employee; 3.23% (n: 1) (Figure 2 and 3).

Case No.	Age/y	Sex	Occupation	Pulse/bpm	BP/mmHg		Temp/C	RR/bpm	O2 Sat/%	Tetany	ECG	Ionized Ca <sup>++</sup>	Hemiplegia
					SBP	DBP							
1	42	F	Teacher	70	130	70	36	16	97	Latent	WTS	4.24 mg/dl	Left
2	29	F	Housewife	95	100	80	37	19	99	Latent	WTS+WDS	3.79mg/dl	Left
3	37	F	Employee	70	100	70	36.5	15	97	Latent	WDS	UA	Left
4	42	F	Housewife	66	110	60	36	14	95	Latent	WDS	UA	Left

Case No.	Age/y	Sex	Occupation	Pulse/ bpm	BP /mmHg		Temp/C	RR/ bpm	O2 Sat/%	Tetany	ECG	Ionized Ca <sup>++</sup>	Hemiplegia
					SBP	DBP							
5	23	F	Housewife	86	140	90	37	20	99	Latent	WTS+WDS	0.66 mmol/l	Left
6	42	F	Housewife	82	110	70	37	21	96	Latent	WTS+WDS	4.3 mg/dl	Right
7	41	F	Housewife	83	120	80	36.6	22	95	Latent	WTS+TPS+CHTS	1.32mmol /l	Left
8	33	F	Housewife	80	110	70	36	17	97	Latent	WTS+WDS	1.1 mmol/l	Left
9	34	F	Worker	93	130	80	80	19	99	Latent	WTS+WDS	UA	Left
10	27	F	Farmer	74	140	80	37	16	99	Latent	WTS	1mmol/l	Left
11*	21	F	Housewife	65	140	70	36	24	97	Latent	WDS	3.76mg/dl	Left
12	25	F	Housewife	71	110	70	36	18	96	Latent	WTS	4.29 mg/dl	Left
13	43	F	Housewife	80	100	80	36	18	95	Latent	WTS	0.57 mmol/l	Left
14	35	M	Worker	80	100	60	37	18	98	Latent	WTS	UA	Left
15	28	F	Housewife	74	110	70	36.7	21	99	Latent	WTS+TPS+CHTS	UA	Left
16	43	F	Housewife	65	140	70	36	24	97	Manifested	WDS	UA	Left
17	65	F	Housewife	86	130	80	37.5	22	95	Manifested		UA	Right
18	40	F	Housewife	76	130	90	36.5	16	99	Latent	WDS	UA	Left
19	40	F	Housewife	88	120	70	37	18	98	Latent	UA	UA	Left
20	25	F	Housewife	76	130	80	36	20	95	Latent	WDS	UA	Left
21	36	M	Worker	70	120	80	37.5	14	98	Latent	Normal	UA	Left
22	37	F	Housewife	98	100	70	36	16	95	Latent	Normal	UA	Left
23	19	M	Student	70	130	70	36	17	99	Latent	WTS	UA	Left
24	29	F	Farmer	68	90	70	36.5	22	97	Manifested	WDS	UA	Left
25	34	F	Teacher	72	100	60	37	23	99	Latent	WTS	UA	Left
26	42	F	Farmer	84	130	80	36	25	95	Latent	WTS	UA	Left
27	35	M	Farmer	80	140	80	36	18	96	Latent	WTS	UA	Reversed
28	16	F	Student	125	140	70	37	20	97	Latent	WTS+ST	UA	Left
29	50	F	Farmer	67	120	80	36.5	24	97	Latent	Normal	UA	Left
30	47	F	Housewife	97	130	80	37	21	95	Latent	WTS	UA	Left
31	34	F	Teacher	94	120	90	37	17	99	Latent	WTS	UA	Left

**Table 2:** Summary of the history, clinical, and management data; (n: 31)

Abbreviations: BP; Blood pressure, Ca<sup>++</sup>: Calcium, CHTW: Camel hump T-waves, DBP; Diastolic blood pressure, F; Female, Male; Male, PVCs: Premature ventricular complexes, SBP; Systolic blood pressure, RR: Respiratory rate, ST: Sinus tachycardia, TPS: Tee-Pee sign, UA: Unavailable, WDS; Wavy double sign, WTS; Wavy triple sign

\*: Pregnant

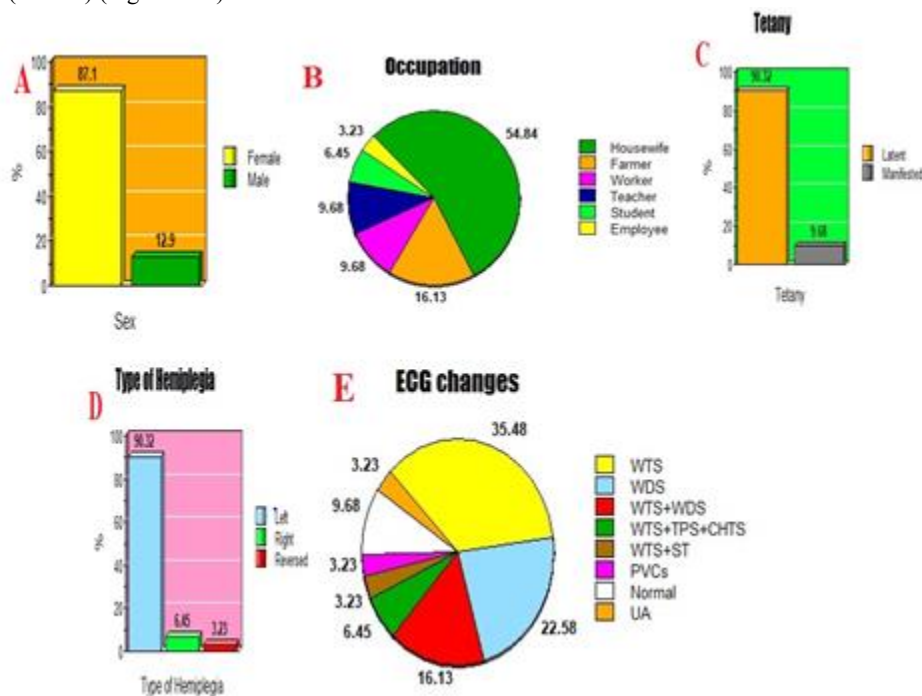
Variable	Numbers	%	Range	Means
<b>Age</b>	-	-	16-65	35.29
<b>Sex</b>				
<b>Female</b>	27	87.1	-	-
<b>Male</b>	4	12.9		
<b>Type of hemiplegia</b>				
<b>Left</b>	28	90.32	-	-
<b>Right</b>	2	6.45		
<b>Reversed</b>	1	3.23		
<b>Tetany</b>				
<b>Latent</b>	28	90.32	-	-
<b>Manifested</b>	3	9.68		
<b>ECG</b>				
<b>WTS</b>	11	35.48	-	-
<b>WDS</b>	7	22.58		
<b>WTS+WDS</b>	5	16.13		
<b>WTS+TPS+CHTS</b>	2	6.45		
<b>WTS+ST</b>	1	3.23		
<b>PVCs</b>	1	3.23		
<b>Normal</b>	3	9.68		
<b>UA</b>	1	3.23		

<b>Laboratory hypocalcemia</b>	10	32.26	-	-
--------------------------------	----	-------	---	---

**Table 3:** Statistical summary of age, sex, type of hemiplegia, tetany, ECG, and laboratory hypocalcemia; (n: 31)

**Abbreviations:** Camel hump T-waves, PVCs: Premature ventricular complexes, ST: Sinus tachycardia, TPS: Tee-Pee sign, UA: Unavailable, WDS; Wavy double sign, WTS; Wavy triple sign

- **Age;**
- Range; 16-65, Minimal; 16, Maximal; 65, Mean; 35.29, Median: 35, and Mode: 42 (Tables 2 and 3).
- **Sex;**
- Female sex; 87.1% (27 cases).
- Male sex; 12.9% (4 cases) (Figure 11A)



**Figure 11:** A. Bar presentation of sex in the study. B. Pie presentation of occupation in the study. C. Bar presentation of tetany in the study. D. Bar presentation of the type of hemiplegia in the study. E. Pie presentation of ECG changes in the study.

• **Occupation**

- Housewife; 54.84% (17 cases)
- Farmer; 16.13% (5 cases)
- Worker; 9.68% (3 cases)
- Teacher; 9.68% (3 cases)
- Student; 6.45% (2 cases)
- Employee; 3.23% (1 case) (Table 3) (Figure 11B).

• **Tetany**

- Latent; 90.32% (28 cases)
- Manifested; 9.68% (3 cases) (Table 3) (Figure 11C).

• **Type of hemiplegia**

- Left; 90.32% (28 cases)
- Right; 6.45% (2 cases)
- Reversed; 3.23% (1 case) (Table 3) (Figure 11D).

• **ECG changes**

- WTS; 35.48% (11 cases)
- WDS; 22.58% (7 cases)
- WTS+WDS; 16.13% (5 cases)
- WTS+TPS+CHTS; 6.45% (2 cases)
- WTS+ST; 3.23% (1 case)
- PVCs; 3.23% (1 case)

- Normal; 9.68% (3 cases)
- UA; 3.23% (1 case) (Table 3) (Figure 11E).

• **Response**

- Application; 100% (31 cases) (Table 2).

**4. Discussion**

**4.1 Past studies**

Depending on the past literature publications, there were interesting case report series and a single study for psychogenic hemiplegia (1994-2020). Haghighi SS (2019) [18] reported one case that has been presented with psychogenic hemiplegia secondary to cervical spine discectomies and fusion reversed by rehabilitation. Haghighi SS and Meyer S (2001) [22] reported a case of psychogenic paraplegia following a motor vehicle accident reversed by treatment of depression and conversion disorder. Morota N et al. (1994) [23] reported a case of a 12-year-old girl presented with psychogenic quadriparesis after undergoing surgical repair of a recurrent syringomyelia that was fully recovered within 1 month by rehabilitation. N Chastan and D Parain (2010) [31] studied 70 patients of psychogenic paralysis and recovery after motor cortex transcranial magnetic stimulation. Berhane L et al. (1998) [25] reported a case of recurrent psychogenic paraplegia following gynecologic laparoscopy reversed with treatment of conversion disorder. Ito A. et al. (2020) [32] reported an unusual case of postoperatively psychogenic tetraplegia the patient spontaneously fully recovered within 12 hours. Shell MG et al. (1997) [24] reported a case of paraplegia presented in a patient with an implantable morphine pump and an epidural abscess with treatment of conversion disorder primarily supportive, focused on consistency and behavioral management. Laraki M et al. (1996) [27] reported a case of hysterical paraplegia in a 15-yr-old, 45-kg girl, transiently after epidural anesthesia and the patient spontaneously fully recovered within 6 days. (Table 4)

Study	Year	Sex	Primary disorder	Secondary trigger	Reversal	Reference
1. Haghighi SS	2019	F	Psychogenic hemiplegia	Cervical spine discectomies and fusion	Rehabilitation	<b>18</b>
2. Haghighi SS and Meyer S	2001	F	Psychogenic paraplegia	Motor vehicle accident	Treatment of depression and conversion disorder	<b>22</b>
3. Morota N et al.	1994	F	Psychogenic quadriparesis	Surgical repair of a recurrent syringomyelia	Rehabilitation	<b>23</b>
4. N Chastan and D Parain	2010	44 F/26 M	Paraparesis	Psychosocial event or a physical injury	Motor cortex transcranial magnetic stimulation	<b>31</b>
5. Berhane L et al.	1998	F	Paraplegia	Gynecologic laparoscopy	Treatment of conversion	<b>25</b>
6. Ito A et al.	2020	F	Tetraplegia	Postoperative	Spontaneous recovery	<b>32</b>
7. Shell MG et al.	1994	F	Paraplegia	Implantable morphine pump and an epidural abscess	Supportive	<b>24</b>
8. Laraki M et al.	1996	F	Paraplegia	Epidural anesthesia	Spontaneous recovery	<b>27</b>

**Table 4:** Past studies for psychogenic coma from 1994 to 2020.F;

Female; M; Male

**4.2 The procedure description**

• **Preparation:**

1. Take a rapid history from patients, relatives, friends, or neighbors. Drug history, acute emotional stress, abuse of substances, psychiatric diseases, swallowing foreign bodies, organic diseases such as IHD, HTN, and DM, etc. History of poisons is mandatory.
2. Do a quick and complete physical examination. Vital signs, measuring O2 saturation using pulse oximetry, and random blood sugar are essential before the maneuver.
3. Do rapid exclusion for organic causes of hemiplegia.

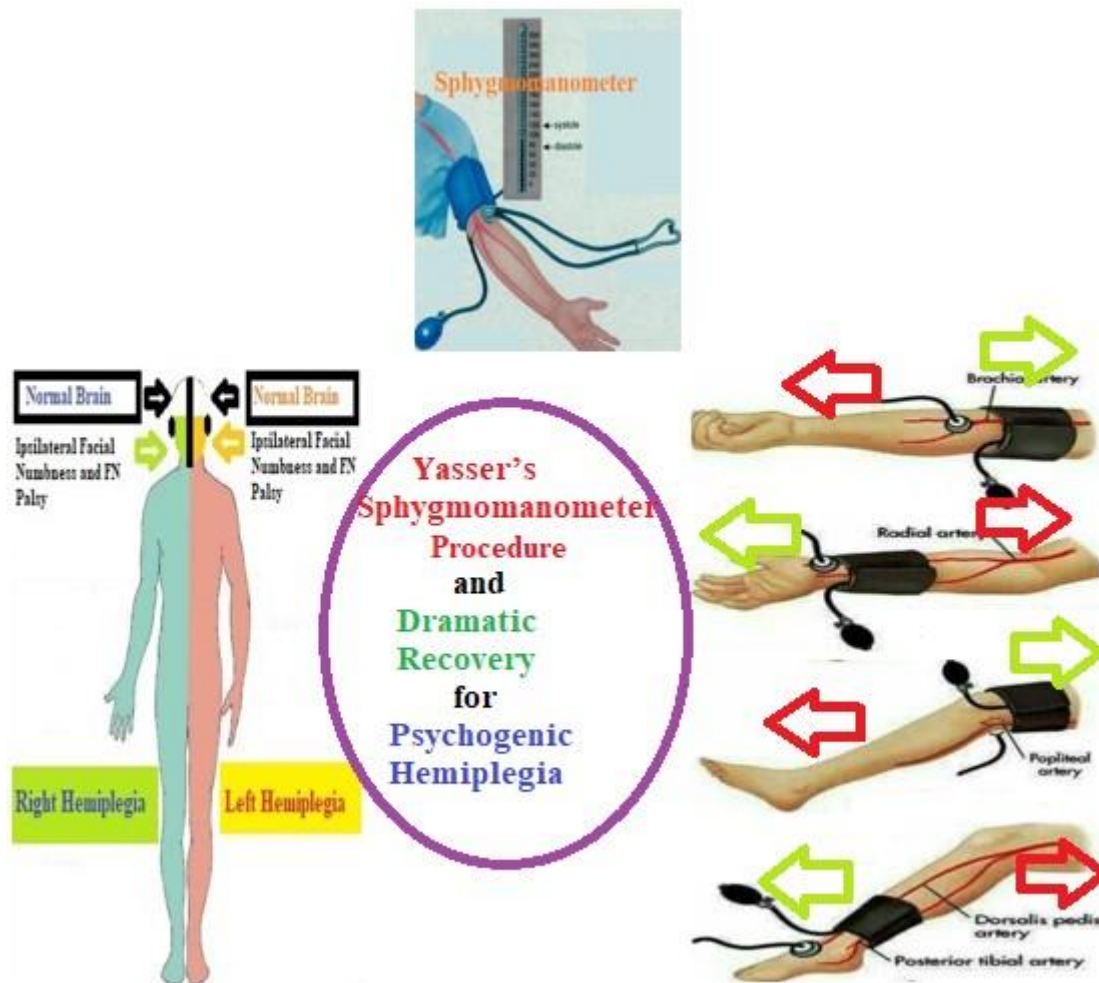
4. Be sure that the case is a psychogenic hemiplegia.
5. Do not allow any visitors and place the patient in a quiet observation area.

**• Indications:**

• Psychogenic hemiplegia. The author depended in a diagnosis of psychogenic hemiplegia on the presence of limb weakness, painful paralyzed extremity, ipsilateral facial numbness or paresthesia with or without facial weakness, normal Glasgow Coma Scale (GCS), and normal brain CT scan. Follow up for at least for 48 hours post recovery with Yasser's Sphygmomanometer Procedure.

**• Principal and Interpretations:**

• Pressuring of the cuff of the sphygmomanometer on inflation may produce an obstructive power at the distal to the compressive site and another transmission power at the proximal to the compressive site. Distal power may be due to compression of local blood arteries resulting in decreasing blood flow to the paralyzed limb inducing some increasing pain over the present pain stimulating the local nerves to produce trial to the movement of this limb. Local hypocalcemia for the paralyzed limb due to this local obstruction may also be a suggestive theory for this pain. On contradictory, the proximal power to the compressive site may be due to transient increasing the diameter of the proximal local blood arteries to the compressive cuff while increasing the blood flow to the proximal area in the paralyzed limb also may be stimulant for the local nerves to produce trial to the movement of this limb. The author thinks that distal power is stronger than the proximal power (red and lime arrows)



**Figure 12:** The author caricaturing a diagram for Yasser's sphygmomanometer procedure in the management of psychogenic hemiplegia.

**• Target:**

- The aim of this procedure is the full gaining of the movements in the paralyzed extremity.

**• The maneuver and response:**

- Measure the blood pressure using a stethoscope and sphygmomanometer as a traditional measurement.
- Wrap the cuff of the sphygmomanometer around the ipsilateral paralyzed extremity.

- Wrap the cuff of the sphygmomanometer around either; just above the brachial area or just above the wrist area and either just above the knee joint or just above the ankle joint.
- Brachial artery, ulnar artery, and radial artery are target arteries in the upper limb. The femoral artery, popliteal artery, posterior tibial artery, and dorsalis pedis artery are target arteries in the lower limb.
- Inflate the cuff with air using a manometer monitoring of sphygmomanometer with no need to use a stethoscope. Inflate till the manometer mercury reaches just above of systolic pressure limit.
- Let the inflated cuff for a few seconds (5-10 seconds) till the patient senses some pain.
- Consider a normal systolic value of 140 mmHg and a diastolic value of 90 mmHg as upper and lower limits.
- Ask the patient to give his or her sense after the persistence of the inflated cuff for a few seconds.
- Request from the patient to move his paralyzed extremity.
- Then the air is slowly let out of the cuff.
- As soon as the patient moves the paralyzed limb, stop the procedure.
- The trial number (times frequency) is a single (**Figure 12**).

• **Advantages:**

- The procedure is easy, available, quick, non-costive, and extremely safe.
- The early recognition of psychogenic hemiplegia and regain of movement can result in reduced iatrogenic complications, hospital costs, and family, and physician anxiety.
- No need to perform an expensive workup routinely.

• **Disadvantages:**

- There were no reported complications.

• **Contraindication:**

- Evidence of organic stroke (not studied), peripheral arterial disease, shock, patient on B-blockers.
- Post-procedure measures:
- When the patient becomes more responsive, re-examine him, obtain a more complete history, and offer him follow-up care, including psychological support if appropriate.
- If the patient is not awake after about 10 seconds after a single trial, begin a more comprehensive medical workup and neuro-psychiatrist consultation.
- Do not ignore or release the patient who has not fully recovered. Instead, he must be fully evaluated for an underlying medical problem, which may require hospital admission.
- Reexamine the patient after regaining consciousness.
- Do not miss the true serious medical emergency in differential diagnoses such as CVA.

**4.3 Limitations of the study:**

- Unavailable electrophysiological examination including modalities such as somatosensory evoked potentials (SSEPs) or transcranial motor evoked potentials (TcMEPs) were the main study limitations.

**5. Conclusion and recommendations**

- The author concluded that Yasser's sphygmomanometer procedure is easy, available, quick, non-costive, time-saving, and extremely safe for psychogenic hemiplegia.
- There are strong association between hypocalcemia (clinical, ECG, and ionized hypocalcemia) and psychogenic hemiplegia.
- There were no reported complications for this procedure encourage the generalizing use in the psychogenic hemiplegia.
- Further widening the research to include the cases of organic stroke is essential.

**Conflicts of interest**

There are no conflicts of interest.

**Acknowledgment**

- I wish to thank Dr. Mohammed Abu-Al-Soud (MRCP) for his past teaching support. Also, I want to thank my wife for saving time and improving the conditions for supporting me.

**References:**

1. Campbell BCV, Khatri P. (2020). *Stroke. Lancet.*; 396(10244):129-142.
2. Powers WJ, Rabinstein AA, Ackerson T, Adeoye OM, Bambakidis NC, et al. (2019). Guidelines for the Early Management of Patients With Acute Ischemic Stroke: 2019 Update to the 2018 Guidelines for the Early Management of Acute Ischemic Stroke: A Guideline for Healthcare Professionals From the American Heart Association/ Association. *Stroke.*; 50(12):e344-e418.
3. H Buck B, Akhtar N, Alrohim A, Khan K, Shuaib A. (2021). Stroke mimics: incidence, aetiology, clinical features and treatment. *Ann Med.*; 53(1):420-436.



4. Ali SF, Hubert GJ, Switzer JA, Majersik JJ, Backhaus R, et al. (2018). Validating the TeleStroke Mimic Score: A Prediction Rule for Identifying Stroke Mimics Evaluated Over Telestroke Networks. *Stroke*;49(3):688-692.
5. McClelland G, Rodgers H, Flynn D, Price CI. (2019). The frequency, characteristics and aetiology of stroke mimic presentations: a narrative review. *Eur J Emerg Med*. 26(1):2-8.
6. Liberman AL, Prabhakaran S. (2017). Stroke Chameleons and Stroke Mimics in the Emergency Department. *Curr Neurol Neurosci Rep*.; 17(2):15.
7. Behrouz R, Benbadis SR. (2014). Psychogenic pseudostroke. *J Stroke Cerebrovasc Dis*.; 23(4): e243-248.
8. Pal PK. (2011). Electrophysiologic evaluation of psychogenic movement disorders. *J Mov Disord*.; 4(1):21-32.
9. Afolabi K, Ali S, Gahtan V, Gorji R, Li F, Nussmeier NA. (2016). Postoperative conversion disorder. *J Clin Anesth*.; 30:21-23.
10. Baker JHE, Silver JR. (1987). Hysterical paraplegia. *Journal of neurology, Neurosurgery, and Psychiatry*.; 50: 375-382.
11. Boone, K. (2011). Somatoform Disorders, Factitious Disorder, and Malingering. In: Schoenberg, M., Scott, J. (eds) *The Little Black Book of Neuropsychology*. Springer, Boston, MA., pp 551-565.
12. Jones A, O'Connell N, David AS, Chalder T. (2020). Functional Stroke Symptoms: A Narrative Review and Conceptual Model. *J Neuropsychiatry Clin Neurosci*.; 32(1):14-23.
13. Gargalas S, Weeks R, Khan-Bourne N, Sholtbolt P, Simblett S, et al. (2017). Incidence and outcome of functional stroke mimics admitted to a hyperacute stroke unit. *J Neurol Neurosurg Psychiatry*.; 88(1):2-6.
14. Gelauff J, Stone J, Edwards M, Carson A. (2014). The prognosis of functional (psychogenic) motor symptoms: a systematic review. *J Neurol Neurosurg Psychiatry*.; 85(2):220-226.
15. Simhan S, Thijs V, Mancuso S, Tsvigoulis G, Katsanos A, et al. (2020). The outcome of acute functional neurological disorder: a meta-analysis of stroke-mimic presentations. *J Neurol*; 267(5):1353-1357.
16. Popkirov S, Stone J, Buchan AM. (2024). Functional Neurological Disorder: A Common and Treatable Stroke Mimic. *Stroke*.; 51(5): 1026-1042.
17. Ford CV. (2000). Somatoform disorders. In: Ebert MH, *Current diagnosis and treatment in psychiatry*. 1st ed., pp, 366-377. McGraw-Hill, New York.
18. (2019). Haghighi SS. Psychogenic Hemiplegia after Cervical Spine Discectomies and Fusion. *Neurosurg Cases Rev*.;2(016):1-4.
19. Ali SF, Hubert GJ, Switzer JA, Majersik JJ, Backhaus R, et al. (2018). Validating the TeleStroke Mimic Score: A Prediction Rule for Identifying Stroke Mimics Evaluated Over Telestroke Networks. *Stroke*; 49(3):688-692.
20. Gelauff J, Stone J, Edwards M, Carson A. (2014). The prognosis of functional (psychogenic) motor symptoms: a systematic review. *J Neurol Neurosurg Psychiatry*.; 85(2):220-226.
21. Chiappa KH, Ropper AH. (1982). Evoked potentials in clinical medicine (first of two parts). *N Engl J Med*.; 306(19):1140-1150.
22. Haghighi SS, Meyer S. (2001). Psychogenic paraplegia in a patient with normal electrophysiologic findings. *Spinal Cord*; 39(12):664-667.
23. Morota N, Deletis V, Kiproviski K, Epstein F, Abbott R, et al. (1994). The use of motor evoked potentials in the diagnosis of psychogenic quadriplegia. A case study. *Pediatric Neurosurg*.; 20: 203-206.
24. Shell MG, Mitchell HL, Loes MW, Belán AP. (1997). Conversion disorder presenting in a patient with an implantable morphine pump and an epidural abscess resulting in paraplegia. *Arch Phys Med Rehabil*.; 78(2):226-229.
25. Berhane L, Kurman R, Smith S. (1998). Lower extremity paralysis after operative laparoscopy from conversion disorder. A case report. *J Reprod Med*.; 43(9):831-835.
26. Crimlisk HL, Bhatia K, Cope H, David A, Marsden CD, et al. (1998). Slater revisited: 6 year follow up study of patients with medically unexplained motor symptoms. *BMJ*.; 316(7131):582-586.
27. Laraki M, Orliaguet GA, Flandin C, Merckx J, Barrier G. (1996). Hysterical paraplegia as a cause of transient paraplegia after epidural anesthesia. *Anesth Analg*.; 83: 876-877.
28. Rappaport M, Sweeney D, Rappaport ML, Saal J, Wilmot C. (1988). Neuropsychiatric assessment of a spinal cord injury patient with sudden recovery. *Arch Phys Med Rehabil*.; 69(6):455-457.
29. Solyom C, Solyom L. (1990). A treatment program for functional paraplegia/Munchausen syndrome. *J Behav Ther Exp Psychiatry*; 21(3):225-230.
30. Kaplan BJ, Friedman WA, Gravenstein D. (1985). Somatosensory evoked potentials in hysterical paraplegia. *Surg Neurol*. 23(5):502-506.

31. Chastan N, Parain D. (2010). Psychogenic paralysis and recovery after motor cortex transcranial magnetic stimulation. *Mov Disord.*;25(10):1501-1504.
32. Ito A, Nakamoto T, Ohira S, Kamibayashi T. (2020). Postoperative tetraplegia due to conversion disorder upon emergence from general anesthesia. *JA Clin Rep*;6(1):88.