

Radiological Analysis of Post Quality in Post Crown Restoration among a Sample of Population in Sana'a City

Anhar Abdullah Issa ¹, Basheer Hamed Al-Shameri ², Mohsen Ali Al-Hamzi ³, Abdulwahab Ismail Al-Kholani ^{4*}, Manar Abdulsalam Al-Kinani ¹, Nidaa Haseeb Saber ¹

¹ Postgraduate Dental Student, Restorative and Esthetic Dentistry Department, Faculty of Dentistry, Sana'a University, Sana'a, Yemen.

² Assistant professor of Endodontic, Restorative and Esthetic Dentistry Department, Faculty of Dentistry, Sana'a University, Republic of Yemen.

³ Associate professor of Restorative Dentistry, Fixed Prosthodontics, Restorative and Esthetic Dentistry Department, Faculty of Dentistry, Thamar University, Yemen.

⁴ Professor of Restorative Dentistry, Dental Implant consultant, Restorative and Esthetic Dentistry Department, Faculty of Dentistry, Sana'a University, Sana'a, Yemen

***Corresponding Author:** Abdulwahab Ismail Al-kholani, Dean of Faculty of Dentistry on 21 September University, Yemen, Head of Restorative and Esthetic Dentistry Department, Dental Implant Consultant.

Received date: September 23, 2024; **Accepted date:** November 04, 2024; **Published date:** November 27, 2024

Citation: Anhar A. Issa, Al-Shameri BH, Mohsen Ali Al-Hamzi, Abdulwahab Ismail Al-Kholani, Al-Kinani MA, et al, (2024), Radiological Analysis of Post Quality in Post Crown Restoration among a Sample of Population in Sana'a City, *J Clinical Research and Reports*, 17(2); DOI:10.31579/2690-1919/414

Copyright: © 2024, Abdulwahab Ismail Al-kholani. This is an open access article distributed under the Creative Commons Attribution License, which permits unrestricted use, distribution, and reproduction in any medium, provided the original work is properly cited.

Abstract

Introduction: Endodontically treated teeth require restoration to ensure long-term survival and function. Proper post-space preparation is crucial for successful restoration.

Material and Methods: A retrospective study was conducted using digital periapical radiographs of endodontically treated teeth (ETT) restored with posts in Sana'a City. Three hundred and fifty-two radiographs were included in the analysis. The following information was extracted from each image: Tooth characteristics: Type, number, and jaw involvement. Post characteristics: Shape, length about root and crown length, width about root width, and length in bone. Gutta-percha (GP) characteristics: Presence of space between GP and post, length of remaining GP in canals, and extension beyond root apices. Root canal treatment quality: Overall assessment. Statistical analysis was performed using SPSS. Descriptive statistics were generated, and the association between different variables was evaluated using the chi-square test at a significance level of $p < 0.05$.

Result: Posts were used to restore maxillary and mandibular teeth equally (49.7%, 50.3%). Prefabricated parallel metal posts were the most used (58%), followed by posts placed in premolars (41.2%). Adherence to prosthetic guidelines was poor. Only 25.3% of posts had a width equal to one-third of the root width. Post length was rarely two-thirds of the root length (5.1%), and often exceeded crown height (61.9%). In 73.6% of cases, there was no space between the gutta-percha (GP) and the post. The remaining GP length was 3–5 mm in 27.9% of cases. These findings highlight the need for improved adherence to prosthetic guidelines in endodontic treatment.

Conclusion: To enhance the quality of post-crown restorations, dentistry schools, and private clinics should implement a controlled academic supervisory environment and a rigorous scientific approach to fixed prosthodontics. This would ensure that radiographically evaluated restorations meet the highest standards of care.

Keywords: post and core; post length; post width; post shape; gutta-percha length; digital periapical image

Introduction

Restoring endodontically treated teeth (ETT) is crucial for long-term success and survival of the teeth 1. To successfully restore ETT, the surviving tooth must be protected, the coronal seal must be effective, the function must be restored, and the aesthetics must be acceptable.2

Nowadays dental clinicians understand “The naturally retained root is the ultimate dental implant”. The ETT with extensive loss of tooth substance have multiple problems due to significant reduction in the capability to resist a myriad of functional forces 2.

Fracture is one of the major incidences encountered in ETT. It was found that the risk of fracture of ETT is 3 to 4 times more than vital teeth³. The fracture resistance of ETT has been reported to be principally dependent on the amount of the remaining tooth structure, the amount of adhesive surface, and the quality of adhesion⁴.

When endodontic treatment is conducted on compromised teeth whether badly decayed, heavily restored, or fractured, the mechanical integrity is affected. Access cavity preparation, dentin removal for standard endodontic treatment procedures, and optimal preparation for subsequent restorative treatment can influence the mechanical integrity of the tooth. To repay for such weakness, different materials and techniques have been introduced in terms of modern principles of post and core utilization⁵.

Post and core systems are mostly used to restore ETT with extensive loss of structure⁶. A post is indicated when there is inadequate remaining coronal tooth structure to retain a core to ensure the success of the future indirect restoration⁷. Posts can protect teeth from fracture by dissipating or distributing forces along the tooth⁸. Posts are also indicated to intensify the retention of the amalgam and composite core. However, not all ETT require a post⁹, and since posts do not reinforce such teeth¹⁰ their use have to be limited to those with inadequate tooth structure. In addition, preparing space for the post is associated with some risk⁹. Even rare, the risk includes perforation in the apical portion of the root or into the lateral fluted areas of the mid-root, called "strip perforation"¹¹. The causes for the failures of the post root canal restorations mostly are root fracture, microleakage, metal corrosion, decementation, and concentration of the forces¹².

The most common types of fractures in post-retained restorations are root fracture, loosening of the post and fracture of the post¹³. Root fractures are most frequently unrestorable, which subsequently results in the extraction of tooth¹³.

A numerous post and core systems have been investigated till date for the restoration of the root canal treated tooth. In fact, post failure and prosthetic failure have been cited as the most common cause of failure in ETT¹⁴. The ETT supported with post and core was considered as a regular procedure in dental practice. Many criteria have been suggested to assess the quality of post and core restorations. Most of these criteria are dependent mainly on radiographic evaluation alone or in combination with clinical examination¹⁵.

The outcomes of post and core restorations in the prosthetic treatment plan depend on the success of every treatment phase. Hence, radiographic assessment must be performed as follows: Before post insertion to check of root canal treatment system seal, after cementation, during follow-up after teeth exposure to masticatory loading forces, and monitoring during maintenance recall to evaluate the treatment method according to data supplied by specialized literature references¹⁶.

Materials and Methods

This cross-sectional study was conducted in Sana'a, Yemen, and was approved by the Research Ethics Committee of the Faculty of Dentistry at Sana'a University. Digital periapical radiographs of 352 posts restoring endodontically treated teeth (ETT) were collected from public and private universities, dental X-ray centers, and clinics. Radiographs with inadequate diagnostic quality were excluded.

Using ImageJ software (1.53e), the radiographs were resized and measured according to predefined criteria. Pixel measurements were converted to millimeters using a calibration based on the known dimensions of the radiographic film. Data for each sample were recorded in a standardized form.

The data were collected and recorded in an Excel spreadsheet. The term "ideal" was assigned to data that adhered to the guidelines outlined in Table 1. The following parameters were evaluated:

- Involved jaw
- Tooth type
- Post type
- Post shape
- Post diameter
- Post length
- Residual GP length
- Space between GP and post

Post diameter	Equal to 1/3 of the root width
Post length related to the root length	Equal to 2/3 of root length
Post length related to the crown height	Equal to or more than crown height
Length of the remaining gutta-percha	Range 3–5 mm in length
The space between the post end and root canal filling	No space present

Table 1: Principal Guidelines for Post-Space Preparation

Statistical analysis was performed using SPSS software (version 21). Descriptive statistics were generated, and the association between different variables was determined using the chi-square test at a significance level of 0.05.

Results

A retrospective study analyzed 352 postoperative periapical radiographs of endodontically treated teeth in Sana'a, Yemen. The sample was evenly distributed between the maxillary and mandibular arches. Prefabricated metal posts were the most common (58%), followed by prefabricated fiber posts (38%). Only 4% were custom-made. Most posts (58.2%) were parallel-sided, while the remaining were tapered (41.8%). Premolars were most frequently restored with posts (41.2%), followed by molars and anterior teeth (36.6% and 22.2%, respectively).

Posts were evaluated based on ideal prosthetic criteria. Results showed that:

- 25.3% had a post diameter equal to one-third of the root diameter.
- 5.1% had a post length equal to two-thirds of the root length.
- 61.9% had a post length equal to or greater than the crown height.
- 73.6% had no space between the gutta-percha (GP) and post.
- 27.9% had a remaining GP length of 3-5 mm.

The analysis revealed that many restored ETT in Sana'a had short posts less than two thirds of the root lengths, some of them with gaps between the post and the crown. Most post widths were less than one-third of the root. Post-crown lengths frequently equal or more than crown height. A significant number of cases had a GP length more than 5 mm. These

findings highlight common prosthetic design shortcomings in the region and suggest areas for improvement.

Post criteria		Frequency	Percentage
Arch	Maxillary Arch	175	49.7%
	Mandibular Arch	177	50.3%
	Total	352	100%
Type of tooth	Anterior tooth	78	22.2%
	Premolar tooth	145	41.2%
	Molar tooth	129	36.6%
	Total	352	100%
Type of post	Custom-made	14	4%
	Prefabricated fiber	134	38%
	Prefabricated metal	204	58%
	Total	352	100%
Shape of post	Parallel	205	58.2%
	Tapered	147	41.8%
	Total	352	100%

Table 2: Post Frequency and Percentage of Arch, Type of Tooth, Type of Post, Shape of Post.

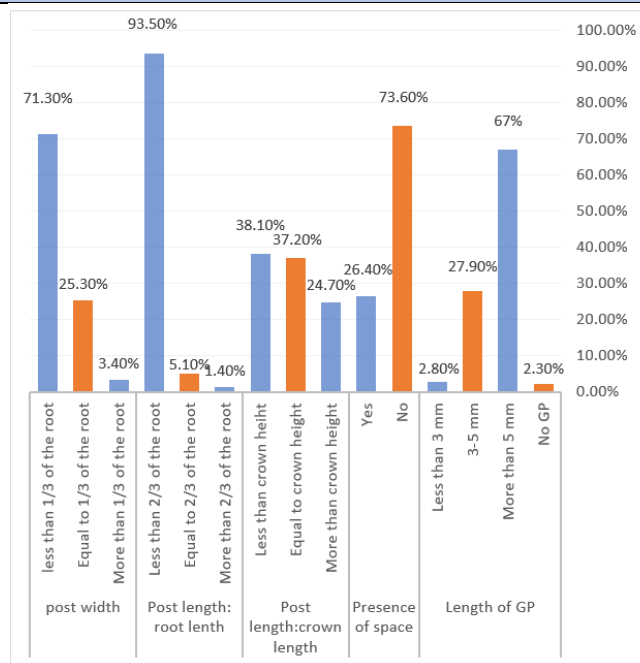


Figure 1: Percentage of prosthetic criteria analyzed (n=352).

The evaluation of endodontically treated teeth (ETT) restored with post and core restorations is contingent upon specific criteria assessed both clinically and radiographically. This study focused solely on radiographic assessment using digital periapical images. Maxillary and mandibular teeth were restored with posts in a nearly balanced distribution, contradicting previous findings that favored maxillary teeth. Premolars were the most frequently restored teeth, aligning with many studies. Prefabricated metal posts were the most common, followed by prefabricated fiber posts. This differs from studies reporting a predominance of prefabricated fiber posts. Custom-made posts were rarely used, suggesting their obsolescence. Parallel posts were more prevalent than tapered posts, contrary to some studies. The majority of post widths were less than one-third of the root diameter, aligning with some studies but diverging from others. Post length was often less than the recommended 2:3 ratio to root length, potentially due to post type. A significant proportion of posts were at least as long as the crown height. Most cases had adequate GP retention, with less than 3 mm remaining in

only a few. Most cases exhibited no gap between the post and the remaining GP, although some had gaps ranging from 0.2 mm to 5.1 mm. The discrepancies observed in this study compared to previous research may be attributed to factors such as sample size, operator expertise, post type, and the specific criteria used for evaluation. The balance between maxillary and mandibular teeth might reflect a shift in treatment preferences or regional variations. The prevalence of metal posts could be due to cost, availability, or perceived strength. The preference for parallel posts might be related to perceived retention or ease of fabrication. Inadequate post preparation or a focus on preserving remaining dentin could contribute to smaller post diameters. The shorter post lengths might be influenced by concerns about apical seal or root strength. The high percentage of adequate GP retention suggests a cautious approach to endodontic treatment.

Conclusion

The findings of this study highlight the variability in post and core restoration practices. A standardized approach, emphasizing proper post

preparation, selection, and placement, is essential to ensure the long-term success of these restorations. Further research is needed to establish evidence-based guidelines for post and core treatment.

References

- Shillingburg HT, Hobo S, Whitsett LD. 1997. *Fundamentals of fixed prosthodontics*. Chicago: Quintessence Publishing Co, p.194-206.
- Yalcin E, Cehreli MC, Canay S. 2005. Fracture resistance of cast metal and ceramic dowel and core restorations: A pilot study. *Journal of Prosthetic Dentistry*, 14, 84-90.
- McComb D. 2008. Restoration of the endodontically treated tooth: an online study guide. *Journal of Endodontics*, 34, e187–e190.
- Dietschi D, Duc O, Krejci I, Sadan A. 2007. Biomechanical considerations for the restoration of endodontically treated teeth: a systematic review of the literature—Part 1. Composition and micro- and macrostructure alterations. *Quintessence International*, 38, 733-743.
- Şişmanoğlu S. 2020. Restoration of endodontically treated teeth: a review of direct restorative approach. *Aurum Journal of Health Sciences*, 2, 21-40.
- Sorrentino R, Di Mauro MI, Ferrari M, Leone R, Zarone F. 2016. Complications of endodontically treated teeth restored with prefabricated fiber post posts and single crowns or fixed dental prostheses—a systematic review. *Clinical Oral Investigations*, 20, 1449–1457.
- Morgano SM, Brackett SE. 1999. Foundation restorations in fixed prosthodontics: current knowledge and future needs. *Journal of Prosthetic Dentistry*, 82, 643-657.
- Makade CS, Meshram GK, Warhadpande M, Patil PG. 2011. A comparative evaluation of fracture resistance of endodontically treated teeth restored with different post core systems: An in-vitro study. *Journal of Advanced Prosthodontics*, 3, 90-95.
- Schwartz RS, Robbins JW. 2004. Post placement and restoration of endodontically treated teeth: A literature review. *Journal of Endodontics*, 30, 289-301.
- Morgano SM. 1996. Restoration of pulpless teeth: Application of traditional principles in present and future contexts *Journal of Prosthetic Dentistry*, 75, 375-380.
- Mahmoud T, Walton RE. 2009. *Endodontics: Principles and Practice*. 4th ed. St. Louis, MO: Saunders, 322-339.
- Shashikala K, Sharma S. 2011. Clinical and radiological evaluation of cast metal and quartz prefabricated fiber post posts in endodontically restored teeth. *Endodontology*, 3, 37-46.
- Peutzfeldt A, Sahafi A, Asmussen E. 2008. A survey of failed post-retained restorations. *Clinical Oral Investigations*, 12, 37-44.
- Bateman G, Ricketts DN, Saunders WP. 2003. Fibre based post systems: A review. *British Dental Journal*, 19, 43-48.
- Ferrari M, Vichi A, Fadda GM, Cagidiaco MC, Tay FR, Breschi L. 2012. A Randomized Controlled Trial of Endodontically Treated and Restored Premolars. *Journal of Dental Research*, 91, S72-S78.
- Weaver RG, Haden NK, Valachovic RW. 2004. Annual ADEA survey of dental school seniors: 2003 graduating class. *Journal of Dental Education*, 68, 1004-1027.
- Jamani KD, Aqrabawi J, Fayyad MA. 2005. A radiographic study of the relationship between technical quality of coronoradicular posts and periapical status in a Jordanian population. *Journal of Oral Science*, 47, 123-128.
- Al-Hamad KQ, Al-Omari M, Al-Wahadni A, et al. 2006. Radiographic assessment of post-retained crowns in an adult Jordanian population. *The Journal of Contemporary Dental Practice*, 7, 29-36.
- Nimigean VR, Butincu L, Nimigean V. 2012. A radiographic study regarding post retained restorations. *Romanian Journal of Morphology and Embryology*, 53, 775-779.
- Meshni A, Mattoo KA, Halboub E. 2018. Radiographic evaluation of post–core restorations fabricated by dental students at Jazan University. *The Journal of Contemporary Dental Practice*, 19, 66-72.
- Almutairi AR, Mathar MI. 2020. Radiographic assessment of the quality of post & core restorations performed by dental students at Qassim University dental clinics. *Integrative Journal of Medical sciences*, 7.
- Almaghrabi J, Alhanoof A, attar E, Alshali S. 2022. Radiographic Analysis of Posts Performed by Undergraduate Dental Student: A Cross-Sectional Study. *Clinical, Cosmetic and Investigational Dentistry*, 14, 37-43.
- Alshehri T, Aly N, Altayyar R, Alghamdi D, Alotaibi Sh, Ellakany P. 2023. Radiographic assessment of dental post and core placement at different educational levels in an undergraduate student clinic: a 4-year retrospective study. *F1000 research*, 12, 976.
- Bafail A, Algarni A, Abuljadayel J, Hawsawi R, Alsulaimani M, Sharbib Sh, Baik A, Hamadallah H, Mirah M. 2024. Evaluation of Students' Proficiency in Removing Gutta-Percha Prior to Fiber Post Placement: A Retrospective Study. *Cureus*, 16, e57203.
- Almansour MI, Madfa AA, Alotaibi AN, Alturki RT, Alshammari AF. 2024. Radiographic assessment of the quality of post and core restorations performed by general dental practitioners in Saudi Arabia Heliyon, 10, e31637.
- Alshehri AH, Alhendi KD, Almnea RA, Alelyani AA, Gadah TS, Al Ahmari NM, Alshahrani AS, Al Moaleem MM, Boreak N, Thubab AY. 2024. Radiographic 18 Performed by 6th-Year Dental Students During the 2022-2023 Academic Year at the College of Dentistry, Jazan University, Saudi Arabia. *Medical Science Monitor*, 30, e943436.25,26
- Baik KM. 2023. Quality of post and core placement by final year undergraduate dental students. *PLoS ONE*, 18, e0294073.
- McComb, D. 2008. *Ensuring continued trust. Restoration of the endodontically treated teeth*. London: Quintessence, pp. 1-19.
- Minguini ME, Mantovani MB, Lolli LF, Silva CO, Progiante P, Marson FC. 2014. Estudo clínico de pinos intrarradiculares diretos e indiretos em região anterior. *Uningá Review*, 20, 15-20.
- Vital RA, Ribeiro JS, Rocha SS. 2015. Evaluation of the pattern dimensions of cast-metal posts in uniradicular teeth. *Revista de Odontologia da UNESP*, 44, 99-102.
- Mendonça CG, Almeida JRVD 2, Takeshita WM, et al. 2017. Radiographic analysis of 1000 cast posts in Sergipe state, Brazil. *Revista de Odontologia da UNESP*, 46, 255-260.
- Fokkinga WA, Kreulen CM, Bronkhorst EM, Creugers NH. 2007. Up to 17-year controlled clinical study on post-and-cores and covering crowns. *Journal of Dentistry*, 35, 778-786.
- Souza EM, Pappen FG, Leonardi DP, Flores VO, Berbert FLCV. 2007. O papel da anatomia radicular na colocação de pinos pré-fabricados: uma visão endodôntica. *RGO (Porto Alegre)*, 55, 77-82.
- McLean A. 1998. Predictably restoring endodontically treated teeth. *Journal of the Canadian Dental Association*, 64, 782-787.
- Grieve AR, McAndrew R. 1993. A radiographic study of post-retained crowns in patients attending a dental hospital. *Brazilian Dental Journal*, 174, 197-201.



This work is licensed under Creative Commons Attribution 4.0 License

To Submit Your Article Click Here: **Submit Manuscript**

DOI:[10.31579/2690-1919/414](https://doi.org/10.31579/2690-1919/414)

Ready to submit your research? Choose Auctores and benefit from:

- fast, convenient online submission
- rigorous peer review by experienced research in your field
- rapid publication on acceptance
- authors retain copyrights
- unique DOI for all articles
- immediate, unrestricted online access

At Auctores, research is always in progress.

Learn more <https://www.auctoresonline.org/journals/journal-of-clinical-research-and-reports>