

# Acute Pancreatitis Complicated by Disturbed Consciousness Rare Mode of Revelation of Hyperparathyroidism Secondary to Parathyroid Adenomas

N. Belhaj <sup>1\*</sup>, R. Bencheikh <sup>1</sup>, M.A. Benbouzid <sup>2</sup>, L. Houassaini. Essakalli <sup>3</sup>

<sup>1</sup>CHR Guelmim; ENT department. Morocco.

<sup>2</sup>ENT Department CHU ibn sina Rabat. Morocco.

\*Corresponding Author: N. Belhaj, CHR Guelmim; ENT department. Morocco.

Received Date: May 14, 2024 | Accepted Date: October 01, 2024 | Published Date: November 16, 2024

**Citation:** Belhaj N, Bencheikh R, M.A. Benbouzid, L. Houassaini. Essakalli, (2024), Acute pancreatitis complicated by disturbed consciousness rare mode of revelation of hyperthyroidism secondary to parathyroid adenomas, *International Journal of Clinical Case Reports and Reviews*, 19(4); DOI:10.31579/2690-4861/473

**Copyright:** © 2024, N. Belhaj. This is an open-access article distributed under the terms of the Creative Commons Attribution License, which permits unrestricted use, distribution, and reproduction in any medium, provided the original author and source are credited.

## Abstract:

Hypercalcemia of primary hyperparathyroidism associated with acute pancreatitis is a rare entity it was described in 1 to 9% of the series; This entity has peculiarities and diagnostics; Therapeutics and prognostics; In this work, we report the observation of a 54-year-old patient admitted to intensive care for a disturbance conscience on acute pancreatitis whose origin is hypercalcemia following hyperparathyroidism of the parathyroid adenoma. After the removal of the two parathyroid adenomas, the evolution was well.

**Key words:** hypercalcemia; hyperparathyroidism; pancreatitis

## Introduction

The two main etiologies of acute pancreatitis are the migration of a stone and alcohol; the other causes are genetic; malformative, tumorous, drug-induced and metabolic (hyperlipidemia, hypercalcemia) [1,2]. its incidence is in the range of 3.5 to 4.8% and most patients with primary hyperparathyroidism (PTH 1) are mildly symptomatic. [3,4]

The aim of this work is to report that primary hyperparathyroidism is a rare cause of acute pancreatitis but should be routinely investigated in the presence of any acute pancreatitis, when

There is no obvious cause.

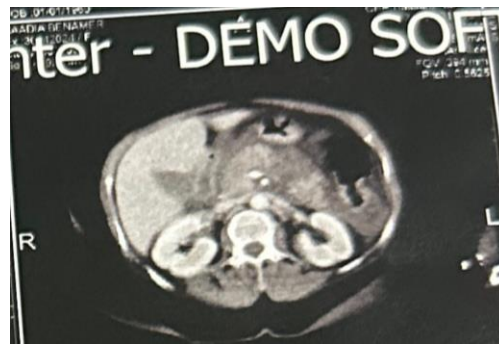## Observation:

This is a 57-year-old patient with no particular history who presented two weeks prior to admission with a picture of vomiting associated with abdominal pain; The patient admitted to a picture of disturbance of consciousness with a GCS of 8 reason she was intubated and admitted to intensive care

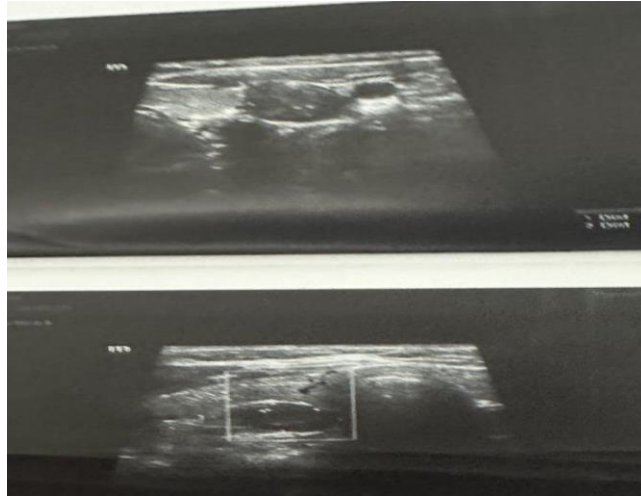
The hydroelectrolytic balance was normal and the pancreatic test showed lipasemia 8 times normal with a phospholipid profile that objectified a serum calcium level of 240 and a hyperparathyroidism of 1200; The rest of the biologic workup was normal.

A requested abdominal CT scan showed stage E pancreatitis of balthazar with peripancreatic ; perisplenic FLUID infiltration and at the level of the parietocolic gutters without stones or dilation visible in the intrahepatic and main bile ducts (Figure 1) with on cervical ultrasound two inferior retrothyroid nodular formations measuring on the right 15.5/15.2mm and left 22/16.8/13mm ovals with irregular contours in places, strongly hypoechoic, site of microcalcifications and vascularized in doppler (figure2); The rest of the thyroid parenchyma was normal in appearance and volume.

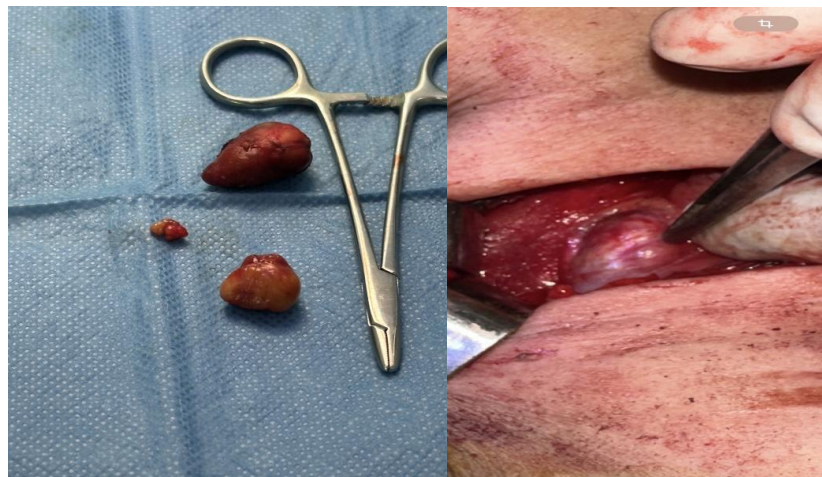Management included rehydration (4l/D); symptomatic treatment of diuretics and corticosteroids and admitted to the operating room for removal of both parathyroid formations under general anesthesia (figure 3.4); Postoperatively, the serum calcium level decreased to 90 and the patient was extubated with good clinical improvement.



**Figure 1:** abdominal CT scan showed stage E pancreatitis of Balthazar



**Figure 2:** cervical ultrasound two inferior retrothyroid nodular formations measuring on the right 15.5/15.2mm and left 22/16.8/13mm ovals with irregular contours in places, strongly hypoechoic, site of microcalcifications and vascularized in doppler (figure 2); The rest of the thyroid parenchyma was normal in appearance and volume.



**Figure 3.4:** Peroperative image of the parathyroid mass on the left, the image of the two removed parathyroid formations

### Discussion:

In the literature, acute pancreatitis is associated with PTH 1 in 0-13% of cases. Several groups believe that the association between pancreatitis and hyperparathyroidism is not coincidental and that there is a causal link between these conditions, although there is no formal experimental evidence [3,5,6—10]. Only Bess et al. [5] remain skeptical about their interaction. It is now well established that a high level of serum calcium

is the most important element in the development of acute pancreatitis. This is the main predictor of acute pancreatitis in the literature [5,6,7].

The pathophysiology of pancreatitis has given rise to many controversies, which are still relevant today. It is now accepted that pancreatitis is a consequence of hyperparathyroidism, rather than the opposite, as was suggested in the 1950s. Indeed, it is unlikely that glucagon hypersecretion leading to hypocalcemia would cause reactive parathyroid hyperplasia. Proye et al [8] reviewed 403 patients operated on for HPT 1. Of these, 14

had associated acute pancreatitis [3.5.10], which was consistent with published data. Two main hypotheses were proposed to demonstrate the causal link. On the one hand, hypercalcemia could cause local DIC leading to necrotizing and hemorrhagic lesions, inducing pancreatitis. On the other hand, hypercalcemia could lead to a higher concentration of ionized calcium in the pancreatic juice. By precipitating in this alkaline environment, calcium could activate the transformation of inactive trypsinogen into active trypsin, triggering autodigestion of the gland. Neither hypothesis has been validated experimentally. Prinz and Aranha [8] hypothesized that hypercalcemia would lead to a higher concentration of ionized calcium in the pancreatic juice, which would then precipitate in the alkaline medium to form lithiasis, causing upstream pancreatitis. These hypotheses are all the more plausible in that pancreatitis has been reported in patients with hypercalcemia secondary to multiple myeloma or vitamin D intoxication (unpublished personal observation [9.10], even after hypercalcemia-inducing parenteral nutrition [11.10]. Only patients with hypercalcemia developed acute pancreatitis. The role of hypercalcemia in the onset of acute pancreatitis therefore appears important for both hypotheses.

A third mechanism has been suggested, involving the direct toxic action of parathyroid hormone on the pancreas. Van Lanschot and Bruining, in 1984 [12], posed the question of the direct role of this hormone. Hypersecretion of parathyroid hormone would cause microthrombi in the organs, leading to pancreatic necrotic lesions. However, this hypothesis does not explain why chronic dialysis patients, who often have elevated

parathyroid hormone levels, do not suffer more acute pancreatitis than the general population [2]. Nor does this hypothesis explain acute pancreatitis due to vitamin D intoxication [10.11]. Finally, the similar level of parathyroid hormone in this study does not support a direct role for this hormone in the mechanism of acute pancreatitis.

In 1982, Layer et al. experimentally studied the effect of chronic hypercalcemia on the pancreatic juices of cats [10.12.13]. They concluded that chronic hypercalcemia did not stimulate pancreatic enzymes when calcium was injected intravenously. More recently, Felderbauer et al. suggested a genetic risk factor, such as mutations in the serine protease inhibitor Kasal type 1 (SPINK 1) and CFTR genes [6.7.8].

SPINK 1 is a natural inhibitor of the trypsinogen, and mutations in this gene have been reported in some cases of pancreatitis. Mutations in the CFTR gene are responsible for cystic fibrosis.

Some mild CFTR mutations are responsible for attenuated forms of the disease with moderate pancreatic involvement. It is conceivable that such genetic mutations could be a favourable breeding ground for the development of acute pancreatitis in the presence of another triggering factor, such as hypercalcemia. [[10.13.14.15.16.17]

## Conclusion

In conclusion, this work confirms the possibility of a causal link between HPT 1 and acute pancreatitis. It also confirms the importance of hypercalcemia on the incidence of acute pancreatitis. The pathophysiology of this association is not yet well understood. HPT 1, which is a curable cause of acute pancreatitis, should be systematically investigated in all cases of acute pancreatitis.

## References

1. Kusnierz-Cabana B, Kedra B, Sierzega M. (2003). Currents concepts on diagnosis and treatment of acute pancreatitis. *Adv Clin Chem*; 37:47—81.
2. Biour M, Daoud H, Ben Salem C. (2005). Pancréatotoxicité des médicaments. Seconde mise à jour du fichier bibliographique des atteintes pancréatiques et des médicaments responsables. *Gastroenterol Clin Biol*; 29:353-359.
3. Carnaille B, Oudar C, Pattou F, Combemale F, Rocha J, et al., (1998). Pancreatitis and primary hyperparathyroidism: forty cases. *ANZ J Surg*; 68:117—119.
4. [10]Felderbauer P, Karakas E, Fendrich V, et al. (2008). Pancreatitis risk in primary hyperparathyroidism: relation to mutations in the SPINK 1 trypsin inhibitor (N34S) and the cystic fibrosis gene. *Am J Gastroenterol*; 103:368—374.
5. Bess MA, Edis AJ, Van Heerden JA. (1980). Hyperparathyroidism and pancreatitis. Chance or causal association? *JAMA*; 18:246—247.
6. Prinz RA, Aranha GV. (1985). The association of primary hyperparathyroidism and pancreatitis. *Am Surg*; 51:325—329.
7. Proye C, Marmousez T, Tiry P, et al. Pancréatites et hyperparathyroïdie primaire. *Chirurgie* 1986;112:221—225.
8. Sarfati E, Assens P, de Ferron P, Jadat R, Dubost C. (1986). Pancréatite aiguë et hyperparathyroïdie aiguë. *Gastroenterol Clin Biol*; 10:189—190.
9. Shepherd JJ. (1996). Hyperparathyroidism presenting as pancreatitis or complicated by postoperative pancreatitis. *ANZ J Surg*; 66:85—87.
10. Pancréatite aiguë et hyperparathyroïdie primaire: étude multicentrique de l'Association francophone de chirurgie endocrinienne.0021-7697/\$ — see front matter © 2009 Elsevier Masson SAS. Tou's droits réservés.C. Curtoa, C. Caillarda, T. Desurmontb, F. Sebagc, doi: 10.1016/j.jchir.2009.06.016
11. Calzada-Nocaudie M, Chanson P, Conte-Devolx B, et al. Prise en charge de l'hyperparathyroïdie primaire asymptomatique. *Ann Endocrinol (Paris)* 2006; 67:7—12.
12. Caillard C, Sebag F, Mathonnet M, et al. (2007). Prospective evaluation of quality of life (SF-36v2) and nonspecific symptoms before and after cure of primary hyperparathyroidism (1-year follow-up). *Surgery*; 141:153—159.
13. Jacob J, John M, Thomas N, et al. (2006). Does hyperparathyroidism cause pancreatitis? A South Indian experience and a review of published work. *ANZ J Surg*; 76:740—744.
14. Knackstedt C, Winograd R, Koch A, Abuzahra F, Trautwein C, Wasmith HE. (2007). Acute necrotic pancreatitis induced by severe hypercalcaemia due to tacalcitol ointment. *Br J Dermatol*; 156:576—577.
15. Moshe Izsak E, Shike M, Roulet M, Jeejeebhoy KN. (1980). Pancreatitis in association with hypercalcemia in patients receiving total parenteral nutrition. *Gastroenterology*;79: 555—558.
16. Van Lanschot JB, Bruining HA. (1984). Primary hyperparathyroidism and pancreatitis. *Neth J Surg*; 36:38—41.
17. Layer P, Hotz J, Schmitz-Moormann HP, Goebell H. (1982). Effects on experimental chronic hypercalcemia on feline exocrine pancreatic secretion. *Gastroenterology*;82: 309—316.



This work is licensed under Creative Commons Attribution 4.0 License

To Submit Your Article Click Here: [Submit Manuscript](#)

**DOI:10.31579/2690-4861/473**

**Ready to submit your research? Choose Auctores and benefit from:**

- fast, convenient online submission
- rigorous peer review by experienced research in your field
- rapid publication on acceptance
- authors retain copyrights
- unique DOI for all articles
- immediate, unrestricted online access

At Auctores, research is always in progress.

Learn more <https://auctoresonline.org/journals/international-journal-of-clinical-case-reports-and-reviews>