

# Explosion of cecum with melena in a neglected acute appendicitis: A case report

Ahmad Reza Shahraki <sup>1\*</sup>, Elham Shahraki <sup>2</sup>, Elahe Shahraki <sup>3</sup>

<sup>1</sup>General Surgeon, Department of Surgery, Medical Faculty, Zahedan University of Medical Sciences and Health Services, Zahedan, Iran.

<sup>2</sup>Associated professor of nephrology, Department of Internal medicine, Nephrologist, Ali Ibne Abitaleb Hospital, Zahedan University of medical Sciences, Zahedan, I.R. Iran.

<sup>3</sup>Dentist, Dental faculty, Zahedan University of Medical Sciences and Health Services, Zahedan, Iran.

**\*Corresponding Author:** Ahmad Reza Shahraki, General Surgeon, Department of Surgery, Medical Faculty, Zahedan University of Medical Sciences and Health Services, Zahedan, Iran.

**Received Date:** July 05, 2024; **Accepted Date:** July 12, 2024; **Published Date:** July 19, 2024

**Citation:** Ahmad Reza Shahraki, Elham Shahraki, Elahe Shahraki, (2024), Explosion of cecum with melena in a neglected acute appendicitis: A case report, *Clinical Medical Reviews and Reports*, 6(6); DOI:10.31579/2690-8794/221

**Copyright:** © 2024, Ahmad Reza Shahraki. This is an open access article distributed under the Creative Commons Attribution License, which permits unrestricted use, distribution, and reproduction in any medium, provided the original work is properly cited.

## Abstract

Acute appendicitis is the most common presentation of the acute abdomen in the UK. Although in most cases this is an easily reached diagnosis, presentation is not always typical and there are certain other conditions which may mimic appendicitis. Diagnostic adjuncts usually provide the additional information required to make a confident diagnosis; however, in some circumstances, the safest and most reliable course of action is appropriate surgical intervention. Acute appendicitis is the most common presenting condition of the acute abdomen. In the vast majority of cases, the diagnosis is reached on accurate history taking and thorough clinical examination alone without the need of diagnostic adjuncts. Furthermore, if the diagnosis is proving to be troublesome, repeated clinical examination and monitoring of the patient's condition during a period of observation will usually direct the clinician to the correct diagnosis. However, this is not always the case and particular age groups and the sex of the patient may lead to atypical presentations. Blood tests and radiological imaging may provide further clues, but it is only through surgical intervention that confirmation of the diagnosis can be made confidently. Appendicitis is a common disease, and as we have improved in early diagnosis and management of this disease process, late stage complications have become extremely rare, but can have indolent presentations.

Our case was a 22 years male with 7 days abdominal pain and referred to surgery part with peritonitis that we do surgery for him and in laparotomy we find Explosion of cecum with melena in a neglected acute appendicitis and septic shock that we do DCS surgery and discharge him healthy after right hemicolectomy. Acute appendicitis is a common cause of acute abdominal pain requiring urgent surgery. Despite characteristic clinical signs, diagnosis can be challenging, leading to unnecessary appendectomies. However, the source of appendix bleeding is very rare. It is important to distinguish appendiceal bleeding from lower gastrointestinal bleeding and to treat it as soon as possible with less invasiveness.

**Keywords:** appendicitis; complicated appendicitis; case report; appendectomy; acute abdomen; lower gastrointestinal bleeding; appendix bleeding

## Introduction

Acute appendicitis is the most common presentation of the acute abdomen in the UK. Although in most cases this is an easily reached diagnosis, presentation is not always typical and there are certain other conditions which may mimic appendicitis. Diagnostic adjuncts usually provide the additional information required to make a confident diagnosis; however, in some circumstances, the safest and most reliable course of action is appropriate surgical intervention [1]. Acute appendicitis is the most common

presenting condition of the acute abdomen. In the vast majority of cases, the diagnosis is reached on accurate history taking and thorough clinical examination alone without the need of diagnostic adjuncts. Furthermore, if the diagnosis is proving to be troublesome, repeated clinical examination and monitoring of the patient's condition during a period of observation will usually direct the clinician to the correct diagnosis. However, this is not always the case and particular age groups and the sex of the patient may lead

to atypical presentations. Blood tests and radiological imaging may provide further clues, but it is only through surgical intervention that confirmation of the diagnosis can be made confidently [1]. Appendicitis is a common disease, and as we have improved in early diagnosis and management of this disease process, latestage complications have become extremely rare, but can have indolent presentations [3]. While a ruptured appendicitis can result in an intra-abdominal abscess, peritonitis, and/or shock, the development of a pyogenic hepatic abscess is extremely rare [4].

### Case presentation:

Our case was a 22 years old male with Abdominal pain and acute abdomen presentation that we admit him and hydrate him and do Laparotomy for him. We find Explosion of cecum (figure 1) with melena (figure 2) in a neglected acute appendicitis.

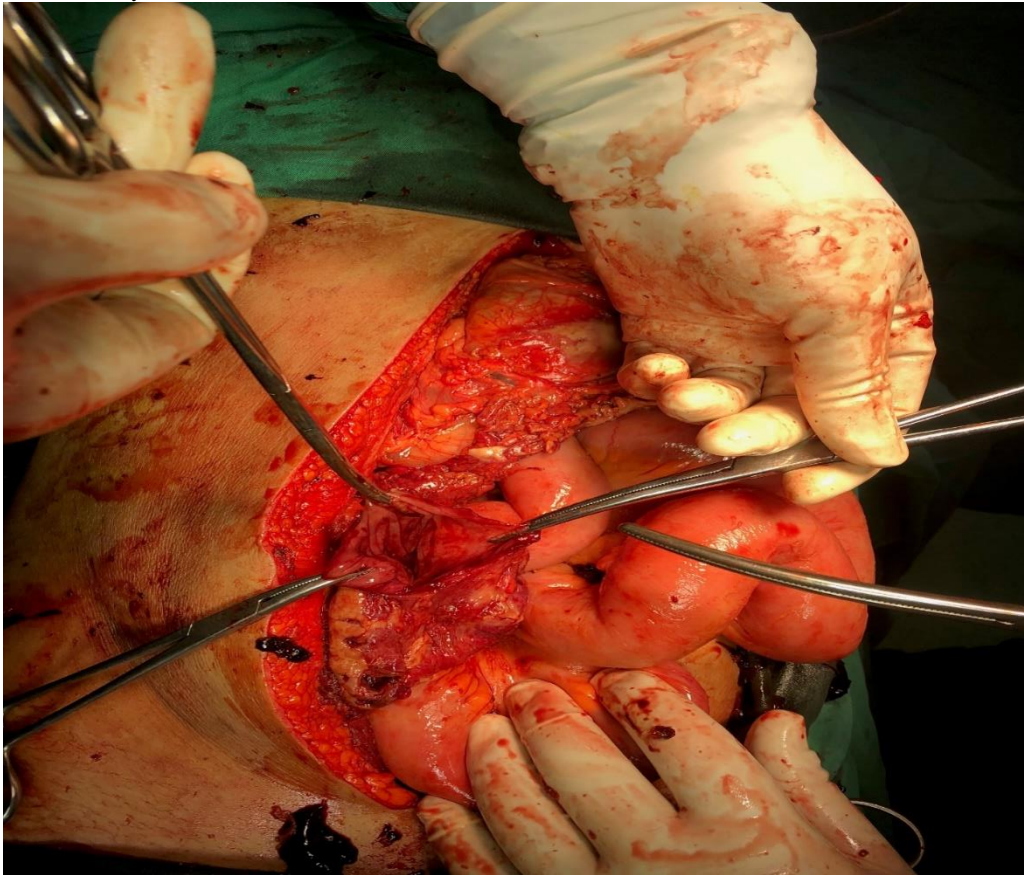


Figure 1: cecal explosion

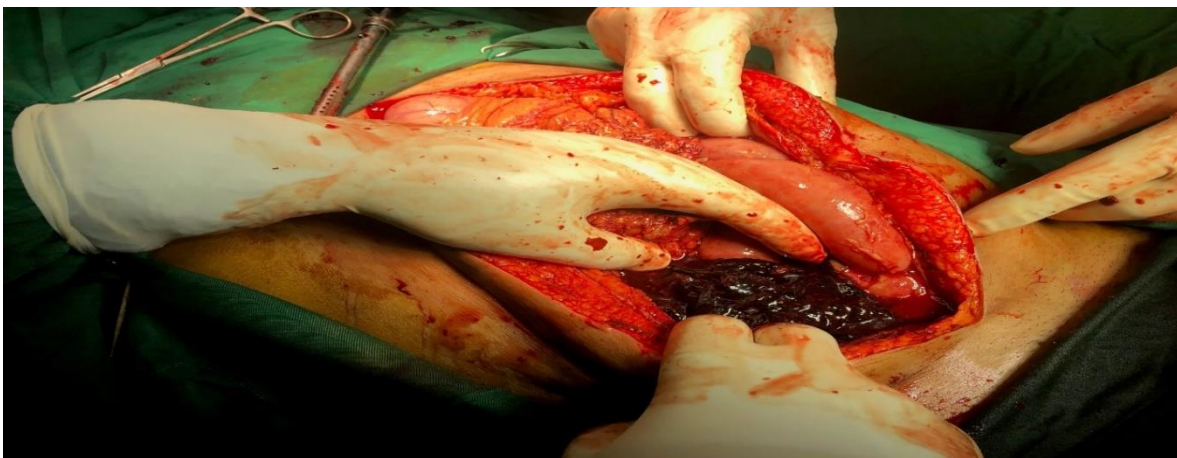


Figure 2: Melena

### Discussion:

Acute appendicitis is more common in teenagers and young adults, although not exclusive to this group. With advancing age, it is important to include other pathologies in the list of differentials, albeit, the clinical signs should

direct the clinician to the correct diagnosis. Acute appendicitis is a very common surgical emergency diagnosed by combining the history, examination, and investigations to build a clinical picture. This presentation can become more complex with abnormal anatomical variations of the appendix [2]. Appendicitis is a common disease, and as we have improved

in early diagnosis and management of this disease process, late stage complications have become extremely rare, but can have indolent presentations [3]. Acute appendicitis (AA) is the most common surgical emergency in children. Accurate and timely diagnosis is crucial but challenging due to atypical presentations and the inherent difficulty of obtaining a reliable history and physical examination in younger children [5].

### Conclusion:

This case report presents a rare complication of a common disease process that can present in a multitude of ways. Introduction In the United States (US), appendicitis is the most common acute abdominal emergency requiring surgery. Patients with appendicitis continue to display a complex and atypical range of clinical manifestations, providing a subsequent high risk for emergency physicians to miss acute abdominal pathology on a patient's initial visits. Due to the risk of potential perforation, the proper and timely clinical identification of acute appendicitis is vital [6]. Retrocecal appendicitis usually presents with atypical signs and symptoms which may lead to delayed diagnosis, perforation and serious complications [7]. A triage chief complaint less suggestive of appendicitis was associated with a higher rate of missed appendicitis in a pediatric ED [8]. Acute appendicitis is a

common cause of acute abdominal pain requiring urgent surgery. Despite characteristic clinical signs, diagnosis can be challenging, leading to unnecessary appendectomies [9]. A timely diagnosis requires a high index of suspicion, a careful history, and a physical examination. Imaging with ultrasound or computed tomography is recommended if there is a discrepancy between the medical history and physical examination [10]. However, the source of appendix bleeding is very rare [11]. It is important to distinguish appendiceal bleeding from lower gastrointestinal bleeding and to treat it as soon as possible with less invasiveness [11]. Appendiceal bleeding is often difficult to stop endoscopically, so appendectomy should be performed as soon as possible [12]. Although appendiceal bleeding is a rare cause of acute lower gastrointestinal bleeding, clinicians should consider it during differential diagnosis [13]. The preoperative detection of appendiceal bleeding is often challenging, colonoscopy is extremely important, bowel preparation is not routinely recommended for patients with acute LGIB or only low-dose bowel preparation is recommended. Laparoscopic appendectomy is the most appropriate treatment for appendiceal bleeding [14].

### Case of appendiceal bleeding (11):

Case	Age	Sex	Clinical findings	Treatment	Case	Age	Sex	Clinical findings	Treatment
1	46	Male	Appendicitis	Appendectomy	16	48	Male	Diverticular hemorrhage	Appendectomy
2	33	Male	Diverticulitis	Appendectomy	17	14	Male	Appendix abscess	Ileocaecal resection
3	72	Male	Angiodysplasia	Appendectomy	18	24	Male	Granulomatous appendicitis	Appendectomy
4	22	Male	Granulomatous appendicitis	Appendectomy	19	49	Male	Acute suppurative appendicitis	Appendectomy
5	68	Male	Appendiceal dieulafoy lesion	Appendectomy	20	63	Male	Diverticulitis	Hemicolectomy
6	44	Male	Diverticulitis	Hemicolectomy	21	18	Female	Intussusception	Appendectomy
7	51	Male	Dieulafoy lesion	Appendectomy	22	33	Female	Cause unknown	Ileocaecal resection
8	71	Male	Appendix ulcer	Barium enema	23	36	Male	Intussusception	Appendectomy
9	41	Male	Atypical florid vascular proliferations	Appendectomy	24	38	Male	Aortoenteric fistula	Appendectomy
10	59	Female	Aortoenteric fistula	Hemicolectomy	25	49	Female	Appendix cancer	Ileocaecal resection
11	25	Male	Focal erosion of appendix mucosa	Appendectomy	26	53	Female	Appendicitis	Appendectomy
12	42	Male	Appendiceal mucosal erosion	Appendectomy	27	44	Male	Cause unknown	Appendectomy
13	56	Male	Gastrointestinal stromal tumor	Appendectomy	28	33	Male	Cause unknown	Appendectomy
14	76	Female	Angiodysplasia	Appendectomy	29	70	Male	Cause unknown	Colonoscopy
15	32	Female	Ulcerated appendiceal stump	Appendectomy	our case	90	Male	Cause unknown	Appendectomy

### Declarations:

Ethical Approval and Consent to participate:

The content of this manuscript are in accordance with the declaration of Helsinki for Ethics. No committee approval was required. Oral and written consent to participate was granted by her wife.

### Consent for publication:

“Written informed consent was obtained from the patient's legal guardian for publication of this case report and any accompanying images. A copy of the written consent is available for review by the Editor-in-Chief of this journal.”



- Availability of supporting data

It is available.

### Authors' contributions:

Ahmad Reza Shahraki is the surgeon of patient and writes this paper. Elham Shahraki edits paper and Elahe Shahraki collects data's.

The authors declare that they have no competing financial interests and nothing to disclose.

### Acknowledgements

Introduction In the United States (US), appendicitis is the most common acute abdominal emergency requiring surgery. Patients with appendicitis continue to display a complex and atypical range of clinical manifestations, providing a subsequent high risk for emergency physicians to miss acute abdominal pathology on a patient's initial visits. Due to the risk of potential perforation, the proper and timely clinical identification of acute appendicitis is vital

### References:

1. Chand M, Moore PJ, Nash GF (2007). A simple case of appendicitis? An increasingly recognised pitfall. *Ann R Coll Surg Engl.* Oct;89(7): W1-3.
2. Longani SK, Ahmed A (2019). Classical Presentation of Acute Appendicitis in the Case of a Subhepatic Appendix. *Cureus.*11(10): e6035.
3. Kurtzman N, Adler J, Ketterer A, Lewis J (2021). Rare Complications of Acute Appendicitis: A Case Report. *Clin Pract Cases Emerg Med.* 2021 Feb;5(1):66-69.
4. Taylor GM, Saffer ER, McDowell EL, Warpinski MA (2019). A 2-year-old with a hepatic abscess secondary to an ascending retrocecal appendicitis: case report and review of the literature. *Int J Emerg Med.* 2019 Dec 19;12(1):41.
5. Benabbas R, Hanna M, Shah J, Sinert R (2017). Diagnostic Accuracy of History, Physical Examination, Laboratory Tests,

- and Point-of-care Ultrasound for Pediatric Acute Appendicitis in the Emergency Department: A Systematic Review and Meta-analysis. *Acad Emerg Med.* 2017 May;24(5):523-551.
6. Brown-Forestiere R, Furiato A, Forestiere NP, Kashani JS, Waheed A (2020). Acute Appendicitis: Clinical Clues and Conundrums Related to the Greatest Misses. *Cureus.* 11;12(5): e8051.
7. Faizi FR, Farzam F (2022). Perforated retrocecal appendicitis presenting with lung abscess-A case report. *Radiol Case Rep.* 2022 Jun 2;17(8):2754-2758.
8. Drapkin Z, Dunnick J, Madsen TE, Bryce M, Schunk JE (2020). Pediatric Appendicitis: Association of Chief Complaint With Missed Appendicitis. *Pediatr Emerg Care.* 2020 Apr;36(4):e204-e207.
9. Francis MA, Nerella R, Francis DT, Raj R, Zain A, Augustine S, Jamil NA (2023). Acute Appendicitis with Appendicolith and its Complication and Management: A Case Report. *Cureus.* 2023 Sep 21;15(9):e45715.
10. Karen Juliana Salinas-Castro MD a, Valentina Mejía-Quñones MD a b, Natalia Yeritza Zúñiga-Londoño MD c (2023). Acute appendicitis after closed abdominal trauma: A case report. *Radiology Case Reports,* Pages 631-634.
11. Maeda Y, Saito S, Ohuchi M, Tamaoki Y, Nasu J, Baba H (2021). Appendiceal bleeding in an elderly male: a case report and a review of the literature. *Surg Case Rep.* 2021 Jun 23;7(1):147.
12. Nakashima T, Sano B, Ikawa A, Tawada K, Shinoda T, Ohno S, et.al (2023). A case of laparoscopic appendectomy for appendiceal bleeding. *Surg Case Rep.* 2023 Oct 16;9(1):179.
13. Zhou SY, Guo MD, Ye XH (2022). Appendiceal bleeding: A case report. *World J Clin Cases.* 26;10(18):6314-6318.
14. Ma Q, Du JJ (2024). Appendiceal bleeding caused by vascular malformation: A case report. *World J Clin Cases.*16;12(14):2457-2462.



This work is licensed under Creative Commons Attribution 4.0 License

To Submit Your Article Click Here:

[Submit Manuscript](#)

DOI:10.31579/2690-8794/221

#### Ready to submit your research? Choose Auctores and benefit from:

- fast, convenient online submission
- rigorous peer review by experienced research in your field
- rapid publication on acceptance
- authors retain copyrights
- unique DOI for all articles
- immediate, unrestricted online access

At Auctores, research is always in progress.

Learn more <https://auctoresonline.org/journals/clinical-medical-reviews-and-reports>