

# Giant Mediastinal Teratoma. Case Report and bibliographic revision

López-Yepes Luis Alejandro <sup>1\*</sup>, Reyes Zúñiga, Karla <sup>2</sup>, Servio Tulio Torres Rodríguez <sup>3</sup>, Urrutia Brán Ana Lucia <sup>4</sup>

<sup>1, 2, 3</sup> Pulmonologist, Resident Physician and Thoracic Surgeon at the National Reference Hospital for Respiratory Diseases,

<sup>4</sup> Nutritionist and Epidemiologist, Private Clinic, Guatemala City, Guatemala. Guatemala City, Guatemala.

**\*Corresponding Author:** López-Yepes Luis Alejandro, Pulmonologist, Resident Physician and Thoracic Surgeon at the National Reference Hospital for Respiratory Diseases, Guatemala City, Guatemala.

**Received date:** August 04, 2024; **Accepted date:** September 12, 2024; **Published date:** November 18, 2024

**Citation:** Luis Alejandro LY, Reyes Z. Karla, Torres Rodríguez ST, Ana Lucia UB, (2024), Giant Mediastinal Teratoma. Case Report and bibliographic revisión, *Clinical Research and Clinical Trials*, 11(2) ; DOI :[10.31579/2693-4779/224](https://doi.org/10.31579/2693-4779/224)

**Copyright:** © 2024, López-Yepes Luis Alejandro. This is an open access article distributed under the Creative Commons Attribution License, which permits unrestricted use, distribution, and reproduction in any medium, provided the original work is properly cited.

## Abstract:

Mature mediastinal teratoma is the most common thoracic germ cell tumor. No specific cause has been detected, although it has been linked to some risk factors, such as maternal exposures to harmful inhalational environmental agents, maternal nutritional deficiencies, cryptorchidism, hypospadias, hemolytic anemia, among others. It is usually a rare entity, without having its prevalence clearly described, it can reach 3% of thoracic pathology, being the 10% of the histological lineage detected in the mediastinal masses. Although some authors have not described differences in the prevalence between males and females, others have detected a clear majority in males, reaching a ratio of 13 to 1. Mature teratoma usually lacks malignant cells and usually has an excellent prognosis after complete surgical excision of the tumor. However, some teratomas may have atypical cells among the diversity of tissues that compose it, which makes it imperative a directed and exhaustive search by the pathologist, to detect this tissue in the tumor mass, since this would imply a worse prognosis and the need to use adjuvant chemotherapy and a follow-up of tumor extension, thus improving the survival of these patients.

Next, a case of mature teratoma of the chest is described and a literature review is performed.

**Keywords:** giant cell tumor; teratoma; mediastinum

## Introduction

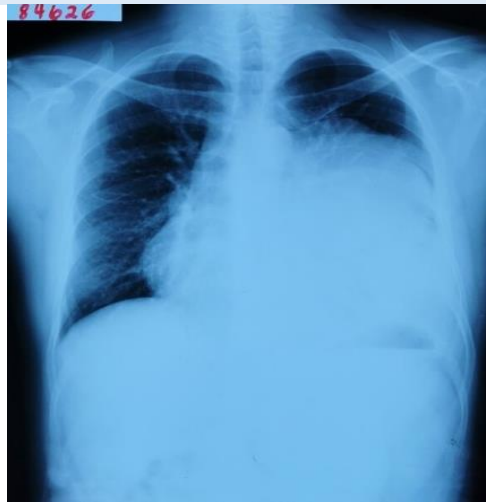We present the case of a mature teratoma in the left hemithorax, in a 29-year-old man, with classic clinical presentation of chest pain with pleuritic characteristics in the left hemithorax, dyspnea on moderate exertion, right trepopnea (dyspnea with the right lateral decubitus) and occasional dry cough. It has been treated with complete excision of the tumor, without having detected any component of malignancy in the mass, having achieved a complete recovery 6 months after the surgical intervention.

### Case Report: Clinical History, Diagnosis. Therapy.

A 29-year-old male patient presented with sudden onset of pain in the left shoulder, radiating to the back, predominantly on the left side, intense, worsening with the right lateral decubitus, cough and deep inspiration, with relief only when taking nonsteroidal anti-inflammatory drugs and spasmolytics. He also reports a feeling of dyspnea that has been increasing until he is resting, which worsens with moderate efforts and with the supine

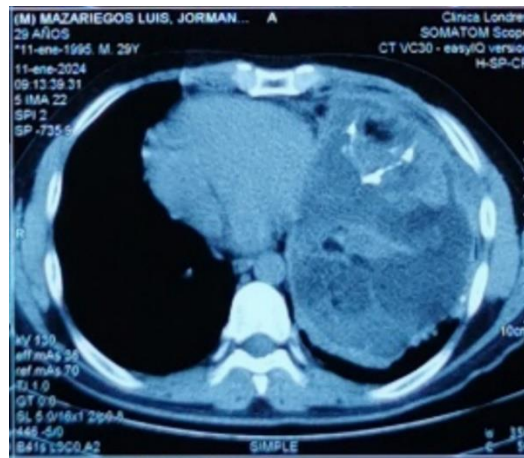
and right lateral position. The symptoms are partially relieved by adopting the left lateral decubitus.

Physical examination revealed a blood pressure of 106/82 mmHg, a temperature of 37°C, SpO<sub>2</sub>: 94%, a heart rate of 94bpm and a glucometer of 83mg/dl in fasting. Pulmonary auscultation revealed a right lung with a good entrance, a left lung with decreased air entry throughout the pulmonary field without other relevant findings. Laboratory studies of hematology, blood chemistry, coagulation times, hormonal profiles, and tumor markers were normal. Spirometry revealed: LVEF 1.47 l (33%); FVC 1.59 (30%); FEV1/FVC 92% (110%), FEF 25-75% 2.38 l/s (45%), severe restrictive pattern. Chest x-ray showed a rounded, solid-looking opacity without an air bronchogram occupying 2/3 of the left hemithorax, with a slight deviation of the mediastinum to the right. (Figure 1).



**Figure 1:** Chest X-ray PA.

Computed tomography (CT) of the chest revealed a heterogeneous, solid mass with different densities inside, including densities of fat, calcium, soft tissues and cartilage, sugestivo de ser un teratoma. (Figura 2).

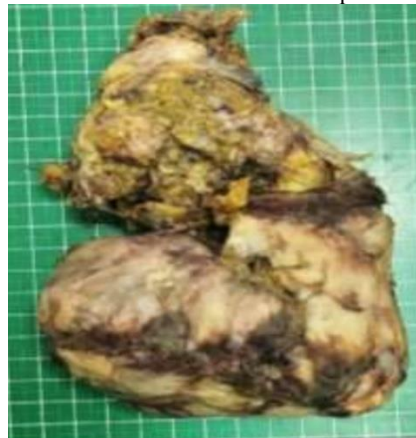

**Figure 2:** Computed tomography scan of the chest.

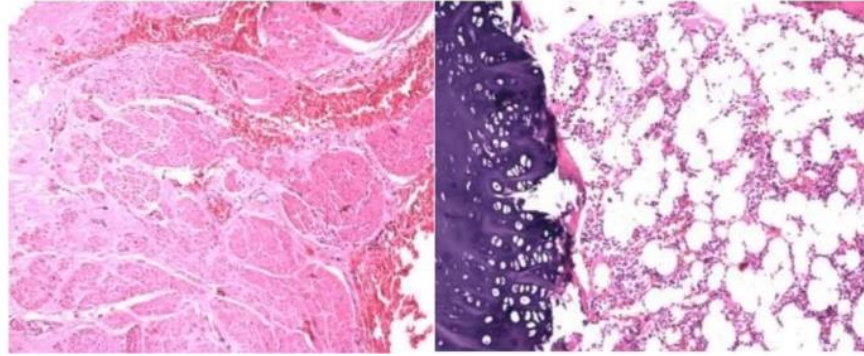
A fiberoptic bronchoscopy was performed with the only finding of extrinsic compression in the main bronchus and segmental bronchus on the left side, without exophytic endobronchial lesions. With the clinical impression of a thoracic teratoma, it was decided to perform a surgical resection through a left posterolateral thoracotomy, in which the extraction of the entire mass was achieved, with dimensions of 17 x 10 x 6 centimeters, with macroscopic

evidence of epithelial, cartilaginous, adipose tissues, presence of hair follicles and sebaceous material.

Histologically, the presence of multiple mature-looking tissues is detected, including mesenchymal tissue such as striated muscle and cartilage, as well as bone marrow, squamous epithelial tissue, with cutaneous adnexa, adipose and mucoproducing tissue. (Figures 3 and 4).



**Figure 3:** Macroscopic image of resected mature teratoma, dimensions 17 x 10 x 6 cm.



**Figure 4:** Histological image (40X) showing striated muscle tissue, cartilage and bone marrow.

A mature teratoma-type germ cell tumor without malignant components is diagnosed. After the resection of the mass, the patient has evolved satisfactorily, achieving the complete expansion of his left lung and is currently in rehabilitation therapy in respiratory physiotherapy.

### Discussion

Germ cell tumors account for about 10-15% of mediastinal tumors. They consist of neoplasms formed by germ cells that have migrated aberrantly during early embryonic development. There are several theories: some propose that there is an error in the migration of primitive germ cells along the urogenital crest<sup>1</sup>; Others propose that these tumors originate from totipotent cells that remained in the blastula or morula state during embryogenesis. The mediastinum is the most common extragonadal location of approximately 1-3% of all giant cell tumors. They can be subdivided into three main groups: teratoma, seminomatous tumors, and nonseminomatous tumors. The predominant histologic type is mature teratoma, followed by seminoma, nonseminoma giant cell tumors, and finally mixed giant cell tumors. Teratoma is the most common mediastinal germ cell tumor, approximately 75% of which are mature teratomas<sup>2</sup>. We have not found in the review risk factors described for mediastinal teratomas, however, there are described risk factors for testicular teratomas, including low birth weight, cryptorchidism, advanced maternal age, neonatal jaundice, retained placenta<sup>3</sup>, and ovarian teratoma, advanced age and postmenopause<sup>4</sup>. Its appearance is more frequent in young adults, but it has been reported in all ages; Men and women are affected with equal frequency. However, a descriptive study conducted between 1986 and 2012 in Costa Rica found a more frequent gender ratio in men than in women, a ratio of 13.5:1 and an average age of 26 years<sup>5</sup>.

Most patients will be symptomatic at diagnosis, with only a third of cases being asymptomatic. The most frequent symptoms are chest pain of retrosternal location, dyspnea and cough; other symptoms may include dysphonia, diaphragmatic paralysis, hemoptysis, and inferior vena cava syndrome<sup>5</sup>. If the tumor fistulizes into the bronchial system, the patient may expectorate different types of tissues that make up the tumor. By definition, the teratoma is made up of tissues different from those in the area where it has grown. It may have mature tissues from any of the three primary germ lines: the mesoderm (bone, cartilage, and muscle), the endoderm (respiratory, gastrointestinal, and mucous gland tissues), and the ectoderm (nerve fibers, epidermal appendages)<sup>6</sup>. Ectoderm derivatives are the most frequent and if there are only epidermal derivatives, it is called a dermoid cyst.

Teratomas are classified as mature, which are usually well differentiated and benign; immature, those with fetal tissue and are malignant, and teratomas with a malignant component. Giant teratomas are those that occupy half or more of the hemithorax. The most common symptoms are chest or shoulder pain, dyspnea, cough, fever, pleural effusion, and bulging of the chest wall.<sup>7</sup>

On x-rays, the teratoma usually looks solid, rounded, lobed, and asymmetrical. It can have cystic images, calcium and heterogeneity of densities that are usually differentiated with greater precision, with chest

axial tomography, being able on many occasions to guide a fairly accurate diagnosis before surgical resection.

The treatment consists of surgical resection, obtaining excellent results after it. All teratomas should be resected because of their compressive effect on neighboring vital structures, in addition to their potential for progressive growth and malignancy.

Teratomas should be carefully studied by the pathologist throughout the entire extension of the mass to rule out the presence of a malignant neoplasm component, since this would worsen its prognosis, due to its potential to infiltrate adjacent organs or even metastasize; If malignant cells are detected, treatment should be accompanied by adjuvant chemotherapy in addition to surgical resection, which will improve patient survival. In addition, extension studies such as PET CT should be performed to rule out metastatic lesions at other levels.<sup>8</sup>

Mature teratoma of the chest is a rare entity. The risk factors that predispose to its development are poorly described. A thorough histological study of the full extent of the mass should be performed to rule out the presence of malignancy in the heterogeneity of tissues that make up the teratoma. All teratomas should be surgically removed and if malignancy is detected, adjuvant chemotherapy and tumor extension study should be considered.

### Conflict of Interest

None of the authors has a conflict of interest.

### References

1. Yalagachin GH. (2013). Anterior mediastinal teratoma- a case report with review of literature. *Indian J Surg*; 75 (1):182-184.
2. Bandrés Carballo B, Parra Gordo ML, González Sendra F, Teratoma maduro mediastínico; Hospital Universitario La Princesa; Madrid
3. Farci F, Shamsudeen S. (2024). Testicular Teratoma. [Updated 2023 Apr 23]. In: StatPearls [Internet]. Treasure Island (FL): StatPearls Publishing;
4. Boiselle PM, Rosado-de-Christenson ML. (2001). Fat attenuation lesions of the mediastinum. *J Comput Assist Tomogr*; 25:881-889.
5. Mainieri-Hidalgo, José A., Rees-Alpizar, Valeria, Gamboa-González, Isabel, Mainieri-Breedy Marcelo. (2013). Tumores de células germinales del mediastino. *Experiencia con 29 pacientes. Acta Médica Costarricense [en línea]*, 55(3), 128-131
6. Guibert N, Attias D, Pontier S, Berjaud J, Laviaille-Guillaudreau V, Didier A, et al. (2011). Mediastinal Teratoma and Trichoptysis. *Ann Thorac Surg.*; 92:351-353.
7. Serraj M, Lakranbi M, Ghalimi J, Ouadnoui Y, Smahi M. (2013). Mediastinal mature teratoma with complex rupture into the lung, bronchus and skin: a case report. *World J Surg Oncol*; 11:125-127.
8. Wick MR, Perlman PH, et al. (2004). Germ cell tumor with somatic-type malignancy. *World Health Organization*

Classification of Tumors: Pathology and Genetics of tumors of the lung, pleura, thymus and heart.; 216-218.



This work is licensed under Creative Commons Attribution 4.0 License

To Submit Your Article Click Here:

**[Submit Manuscript](#)**

**DOI:10.31579/2693-4779/224**

**Ready to submit your research? Choose Auctores and benefit from:**

- fast, convenient online submission
- rigorous peer review by experienced research in your field
- rapid publication on acceptance
- authors retain copyrights
- unique DOI for all articles
- immediate, unrestricted online access

At Auctores, research is always in progress.

Learn more <https://auctoresonline.org/journals/clinical-research-and-clinical-trials>