

## Primary Repair of liver Blunt Trauma: A Case Report

Ahmad Reza Shahraki\*

General surgeon, Assistant professor, Department of surgery, Zahedan medical faculty, Zahedan University of Medical Sciences and Health Services, Zahedan, Iran.

**\*Corresponding Author:** Ahmad Reza Shahraki., General surgeon, Assistant professor, Department of surgery, Zahedan medical faculty, Zahedan University of Medical Sciences and Health Services, Zahedan, Iran.

**Received Date:** 13 August, 2024 | **Accepted Date:** 10 September, 2024 | **Published Date:** 08 October, 2024

**Citation:** Ahmad R. Shahraki, (2024), Primary Repair of liver Blunt Trauma: A Case Report, *Journal of Clinical Surgery and Research*, 5(7); DOI:10.31579/2768-2757/139

**Copyright:** © 2024, Ahmad Reza Shahraki. This is an open access article distributed under the Creative Commons Attribution License, which permits unrestricted use, distribution, and reproduction in any medium, provided the original work is properly cited.

### Abstract:

Liver injury is the most vulnerable to blunt abdominal trauma. The liver is one of the most affected organs in abdominal trauma mostly because of its considerable dimensions, the fragility of the liver parenchyma. In liver trauma, hemodynamic instability guarantees an emergency Laparotomy. our case was a 29 years old man with car accident, blunt abdominal trauma and blunt liver trauma that primary repair did for him. In liver trauma, hemodynamic instability requests an emergency Laparotomy. Most cases of blunt hepatic trauma are treated nowadays non-operatively. This type of conservative treatment has resulted in increased complication rate. In liver trauma, hemodynamic instability requests an emergency laparotomy. Emergency physicians must be aware that radiological intervention is an important adjunct to management of liver injury. Most cases of blunt hepatic trauma are treated nowadays non-operatively. This type of conservative treatment has resulted in increased complication rate Massive life threatening intraperitoneal bleeding may occur weeks after liver trauma. Although non operative management is opted nowadays over operative treatment, in high grades liver trauma, the patients should be closely monitored by US examinations to allow early detection of changes indicating the development of possible late complications

**keywords:** trauma; liver laceration; hepatic injury; laparotomy

### Introduction

The liver is one of the most affected organs in abdominal trauma mainly due to its large size, the fragility of the parenchyma and Glisson's capsule, significant vascularity, and location in relation to the anterior abdominal wall, below the coastal rim [1]. The most important steps in the therapeutic approach to liver trauma are rapid diagnosis and determination of the degree of injury [2] The therapeutic strategy has undergone significant changes in recent decades, nowadays non operative being frequently used in liver trauma for thermodynamically stable patients [3]. Although non operative management has advanced significantly, the treatment should be tailored primarily to the physiological conditions of the continuously monitored patient (4). The decisive factor for the surgical intervention is hemodynamic stability.

The higher the degree of the injury, the greater the risk of the patient to become thermodynamically unstable, which will require emergency surgery. Surgical intervention and damage control is focused on obtaining hemodynamic stability rather than the immediate and complete treatment of injuries [5]. Liver packing is one of the techniques used in cases of abdominal trauma with massive bleeding in order to obtain compression on the parenchyma and reduce the time of surgery [6].

American Association for the Surgery of Trauma liver injury scale: [7]

I Hematoma Subcapsular < 10% surface

Laceration Capsular tear < 1 cm parenchyma depth

II Hematoma Subcapsular 10-50% surface area; intraparenchymal < 10 cm diameter

Laceration 1-3 cm parenchymal depth; < 10 cm in length

III Hematoma Subcapsular > 50% surface area or expanding; ruptured subcapsular or parenchymal

hematoma; intraparenchymal hematoma > 10 cm

Laceration > 3 cm parenchymal depth

IV Laceration Parenchymal rupture 25-75% of hepatic lobe or 1-3 Couinaud segments

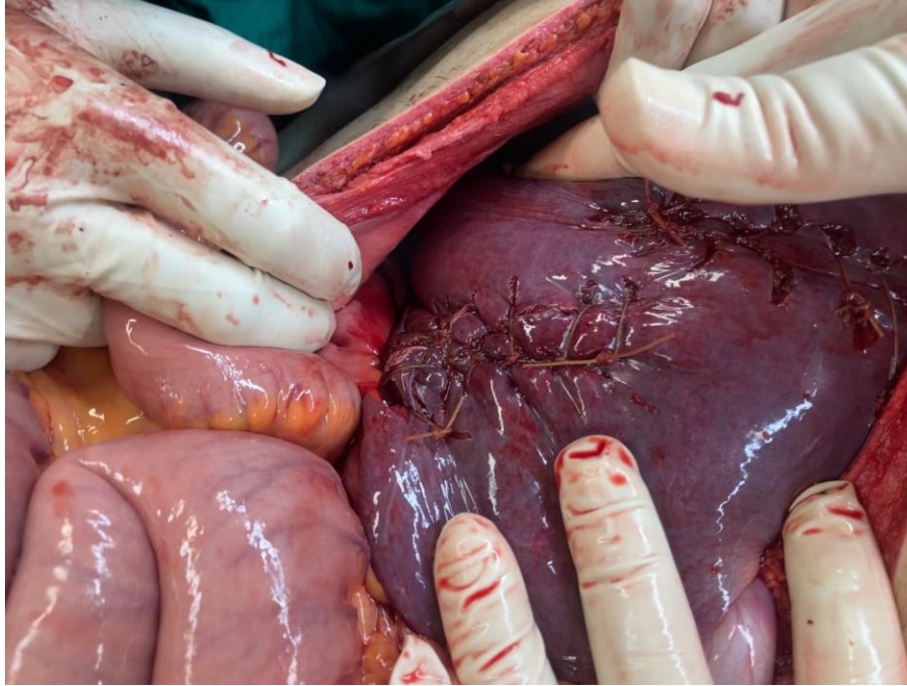
V Laceration Parenchymal rupture > 75% or > 3 Couinaud segments

Vascular Juxtahepatic veins injuries (suprahepatic veins or retrohepatic vena cava)

## VI Vascular Hepatic avulsion

This case report shows as a surgeon you must decide as soon as possible to repair liver or just do damage control surgery and packing.

### Case presentation:



**Figure1:** Primary repair of liver.

After 4 days Ultrasonography show no liquid in abdomen and after 8 days we discharge patient successfully.

### Conclusion:

In liver trauma, hemodynamic instability requests an emergency laparotomy [8]. Emergency physicians must be aware that radiological intervention is an important adjunct to management of liver injury [9]. Most cases of blunt hepatic trauma are treated nowadays non-operatively. This type of conservative treatment has

resulted in increased complication rate [10] Massive life-threatening intraperitoneal bleeding may occur weeks after liver trauma. Although non operative management is opted nowadays over operative treatment, in high grades liver trauma, the patients should be closely monitored by US examinations to allow early detection of changes indicating the development of possible late complications. When such signs are detected, angiography may allow early non operative treatment and possibly prevent late bleeding. Patients should not be discharged before the pathological US imaging signs of damage are stabilized [10].

### Declarations:

#### Ethical Approval and Consent to participate:

The content of this manuscript are in accordance with the declaration of Helsinki for Ethics. No committee approval was required. Oral and written consent to participate was granted by the families.

### Consent for publication:

“Written informed consent was obtained from the patient's legal guardian for publication of this case report and any accompanying images. A copy Auctores Publishing LLC – Volume 5(6)-139 www.auctoresonline.org ISSN: 2768-2757

Our case was a 29 years old man with car accident, her GCS was 15 and his main complaint was abdominal pain. His blood pressure was 135/80 and hear rate was 90. A FAST did for him and found moderate liquids in his abdomen, with all situation he bring to operating room and laparotomy was done. A multiple hepatic damage was seen and primary repair did .

of the written consent is available for review by the Editor-in-Chief of this journal.”

### - Availability of supporting data

It is available

### - Competing interests:

The author declares that they have no competing financial interests and nothing to disclose.

### - Funding: There is no funding.

### - Authors' contributions:

Ahmad Reza Shahraki was the surgeon of patient and writes this paper.

The author declares that they have no competing financial interests and nothing to disclose.

### - Acknowledgements

In liver trauma, hemodynamic instability requests an emergency laparotomy. Most cases of blunt hepatic trauma are treated nowadays non-operatively. This type of conservative treatment has resulted in increased complication rate.

### References:

1. Ahmed N, Vernick JJ. (2011). Management of liver trauma in adults Journal of Emergencies, Trauma and Shock, vol 4, Wolters Kluwer - Medknow Publications, 114–119.

2. Letoublon C, Amariutei A, Taton N, Lacaze L, Abba J, et al. (2016). Management of blunt hepatic trauma. *J. Visc. Surg*; 153:33–43.
3. Ibrahim AH, Osman AJ, Alarfaj MA, Alzamil AM, Abahussain MA, et al. (2020). Case report: Evisceration of abdomen after blunt trauma. *Int. J. Surg. Case Rep*; 72: 207–11.
4. Doklesti\_K, Stefanovi\_B, Gregori\_P, Ivan\_evi\_N, Lon\_ar\_Z, et al. (2015). Surgical management of AAST grades III-V hepatic trauma by Damage control surgery with perihepatic packing and Definitive hepatic repair-single centre experience. *World J. Emerg. Surg*; 10:1–8.
5. Petrowsky H, Raeder S, Zuercher L, Platz A, Simmen HP, et al. (2012). A quarter century experience in liver trauma: A plea for early computed tomography and conservative management for all hemodynamically stable patients. *World J. Surg*; 36:247–254.
6. Caruso DM, Battistella FD, Owings JT, Lee SL, Samaco RC. (1999). Perihepatic packing of major liver injuries: Complications and mortality. *Arch. Surg*; 134:958–963.
7. Moore EE, Cogbill TH, Jurkovich GJ, Shackford SR, Malangoni MA, et al. (1995). Organ injury scaling: Spleen and liver (1994 revision). *J. Trauma - Inj. Infect. Crit. Care*; 38:323–324.
8. Vlad Braga, Iulian Slavu, Adrian Tulin, Bogdan Socea, Lucian Alecu. (2020). A case report of blunt liver trauma in times of COVID-19 pandemic. *Romanian Journal of Orthopaedic Surgery and Traumatology*.
9. Atsuyoshi Iidaa, Tsuyoshi Ryukob, Masaichi Kemmotsu, Hiroaki Ishiic, Hiromichi Naitod, et al. (2020). Three-year-old traumatic liver injury patient treated successfully using transcatheter arterial embolization A. *International Journal of Surgery Case Reports*; 70 (2020) 205–208.
10. Uri Kaplan., Oshama A Hatoum., Alexander Chulsky., Hussam Menzal., and Doron Kopelman. (2011). Two weeks delayed bleeding in blunt liver injury: case report and review of the literature. Kaplan et al. *World Journal of Emergency Surgery*, 6:14,



This work is licensed under Creative Commons Attribution 4.0 License

To Submit Your Article, Click Here:

**Submit Manuscript**

DOI: [10.31579/2768-2757/139](https://doi.org/10.31579/2768-2757/139)

#### Ready to submit your research? Choose Auctores and benefit from:

- fast, convenient online submission
- rigorous peer review by experienced research in your field
- rapid publication on acceptance
- authors retain copyrights
- unique DOI for all articles
- immediate, unrestricted online access

At Auctores, research is always in progress.

Learn more <https://www.auctoresonline.org/journals/journal-of-clinical-surgery-and-research>