

# Tamponade revealing purulent pericarditis caused by *Klebsiella pneumoniae* and *Escherichia coli*. Clinical cure by drainage and Antibiotic therapy. Sikasso (Mali)

Traore-Kissima Abdoulaye <sup>1</sup>, Cénac Arnaud <sup>2\*</sup>, Dembele Ahmadou <sup>3</sup>, Cissouma Assetou <sup>4</sup>, Haidara Ousmane <sup>1</sup>, Kone Nouhoum <sup>1</sup>, Dembele Marie-Ange <sup>5</sup>, Kassogue Oumar <sup>6</sup>

<sup>1</sup>Department of Cardiology, Sikasso Hospital, Mali.

<sup>2</sup>UFR of Medicine, University of Western Brittany, France.

<sup>3</sup>Department of Otorhinolaryngologie, Sikasso Hospital, Mali.

<sup>4</sup>Department of Pediatrics, Sikasso Hospital, Mali.

<sup>5</sup>Department of Radiology, Sikasso Hospital, Mali.

<sup>6</sup>Biology laboratory (BioSik), Sikasso, Mali.

\*Corresponding Author: Cénac Arnaud, UFR of Medicine, University of Western Brittany, Brest, France.

Received date: August 16, 2024; Accepted date: September 23, 2024; Published date: September 30, 2024

**Citation:** Traore K. Abdoulaye, Cénac Arnaud, Dembele Ahmadou, Cissouma Assetou, Haidara Ousmane, et al. (2024), Tamponade revealing purulent pericarditis caused by *Klebsiella pneumoniae* and *Escherichia coli*. Clinical cure by drainage and antibiotic therapy. Sikasso (Mali), *Journal of Clinical Cardiology and Cardiovascular Interventions*, 7(10); DOI:10.31579/2641-0419/404

**Copyright:** © 2024, Cénac Arnaud. This is an open access article distributed under the Creative Commons Attribution License, which permits unrestricted use, distribution, and reproduction in any medium, provided the original work is properly cited.

## Abstract

The authors report the observation of a 52-year-old Malian patient living in Sikasso (Mali), hospitalized urgently for febrile condition with arterial hypotension. The diagnosis of tamponade is made by echocardiography. Drainage of the pericardial effusion quickly improves the hemodynamic status and reveals purulent fluid. Microbiological analysis of the liquid identifies 2 different, associated pathogenic bacteria: *Escherichia coli* and *Klebsiella pneumoniae*. Treatment with Imipenem (2 g/day by venous infusion) for 21 days leads to healing. Thirty-six months later the patient is in a stable state of clinical recovery. The authors did not find in the literature any purulent pericarditis with the 2 bacteria identified here, associated.

**Keywords:** tamponade; purulent pericarditis; *klebsiella pneumoniae*; *escherichia coli*

## Introduction

Purulent pericarditis, apart from tuberculosis, is rare [1]. The observation reported is a purulent pericarditis where 2 associated pathogenic bacteria were isolated, an association not previously described.

**Clinical history.** A 52-year-old black Malian man living in Sikasso was hospitalized in January 2021 for febrile chest pain with dry cough and edema of the lower limbs. The clinical examination data are:

Height = 1.86 m Weight = 65 kg

Respiratory rate = 22 cycles/min

Chest distension

Bilateral crackling rattles

Unperceived peak shock

Low blood pressure: right arm = 90/50 mmHg

left arm = 80/50 mmHg

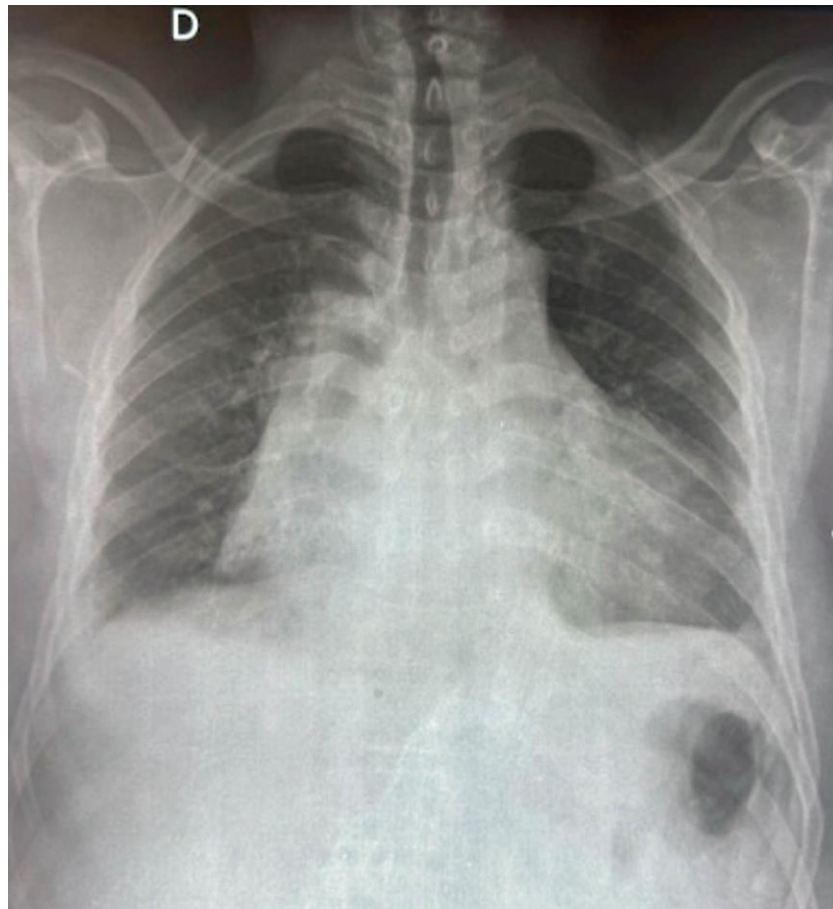
Hepatomegaly with jugular turgor

Hepatojugular reflux

Peripheral pulses weakly felt

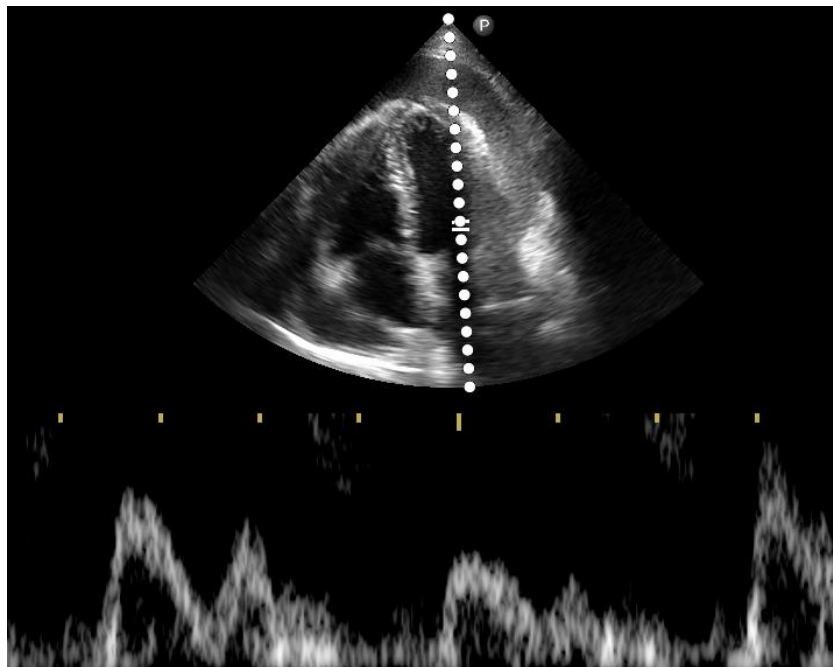
ECG: sinus rhythm at 98/min, diffuse repolarization disorders such as “Holzmann stage 1 pericarditis”.

Frontal chest x-ray: very enlarged cardiac shadow (cardiothoracic ratio = 0.8), basal opacity of the left lung field, barely visible recess of pleura (pleural effusion?) (**Figure 1**).



**Figure 1 :** Frontal chest radiograph. Cardiothoracic ratio = 0.8.

Echocardiography: demonstration of a large pericardial effusion with a “swinging heart” appearance. Left and right systolic functions are preserved but the diastole of the right ventricle is of low amplitude, a sign of tamponade (figure 2).



**Figure 2 :** Ultrasound before puncture (apical section of the 4 cavities): large pericardial effusion and significant variations in flow, signs of poor tolerance (tamponade).

Biological results: anemia with hemoglobin at 10 g/dL and hematocrit at 35.5%, red blood cells = 4.42 million/mm<sup>3</sup>, leukocytosis at 26,400/mm<sup>3</sup> with 82% neutrophils, platelets = 245,000/mm<sup>3</sup>

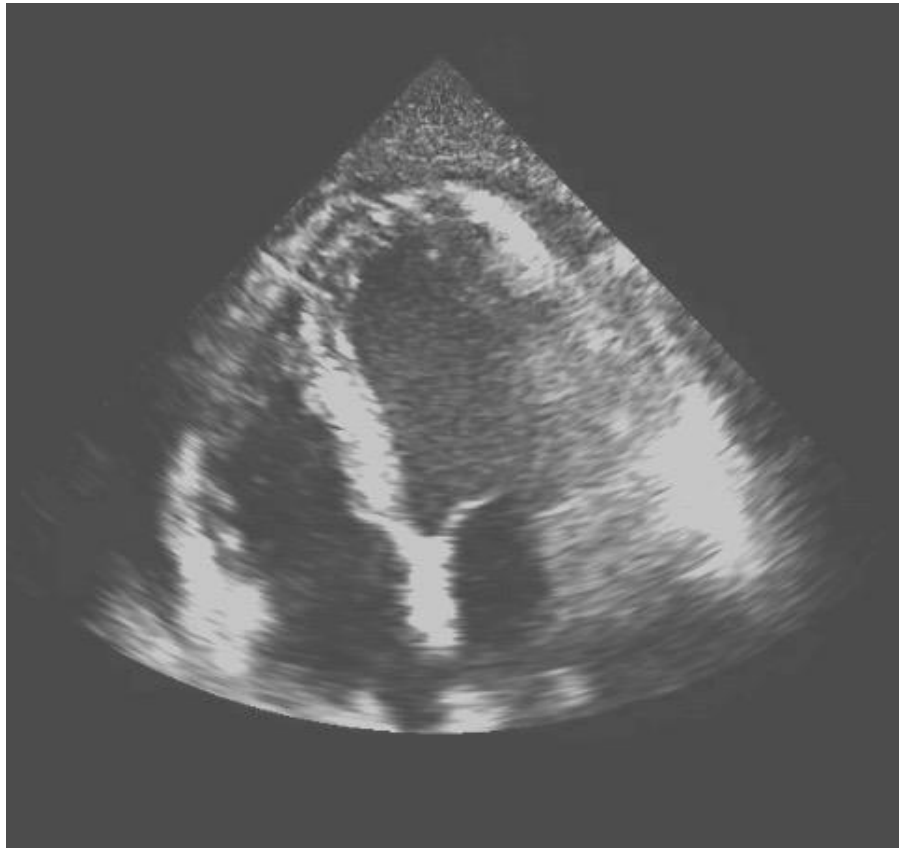
C reactive protein = 50 mg/L

Fasting blood sugar = 1 g/L Creatinine = 18 mg/L

The pericardial puncture brings back a brown, cloudy fluid with a purulent appearance. On direct examination under the microscope, the number of leukocytes per field is greater than 500, with 90% neutrophils and 10% lymphocytes. The culture makes it possible to isolate 2 pathogenic bacteria, *Escherichia coli* and *Klebsiella pneumoniae* and to establish an

antibiogram. Both bacteria are sensitive to several antibiotics: Imipeneme, Kanamycin, Amikacin, etc.

Treatment and evolution. The diagnosis of purulent pericarditis complicated by tamponade was made. High-flow oxygen therapy is installed and an ultrasound-guided pericardial puncture is performed. An hour later, a new ultrasound examination reveals the virtual disappearance of the effusion (figure 3) and signs of tamponade. Antibiotic treatment with Imipeneme is undertaken at a dose of 2 g/day, intravenously, for 21 days, under monitoring of renal function. At the end of this treatment, the clinical, biological and ultrasound assessments confirm healing. After several months (up to 36 months), the patient's condition is stable, without relapse.



**Figure 3:** Ultrasound after puncture (apical section of the 4 cavities): small pericardial effusion coinciding with a spectacular clinical improvement.

## Discussion

Purulent pericarditis is a serious, life-threatening infection [1]. Having become rare in Europe (< 1% of causes of pericarditis), they are more frequent in Africa (2 to 3% of causes of pericarditis) [2]. When the diagnosis is considered during a tamponade, it is a vital emergency [3]. The contribution of echocardiography to making the diagnosis of pericardial effusion with tamponade is then decisive [3]. As for the pathogens responsible, several have been reported but are rare apart from the tuberculosis bacillus [2]. Thus *Klebsiella pneumoniae* is found responsible for purulent pericarditis in a patient undergoing hemodialysis [4], in a Nigerian child [5], in a 44-year-old Chinese woman infected with a lethal hyper-virulent form [6], in a Colombian [7]. The responsibility of *Escherichia coli* seems exceptional; we found only one observation in the medical literature [8]. As for the question of a *Klebsiella pneumoniae*-*Escherichia coli* double infection, no case is reported in the literature accessible on the databases.

## Conclusion

This clinical case demonstrates for the first time the possibility of a bacterial association in a purulent pericarditis.

## Conflict of interest

No conflict of interest.

## References

1. Pommier Th, Jeanmichel M, Yao H, Sagnard A, Vernay C, Leclercq Th (2020). Maladies du péricarde. In « Cardiologie et maladies vasculaires ». Edit. Masson., Page 192 : étiologies des maladies du péricarde
2. Idem. Page 193 : fréquence des étiologies des péricardites
3. Idem. Page 194 : tamponnade.
4. Suchin M, Vinod K, Narayanan U, Bipi P and Praveen S.(2023)Acute Purulent Pericarditis caused by *Klebsiella pneumoniae* in a patient ESRD on Hemodialysis. *Indian J Nephrol*;33(3):230-231.

5. Peter ID, Belonwu R, Asani MO, Aliyu I, Uma IU, Imam A (2016). Purulent Pericarditis Caused by Klebsiella pneumoniae in a Nigerian Child. J Pract Cardiovasc Sci;2:194-196.
6. Liang S, Cao H, Ying F, Zhang C. (2022). Report of a Fatal Purulent Pericarditis Case Caused by STII-K64 Carbapenem-Resistant Hypervirulent Klebsiella pneumoniae. Infection and Drug Resistance;15:4749-4757.
7. Vila GC, Flores E, Caldentey G. (2017;). Purulent Pericarditis Due to Klebsiella pneumoniae Pulmonary Infection. Rev Colomb Cardiol 24(4):417-418.
8. Thaneeru P, Sebastian C, Stiles M, Bhattacharya S. (2018). Purulent Pericarditis with Escherichia coli : a Rare Diagnostic. Heart Lung and Circulation;27(Suppl.) S339.



This work is licensed under Creative Commons Attribution 4.0 License

To Submit Your Article Click Here: [Submit Manuscript](#)

DOI: [10.31579/2641-0419/404](https://doi.org/10.31579/2641-0419/404)

**Ready to submit your research? Choose Auctores and benefit from:**

- fast, convenient online submission
- rigorous peer review by experienced research in your field
- rapid publication on acceptance
- authors retain copyrights
- unique DOI for all articles
- immediate, unrestricted online access

At Auctores, research is always in progress.

Learn more <https://www.auctoresonline.org/journals/journal-of-clinical-research-and-reports>