

Omental Infarction After Infectious Caesarian Section: A Case Report

Ahmad Reza Shahraki

General Surgeon, Assistant professor, Department of Surgery, Medical Faculty, Zahedan University of Medical Sciences and Health Services, Zahedan, Iran.

***Corresponding Author:** Ahmad Reza Shahraki, General Surgeon, Assistant professor, Department of Surgery, Medical Faculty, Zahedan University of Medical Sciences and Health Services, Zahedan, Iran

Received date: August 13, 2024; **Accepted date:** August 21, 2024; **Published date:** August 28, 2024

Citation: Ahmad R. Shahraki, (2024), Omental infarction after infectious caesarian section: A case report, *J, Clinical Case Reports and Studies*, 5(7); DOI:10.31579/2690-8808/213

Copyright: ©, 2024, Ahmad Reza Shahraki. This is an open access article distributed under the Creative Commons Attribution License, which permits unrestricted use, distribution, and reproduction in any medium, provided the original work is properly cited.

Abstract

There have been about 300 cases of omental infarction reported in literature. Omental infarction is a rare disease entity that can cause acute or subacute abdominal pain. In the past, it was thought that omental infarction mainly occurred on the right side because it was detected when surgery was performed on patients who complained of abdominal pain on the right side. Although the classical treatment of omental infarction is surgery, more recently the conservative management has been suggested. Thus, we believe that the knowledge of the characteristic imaging findings is essential for establish a correct preoperative diagnosis, which can avoid unnecessary surgical intervention. This case presentation wants to show rare results of abdominal surgery and following the patient after surgery is so important.

Our case was a 19 years old female with abdominal pain that underwent caesarian section 10 days before, that CT scan shows infection in uterine and abdomen and in laparotomy omental infarction and infected uterine was seen. After treatment she discharge healthy.

By adding omental infarction to the list of differential diagnoses in patients who present with acute abdominal pain, future management of patients with an acute abdomen can be adjusted for the optimal approach to not overlook any surgery-requiring diagnosis as well as to prevent overtreatment.

Key Words: omental infarction, caesarian section, abdominal pain, CT scan, emergency medicine

Introduction

Omental infarction is a rare disease entity that can cause acute or subacute abdominal pain. In the past, it was thought that omental infarction mainly occurred on the right side because it was detected when surgery was performed on patients who complained of abdominal pain on the right side [1]. Omental infarction is a rare condition that has not been well studied or well characterised in the literature. Because the treatment is supportive care, early recognition can reduce patient morbidity and minimise invasive workups and unwarranted treatments. As of now, the incidence of omental infarction has yet to be accurately determined and only 400 cases have been documented in the literature to date [2]. Omental infarction in adults is a rarely occurring phenomenon, with left-sided omental infarction being even more seldom [3]. Omental infarction is a rare disease that affects the entire omentum or a segment of the greater omentum, the cause of which sometimes remains elusive [4,5]. There have been about 300 cases of omental infarction reported in literature [6,7]. Although the classical treatment of omental infarction is surgery, more recently the conservative management has been suggested. Thus, we believe that the knowledge of the characteristic imaging findings is essential for establish a correct preoperative diagnosis, which can avoid unnecessary surgical intervention.

This case presentation wants to show rare results of abdominal surgery and following the patient after surgery is so important [8]. There are two main categories of omental infarctions primary and secondary [2]. Traditionally, omental infarctions were diagnosed during surgery. However, new advancements in imaging techniques have allowed for the diagnosis to be determined outside of surgery such as in our case. CT scans are the imaging studies of choice. Greater omental pathologies can be divided into four categories caking (the displacement of omental adipose tissue by soft tissue), fat stranding, cystic masses and discrete nodules [2]. We report this case because it is so rare and in common situation you can see.

Case presentation:

This case is about a 19 years old female that has caesarian section 10 days before and now referred to surgery parts with abdominal pain. We admit her and start examination that lab data's was normal but a low grade fever we detect. We do abominopelvic CT scan for her that shows about 500cc liquid in pelvic and because of suspicious for uterine damage in CT, we do laparotomy for her. We find pus in pelvic (figure1) and we search for source of infection that findings shows it is about uterine and procedure of caesarian

section. We find a necrotic and pale omentum (figure2) that express omental infarction. We wash and clean abdominopelvic and start conservative therapy and after 5 days we discharge her healthy.

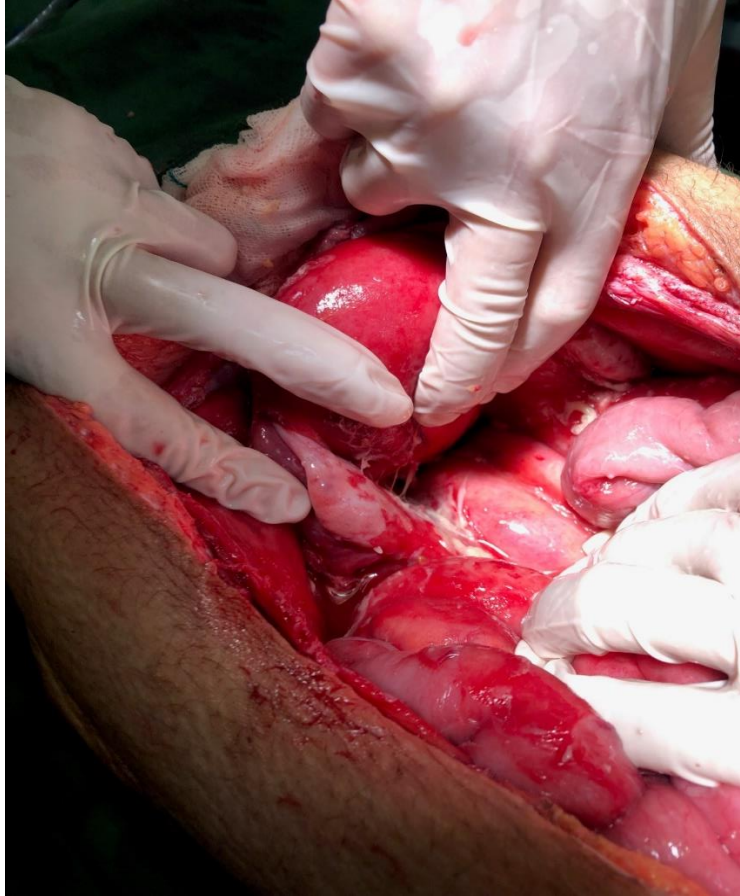


Figure 1: pus in pelvic

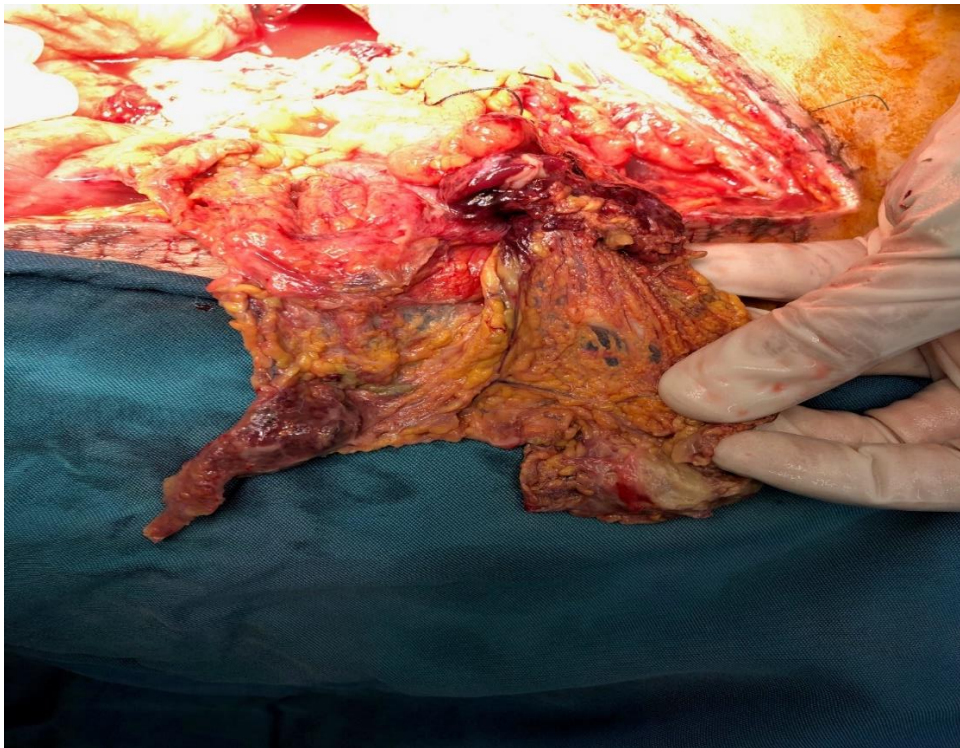


Figure 2: Omental infarction

Discussion:

A major challenge to the diagnosis of omental infarction is that it can mimic the classic presentation of an acute abdomen [2,13]. Based on patients' symptoms, they most commonly fit the picture of peritonitis. Laboratory values can show a non-specific inflammatory response [2,14].

Differential diagnosis: [9]

Ischaemic colitis.

Acute cholecystitis.

Epiplonic appendagitis.

Trauma.

Small bowel obstruction from adhesive disease from prior surgical intervention.

Ileus.

Diverticulitis.

Pancreatitis.

Ovarian cyst.

Ectopic pregnancy.

Although the classical treatment of omental infarction is surgery, more recently the conservative management has been suggested. Thus, we believe that the knowledge of the characteristic imaging findings is essential for establish a correct preoperative diagnosis, which can avoid unnecessary surgical intervention. This case presentation wants to show rare results of abdominal surgery and following the patient after surgery is so important [12]. Today there are two main strategies in the management of omental infarction, conservative and laparoscopic excision. Classical laparotomy is no longer performed due to its invasiveness compared with the conservative or laparoscopic approach [2]. Conservative management includes oral analgesic medications, anti-inflammatory medications and antibiotics. The advantage of early surgical intervention is the reduced incidence of necrosis, abscess formation and adhesion formation. Laparoscopic surgery can also decrease the patients' time in the hospital. A disadvantage of conservative management is that symptoms can persist for weeks with the mean time of resolution being 13.5 days [2]. However, there are the natural risks of laparoscopic surgery including complications with anaesthesia, intraoperative hazards and postoperative morbidity. In patients who are non-operative candidates due to comorbidities and conservative management remains a preferable option. In our case report, a conservative approach lead to symptom resolution [2].

Conclusion:

Omental infarction should be included in the differential diagnosis list of acute abdominal pain because it can occur at any site. In addition, because this disease runs a self-limited course, conservative care is recommended. Thus, unnecessary operations can be avoided in cases where omental infarction is diagnosed by imaging studies [1]. Omentum biological properties include Neovascularization, homeostasis, tissue healing and regeneration and as an in vivo incubator for cells and tissue cultivation. Some of these properties have long been noted in surgical practice and used empirically in several procedures [10]. Only in uncommon circumstances of unclear imaging findings or deterioration in the patient's conditions, a diagnostic laparoscopy as a minimal invasive approach may settle the diagnosis and can be extended to a therapeutic maneuver [11]. By adding omental infarction to the list of differential diagnoses in patients who present with acute abdominal pain, future management of patients with an acute abdomen can be adjusted for the optimal approach to not overlook any surgery-requiring diagnosis as well as to prevent overtreatment [1].

Learning points: [2]

Omental infarction should be included in the differential diagnosis list of acute abdominal pain in order to prevent unnecessary surgical interventions.

Traditionally, omental infarctions were diagnosed during surgery. New advancements in imaging techniques have allowed for the diagnosis and it is important to be aware of imaging findings consistent with the diagnosis.

This disease appears to be a self-limited course, treated with conservative care including pain control and fluids.

Unnecessary operations, consultations and treatments can be avoided in cases where omental infarction is diagnosed by imaging studies

Declarations:

Ethical Approval and Consent to participate:

The content of this manuscript are in accordance with the declaration of Helsinki for Ethics. No committee approval was required. Oral and written consent to participate was granted by her husband.

Consent for publication:

“Written informed consent was obtained from the patient's legal guardian for publication of this case report and any accompanying images. A copy of the written consent is available for review by the Editor-in-Chief of this journal.”

Availability of supporting data

It is available.

Competing interests:

The author declares that they have no competing financial interests and nothing to disclose.

Funding: There is no funding.

Authors' contributions:

Ahmad Reza Shahraki is the surgeon of patient and writes this paper.

The author declares that they have no competing financial interests and nothing to disclose.

Acknowledgements

Although the classical treatment of omental infarction is surgery, more recently the conservative management has been suggested. Thus, we believe that the knowledge of the characteristic imaging findings is essential for establish a correct preoperative diagnosis, which can avoid unnecessary surgical intervention. This case presentation wants to show rare results of abdominal surgery and following the patient after surgery is so important.

References:

1. Park TU, Oh JH, Chang IT, Lee SJ, Kim SE, et. al., (2012). Omental infarction: case series and review of the literature. *J Emerg Med.* 42(2):149-154.
2. McMillen B, Hekman DP, Nguyen MTT, Grewal D. (2019). Idiopathic omental infarction: managed conservatively. *BMJ Case Rep.* 12(3).
3. Nijkamp JLG, Gerretsen SC, Stassen PM. Left-sided omental infarction: a rare cause of abdominal pain, discovered by CT scan. *BMJ Case Rep.* 2018.
4. Aoun N, Haddad-Zebouni S, Slaba S, Noun R, Ghossain M (2001). Left-sided omental torsion: CT appearance. *Eur Radiol* 11(1):96-98.

5. Singh AK, Gervais DA, Lee P, Westra S, Hahn PF, Novelline RA, Mueller PR (2006) Omental infarct: CT imaging features. *Abdom Imaging* 31(5):549-554.
6. Tachezy M, Grotelüschen R, Gebauer F, Marx AH, Izbicki JR, Kaifi JT (2010) Omental infarction in the postpartum period: a case report and a review of the literature. *J Med Case Rep* 4:368.
7. Naffaa LN, Shabb NS, Haddad MC (2003) CT findings of omental torsion and infarction: case report and review of the literature. *Clin Imaging* 27(2):116-118.
8. Ahmad Reza Shahraki, Reza Abaee, Elham Shahraki. (2023). Omental Infarction after Infectious Uterine Underwent Caesarian Section: A Case Report. *International Journal of Innovative Research in Medical Science (IJIRMS)* Volume 08, Issue 12.
9. McMillen B, Hekman DP, Nguyen MTT, Grewal D. (2019). Idiopathic omental infarction: managed conservatively. *BMJ Case Rep.* 12(3).
10. Di Nicola, V. (2019). Omentum a powerful biological source in regenerative surgery. *Regenerative therapy*, 11, 182-191.
11. Ahmad Reza Shahraki et al, (2024). East African Scholars *J Med Surg*; Vol-6, Iss-2: 64-66.
12. Ahmad Reza Shahraki, Reza Abaee, Elham Shahraki. Omental Infarction after Infectious Uterine Underwent Caesarian Section: A Case Report. *International Journal of Innovative Research in Medical Science (IJIRMS)* Volume 08, Issue 12.
13. Lindley SI, Peyser PM. (2018). Idiopathic omental infarction: one for conservative or surgical management? *J Surg Case Rep.*
14. Occhionorelli S, Zese M, Cappellari L, et al., (2014). Acute abdomen due to primary omental torsion and infarction. *Case Rep Surg*, 1-4.



This work is licensed under Creative Commons Attribution 4.0 License

To Submit Your Article Click Here: [Submit Manuscript](#)

DOI:10.31579/2690-8808/213

Ready to submit your research? Choose Auctores and benefit from:

- fast, convenient online submission
- rigorous peer review by experienced research in your field
- rapid publication on acceptance
- authors retain copyrights
- unique DOI for all articles
- immediate, unrestricted online access

At Auctores, research is always in progress.

Learn more <https://auctoresonline.org/journals/journal-of-clinical-case-reports-and-studies>