

Role of Autologous Platelet Rich Plasms (Aprp) In the Take of Full Thickness Skin Graft in Post Burn Contracture

Manoj Kumar S¹, Ravi Kumar Chittoria^{2*}, Neljo Thomas³, Nishad K³, M Vijayaraghavan⁴, Sanikommu Dheeraj Reddy⁴

¹Junior Resident, General Surgery, Department of Plastic Surgery, JIPMER, Pondicherry, India.

²Professor & Registrar (Academic), Head of IT Wing and Telemedicine, Department of Plastic Surgery & Telemedicine, JIPMER, Pondicherry, India.

³Senior Resident, Department Of Plastic Surgery, JIPMER, Pondicherry, India.

⁴Junior resident, Department of general surgery, JIPMER, Pondicherry, India.

***Corresponding Author:** Ravi Kumar Chittoria, Professor & Registrar (Academic), Head of IT Wing and Telemedicine, Department of Plastic Surgery & Telemedicine, JIPMER, Pondicherry, India.

Received date: December 20, 2021; Accepted date: January 04, 2022; Published date: January 10, 2022

Citation: Manoj K S, Ravi K Chittoria, N Thomas, Nishad K, M Vijayaraghavan, Sanikommu D Reddy. (2022). Severe Urticaria Reaction in Energy Deficient Patient Post-COVID-19 Vaccine. *Dermatology and Dermatitis*. 7(1); DOI:10.31579/2578-8949/163

Copyright: ©2021 Ravi Kumar Chittoria, This is an open-access article distributed under the terms of The Creative Commons. Attribution License, which permits unrestricted use, distribution, and reproduction in any medium, provided the original author and source are credited.

Abstract

All deeper burns especially second degree deep dermal and full thickness heals by scarring that causes restrictions in the movements and aesthetics issues for patients. Burn reconstructive surgery requires that the defects after release should be replaced with donor tissues which have matching texture and colour like autologous skin grafting or flap surgeries. Autologous platelet rich plasma contains concentrated platelets after graded centrifugation, which has various applications like alopecia, acne, reproductive techniques etc. Here we are using this method to test for role in take of Full Thickness Skin Graft post burn contracture. Full-thickness skin grafts include full thickness of the epidermis and dermis whereas split-thickness skin grafts include the entire epidermis and only partial dermis. The main complication of this procedure is risk of graft failure. Autologous platelet-rich plasma (APRP) as the name suggests is concentration of the patient's own platelets in a small amount of plasma. It is enriched by growth factors, and it acts as a fibrin sealant and has various properties. Its important application is in skin grafting where it aids as a fibrin sealant and aids in the take of the graft by enriching it with growth factors and promoting angiogenesis The purpose of this case report is using autologous platelet rich plasma as a therapeutic method for accelerating take of Full Thickness Skin Graft in post burn contracture with better prognosis.

Keywords: Aprp; ftsg; post burn contracture

Introduction

Burn trauma constitutes the second most common cause of trauma-related deaths after vehicular accidents, in both developing and developed country. An extensive burn is the most devastating injury that human being had to suffer. After immediate concern for survival in victim, restoration to pre-injury status, and return to daily activities becomes important for victim and treating team [1]. A healed burn patient may be left with contractures and scars with varying degrees of functional issues and cause social stigma among victims.

Materials and Methods

This study was conducted in Plastic surgery department in a tertiary care centre in the month of November-December 2021. The patient is a case of post burn contraction of right index and middle finger, with restriction of daily activities. Release of post burns contracture with Full Thickness Skin Graft (FTSG) assisted by Autologous Platelet Rich Plasma (APRP)

and K -wire fixation was done. Total 5 cycles of APRP were given to the patient

Results

Application of APRP helped in achieving better FTSG uptake.

Discussion

Autologous Platelet rich plasms (APRP) is a biological product defined as a portion of the plasma fraction of autologous blood with a platelet concentration above the baseline.[2] The contents of the APRP are not only platelets, but also growth factors such as platelet-derived growth factors, chemokines, clotting factors, and fibrin.

The concept and description of PRP started in the field of haematology [3]. It was used for patients with thrombocytopenia. In the coming days, PRP has been used in various other fields such as musculoskeletal field in sports injuries, cardiac surgery, paediatric surgery, gynaecology, urology, plastic surgery, and ophthalmology.

Owing to its contents, the use of APRP has been researched in the field of regenerative medicine in conditions such as alopecia, chronic wounds, and scar management.

The mainstay management of wounds is skin grafting. The main part of the skin graft is the take of the graft, which is in three stages:

1. Stage of imbibition
2. Stage of inosculation
3. Stage of revascularization.

PRP aids in bridging the stages of skin graft take.

PRP functions as a tissue sealant and drug delivery system, with the platelets initiating wound repair by releasing locally acting growth factors

via α -granules degranulation.[4] The application of APRP to STSG application sites has been recently described and theorized to provide immediate skin graft anchorage as well as inosculation of the STSG with nutrient-rich blood media[5]. Some study on burns patients, have proven that PRP is safe and effective for fixation of skin grafts due to its adhesive nature, and its outcomes are better than securing skin graft to wound margins or bed with sutures, staples, or glue, hence it not only decreases the surgery time but also avoids the removal of sutures/staplers in postoperative period [6].

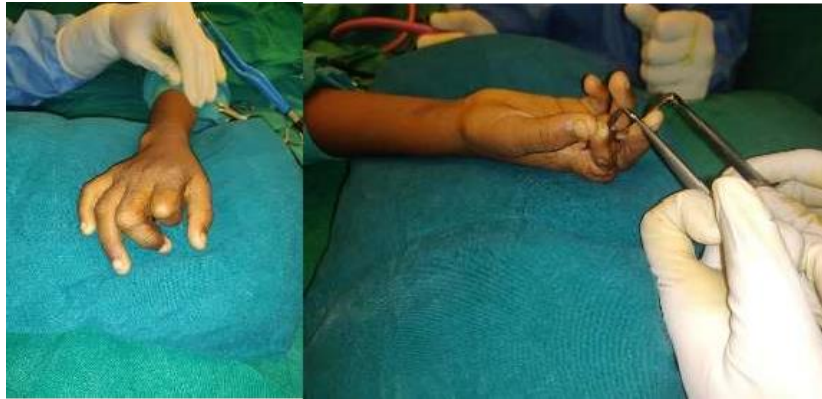


Figure 1: Post Burn Contracture of Index Finger and Middle Finger

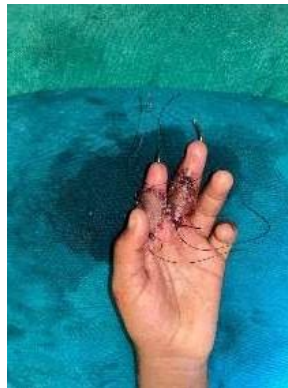

Figure 2: Post Burn Contracture Release and Full Thickness Skin Graft done

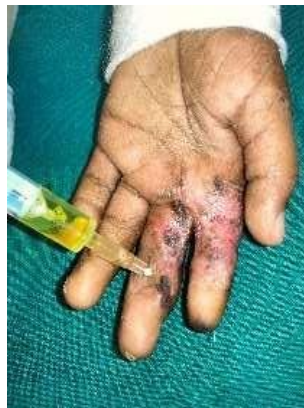

Figure 3: Autologous Platelet Rich Plasma

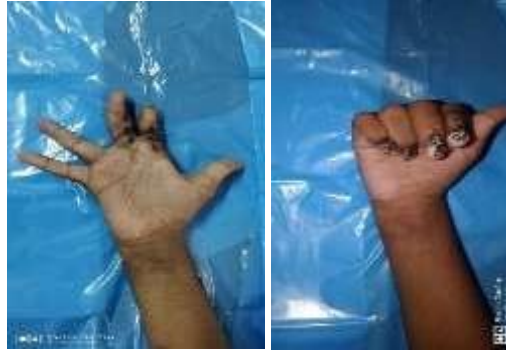

Figure 4: At discharge with well healed Full Thickness Skin Graft

Previous study conducted by Puttirutvong [7] has evaluated the healing time of both meshed full-thickness skin grafts versus STSGs (i.e., 0.015-in thickness) in patients with diabetes. This study revealed a mean total healing time of 20.1 ± 7.3 days for the STSG group, with the primary factor affecting graft take being hematoma/seroma formation and infection. Vijayaraghavan *et al* [8] showed that wounds treated with APRP therapy alone healed in 4–8 weeks. Wounds treated with APRP, and split skin graft/flap cover healed in 3–6 weeks.

Conclusions

In our study we found that APRP was useful in promoting FTSG uptake. The limitation of the study includes that it is a case report with a single centre study with no statistical analysis. Further randomised controlled studies are required to validate the efficacy of the LLLT in the uptake of FTSG post burn contracture.

References

1. Franco D, Franco T, Schettino AM, Filho JM, Vendramin FS. (2012). Protocol for obtaining PRP for autologous use. *Aesthetic Plast Surg.* 36:1254-1259.
2. Alves R, Grimalt R. (2016). Randomized placebo-controlled, double-blind, half-head study to assess the efficacy of platelet-rich plasma on the treatment of androgenetic alopecia. *Dermatol Surg.* 42:491-497.
3. Andia I, Abate M. (2013). Platelet-rich plasma: underlying biology and clinical correlates. *Regen Med.* 8:645-658.
4. Thimmanahalli G, Kumar M. (2018). Efficacy of autologous platelet rich plasma over conventional mechanical fixation methods in split thickness skin grafting. *Int Surg J.* 6:108.
5. Schade VL, Roukis TS. (2008). Use of platelet-rich plasma with split-thickness skin grafts in the high-risk patient. *Foot Ankle Spec.* 1:155-159.
6. Gibran N, Luterman A, Herndon D, Lozano D, Greenhalgh DG, Grubbs L, et al. (2007). Comparison of fibrin sealant and staples for attaching split-thickness autologous sheet grafts in patients with deep partial- or full-thickness burn wounds: a phase 1/2 clinical study. *J Burn Care Res.* 28:401-408.
7. Puttirutvong P. (2004). Meshed skin graft versus split thickness skin graft in diabetic ulcer coverage. *J Med Assoc Thai.* 87:66-72.
8. Vijayaraghavan N, Mohapatra DP, Friji MT, Arjun A, Bibilash BS, Pandey S, et al. (2014). Role of autologous platelet rich plasma (APRP) in wound healing. *J Soc Wound Care Res.* 7:230-238.



This work is licensed under Creative Commons Attribution 4.0 License

To Submit Your Article Click Here:

Submit Manuscript

DOI:10.31579/2578-8949/091

Ready to submit your research? Choose Auctores and benefit from:

- fast, convenient online submission
- rigorous peer review by experienced research in your field
- rapid publication on acceptance
- authors retain copyrights
- unique DOI for all articles
- immediate, unrestricted online access

At Auctores, research is always in progress.

Learn more <https://auctoresonline.org/journals/dermatology-and-dermatitis>