

# Rare Tumor of oral Cavity: soft Palate Hemangioma: Case Report and Literature Review

Rajaa El Azzouzi <sup>1,3\*</sup>, Kawtar Ayyad <sup>2,3</sup>, Bouchra Dani <sup>1,3</sup>, Malik Boulaadas <sup>1,3</sup>, Houssayni leila Essakalli <sup>2,3</sup>

<sup>1</sup>Department of Maxillofacial Surgery Hospital of Specialities Rabat, Morocco.

<sup>2</sup>Department of Otolaryngology and neck surgery Hospital of Specialities Rabat, Morocco.

<sup>3</sup>Faculty of Medicine and Pharmacy of Rabat. Mohammed V University in Rabat, Rabat, Morocco.

**\*Corresponding Author:** Rajaa El Azzouzi, Department of Maxillofacial Surgery Hospital of Specialities; CHU Ibn Sina, Av. Abderrahim Bouabid, Rabat-Morocco. BP 1382 RP. 10001 Rabat, Maroc

**Received date:** March 27, 2024; **Accepted date:** April 02, 2024; **Published date:** April 08, 2024

**Citation:** Rajaa El Azzouzi, Kawtar Ayyad, Bouchra Dani, Malik Boulaadas, Houssayni L. Essakalli, (2024), Rare Tumor of Oral Cavity: soft Palate Hemangioma: Case Report and Literature Review, *Clinical Research and Clinical Trials*, 9(5); DOI:10.31579/2693-4779/200

**Copyright:** © 2024, Rajaa El Azzouzi. This is an open access article distributed under the Creative Commons Attribution License, which permits unrestricted use, distribution, and reproduction in any medium, provided the original work is properly cited.

## Abstract:

Hemangiomas are benign tumors of blood vessel characterized by hyperplasia of venous and capillary structures embedded in the submucosal connective tissue. Most hemangiomas are observed in the head and neck region; however, the oral cavity is a rare location and palatal hemangiomas are uncommon with an occurrence of less than 3% of oral hemangiomas.

We report a rare location of hemangioma on the soft palate in a 25-year-old man. The lesion was diagnosed by histopathology after a biopsy and the patient underwent a total surgical excision. And by a literature review we will describe the clinical, histological, therapeutic features and the prognosis of this rare tumor.

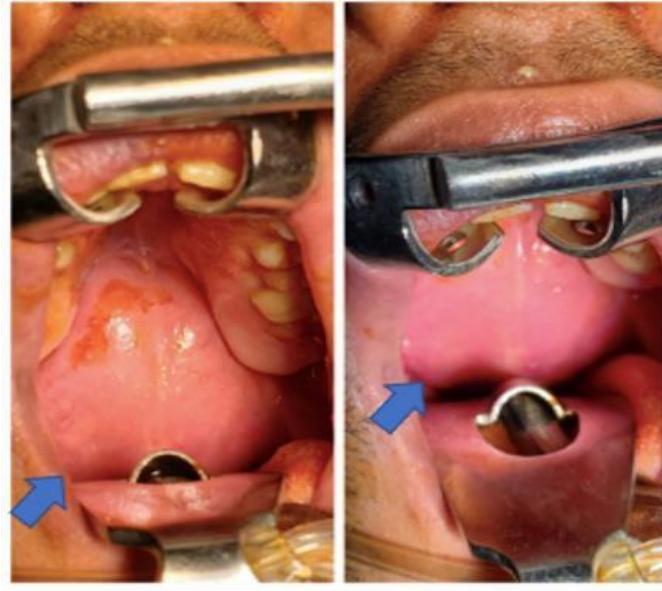
**Keywords:** case report; hemangioma; soft palate; oral cavity tumors

## Introduction

Hemangioma is a benign tumor of vaso-formative origin that is characterized by abnormal expansion of veins and capillaries settled in the submucosal connective tissue. Commonly seen in a younger population and represent the most common head and neck neoplasm at the pediatric age. Generally, 60%-70% of hemangiomas are observed in the head and neck; however, the oral cavity is still an uncommon location [1]. They may be observed in lips, buccal mucosa and tongue but the hard, soft palates and uvula are rarely affected. Their occurrence on the palatal mucosa is extremely rare. The present case report is an extremely rare site of hemangioma involving the soft palate.

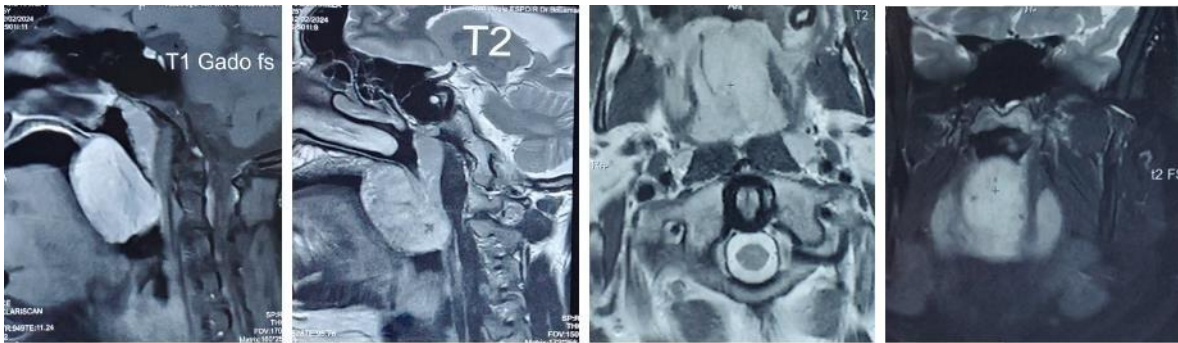
## Case report:

We report the case of a 25-year-old patient, with psychomotor retardation and no other medical history, admitted to our department for management of a soft palate mass, discovered 3 years ago by the family, which has since, progressively increased in volume with dysphagia, phonation disorders and no associated dyspnea. On clinical examination, the mass was soft, painless, with no-thrilling and normal-looking mucosal covering, no bleeding on contact, measuring approximately 4 cm long (Figure 1).



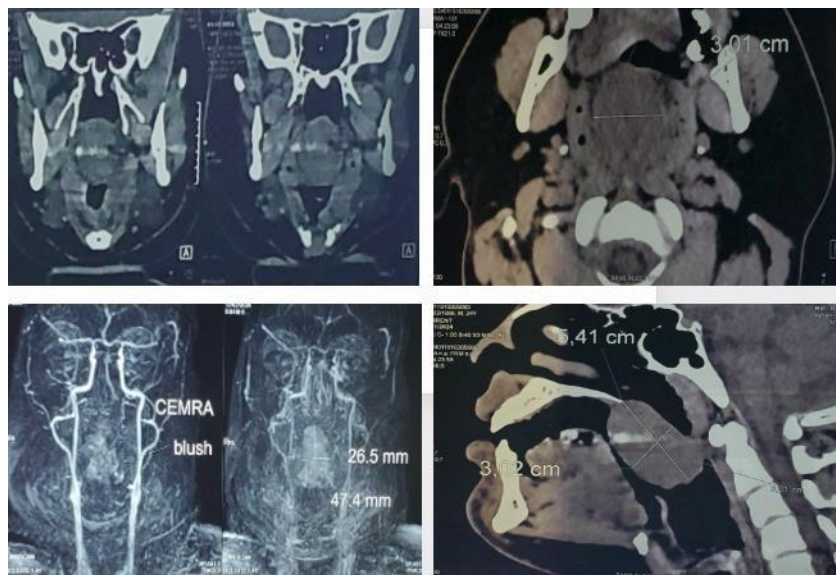
**Figure 1:** Intraoral view of the soft palate mass.

Radiological examination was carried out: Facial MRI: Mass of the soft palate, regular and homogeneous, discretely hyperintense in T1 and T2, with moderate contrast in late arterial time without consequent on venous return, partially obstructing the oro-pharyngeal tract (Figure 2)



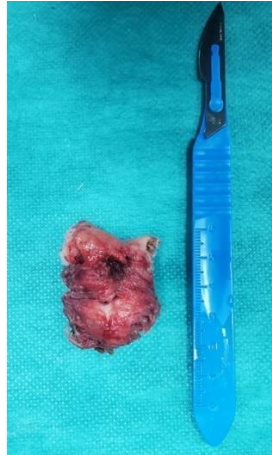**Figure 2:** IMR in axial coronal and sagittal sections showing the soft palate hemangioma.

Cranio-facial CT: Soft palate mass measuring 30 x 30 x 54 mm, well limited, with no associated bone lysis (Figure 3).



**Figure 3:** Cervico-facial CT scan in coronal, axial, sagittal section showing the soft palate hemangioma.

A biopsy was first performed, anatomopathological study revealed a velar hemangioma diagnosis; the patient subsequently underwent a complete removal of the mass under general anesthesia (Figure 4), the final anatomopathological result confirmed the diagnosis of soft palate hemangioma.



**Figure 4:** Macroscopic appearance of soft palate hemangioma.

### Discussion:

Hemangioma is a benign tumor of vaso-formative origin that is characterized by abnormal expansion of veins and capillaries settled in the submucosal connective tissue with no malignant potential. Hemangioma is further sub classified based on their histological appearance as: cavernous lesions, capillary lesions and mixed lesions. A sclerosing variety also occurs that tends to undergo spontaneous fibrosis.

They are considered to be the most common tumor of childhood, occurring in about 5–10% of children <1 year of age, exhibiting a rapid growth phase with endothelial cell proliferation followed by gradual involution [2]. There is however an additional neoplastic form that appears in middle life or in older people [3]. However, more than 50% are found in patients >40 years of age. Generally, 60%-70% of hemangiomas are observed in the head and neck [1]. The lips, buccal mucosa and tongue are the most common sites of occurrence, while the hard and soft palates and uvula are rarely affected. Palatal hemangioma is uncommon, with fewer than 3% of the cases occurring in the site [4]. In the oral cavity they may occur in any area, at any age, without any racial or gender predilection.

Clinical examination reveals a well circumscribed, smooth, or lobulated blue red colored, painless and compressible swelling that refill slowly after releasing the compression, of variable volume, that can even cause airway obstruction and may bleed profusely in some cases, spontaneously or following trauma. [5]. Usually, congenital. These growths may not manifest themselves for years and spontaneous remission is unlikely during adulthood.

Radiographic imaging as CT scan and MRI are useful for analyzing exact features of the lesion, such as the size, location, extension, and relation with surrounding vital structures. They are also used for differential diagnosis. The varied appearance of soft palate hemangioma, mimic other lesions such as pyogenic granuloma, epulis granulomatosa, telegenctesia, angiosarcoma or squamous cell carcinoma [3,6] histopathological examination is important for a final diagnosis.

MRI is superior to CT for evaluating soft tissue masses. In MRI, these tumors typically show low-signal intensity on T1-weighted images and high-signal intensity on T2-weighted images. The angiography shows hemangioma as well-circumscribed lesions with intense tissue staining and demonstrates afferent and efferent vascular supply.

Management of hemangioma depends on several factors, the size, location, extent, clinical characteristics of the lesion, the age and patient oriented

issues. Most of the hemangiomas are managed conservatively and require no intervention; The watch and wait policy.

However, 10–20% requires treatment. The range of treatment includes intralesional or systemic corticosteroid therapies, surgical excision, immunomodulatory therapies, embolization techniques and electrocoagulation while cryosurgery are the most popular, sclerotherapy is favored because of its efficiency and ability to secure the surrounding structures [7]. Indications for surgery are no evidence for involution, very large tumors with involvement of the adjacent structures, symptomatic (hemorrhage and infection) tumors, or cosmetic risk [7]. In the present case, surgery was carried out on the basis of size, location, the tumor's evolutionary profile, its extension and the association of dysphagia and phonation disorders.

### Conclusion:

Hemangiomas are benign tumors of blood vessel, most frequently observed in the head and neck region, however the soft palate localization is very rare and can be confused with other diagnosis which require a careful clinical and radiological evaluation. Several treatment modalities exist, that should be patient specific and depend on the tumor features. In the case of surgery option, an adequate measure to control bleeding should be encouraged.

### References:

- 1- Kamala KA, Ashok L, Sujatha GP. (2014). Cavernous hemangioma of the tongue: A rare case report. *Contemp Clin Dent* ; 5 : 95-98.
- 2- Neville BW, Damm DD, Allen CM et al. (2008). *Oral and maxillofacial pathology*. 3rd edn St Louis: Saunders,
- 3- Acikgoz A, Sakallioglu U, Ozdamar S et al. (2000). Rare benign tumours of oral cavity—capillary hemangioma of palatal mucosa: a case report. *Int J Paediatr Dent* ;10 :161-165.
- 4- Lale AM, P. Coleman, Ellis PD, a palatal haemangioma in a child. *J laryngol otol* 1998; 112; 677-678.
- 5- V P, Puppala N, Deshmukh SN, B J, S A. Cavernous hemangioma of tongue: management of two cases. *J Clin Diagn Res* 2014 ; 8 : 15-17.
- 6- Gill JS, Gill S, Bhardwaj A et al. (2012). Oral haemangioma. *Case Rep Med*
- 7- Kamala KA, Ashok L, Sujatha GP. (2014). Cavernous hemangioma of the tongue: A rare case report. *Contemp Clin Dent* ; 5 : 95-98.



This work is licensed under Creative Commons Attribution 4.0 License

To Submit Your Article Click Here:

**[Submit Manuscript](#)**

**DOI:10.31579/2693-4779/200**

**Ready to submit your research? Choose Auctores and benefit from:**

- fast, convenient online submission
- rigorous peer review by experienced research in your field
- rapid publication on acceptance
- authors retain copyrights
- unique DOI for all articles
- immediate, unrestricted online access

At Auctores, research is always in progress.

Learn more <https://auctoresonline.org/journals/clinical-research-and-clinical-trials>