

# Colocutaneous Fistula after Gastrostomy Tube Replacement without an Endoscopic view of a Previous Percutaneous Endoscopic Gastrostomy: A Case Report

Felipe Anduquia-Garay \*, Yesica Cardona-Ríos, Paydieg Márquez, Dana Vargas, Cher Guzmán, Lorena Gutiérrez, Victor Melo, Bernardo Borraez-Segura

Student at the Technological University of Pereira Pereira, Risaralda Department, Colômbia.

**Corresponding Author:** Felipe Anduquia-Garay, Student at the Technological University of Pereira Pereira, Risaralda Department, Colômbia.

**Received date:** December 29, 2023; **Accepted date:** January 08, 2023; **Published date:** January 16, 2023

**Citation:** Felipe Anduquia-Garay, Yesica Cardona-Ríos, Paydieg Márquez, Dana Vargas, Cher Guzmán, et al., (2023), Colocutaneous Fistula after Gastrostomy Tube Replacement without an Endoscopic view of a Previous Percutaneous Endoscopic Gastrostomy: A Case Report, *J Thoracic Disease and Cardiothoracic Surgery*, 4(6); DOI:10.31579/2693-2156/075

**Copyright:** © 2023, Felipe Anduquia-Garay. This is an open access article distributed under the Creative Commons Attribution License, which permits unrestricted use, distribution, and reproduction in any medium, provided the original work is properly cited.

## Abstract

**Background:** Percutaneous endoscopic gastrostomy (PEG) has become a widely used technique to provide a safe, simple and inexpensive route for enteral nutrition. Despite the precautions, numbers of complications have been described in the literature. Complications after a procedure like bleeding, injury to internal organs, tumor seeding, infections, or gastrocolocutaneous can occur with rates that range between 0,4 - 22.5%.

Colocutaneous fistula is an unusual complication that can present as intractable diarrhea after feeding. A proper technique of PEG placement including transillumination and finger palpation are key preventive measures. The aim of our paper is to describe a case of a colocutaneous fistula after gastrostomy tube replacement without an endoscopic view of a previous PEG. Our case shows the importance of endoscopic vision for gastrostomy tube replacement.

**Keywords:** heart transplantation; organ donor; primary graft failure; data base analysis

## Background

Percutaneous endoscopic gastrostomy (PEG) has become a widely used technique to provide a safe, simple and inexpensive route for enteral nutrition. Despite the precautions, numbers of complications have been described in the literature. Complications after a procedure like bleeding, injury to internal organs, tumor seeding, infections, or gastrocolocutaneous can occur with rates that range between 0,4 - 22.5% [1].

Colocutaneous fistula is an unusual complication that can present as intractable diarrhea after feeding. A proper technique of PEG placement including transillumination and finger palpation are key preventive measures [2]. The aim of our paper is to describe a case of a colocutaneous fistula after gastrostomy tube replacement without an endoscopic view of a previous PEG. Our case shows the importance of endoscopic vision for gastrostomy tube replacement.

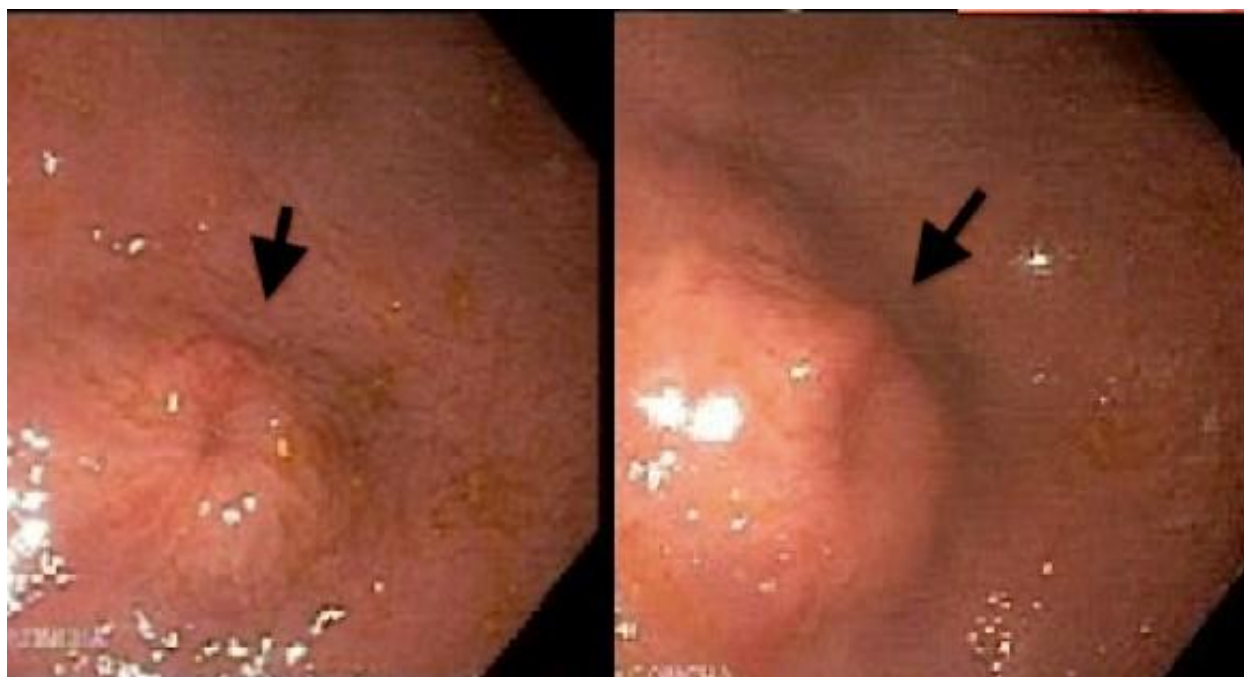## Case Report

An 88-year-old man with a history of ischemic stroke 7 years ago, convulsive syndrome, atrial fibrillation and chronic kidney disease, had a PEG tube inserted at our clinic 6 months before for enteral nutrition without any complications.

The gastrostomy tube was functional and useful for those 6 months for feeding and medication administration, at which time a tube replacement was performed without an endoscopic view in an external hospital.

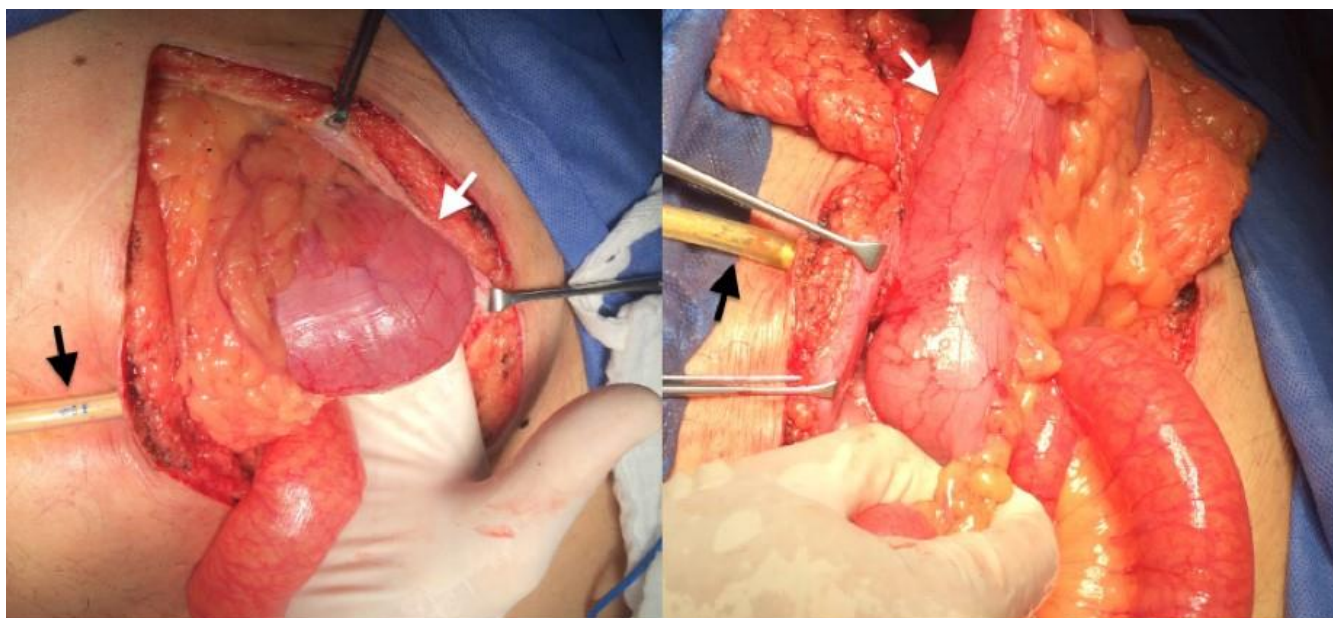
The patient was admitted twelve days later in the emergency room with several episodes of diarrhea and abdominal pain. Abdomen exploration was unreliable, with a normal white blood cells count, a low serum albumin/protein levels and a stool sample incompatible with infection.

After evidence of a persistent intractable and white colored diarrhea, the gastroenterology and surgery teams were consulted, who decided to perform an upper endoscopy with an absent gastrostomy tube in the stomach. Figure 1.

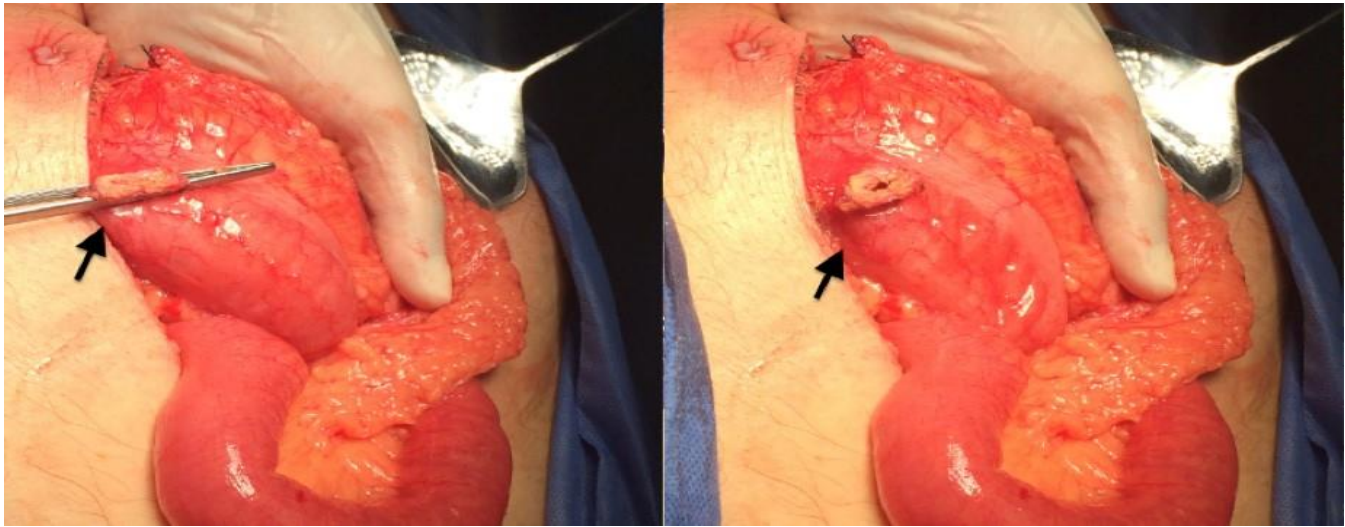


**Figure 1:** Absent gastrostomy tube in the stomach.

Colocutaneous fistula was diagnosed and the patient underwent a laparotomy. At the time of surgery, no injuries or signs of previous connection with the stomach were seen and PEG was located into the transverse colon. Figure 2. The colocutaneous fistula was excised, the colonic hole was closed, and a regular open gastrostomy performed without any complications. Figure 3. The patient was discharged 5 days after the procedure with an uneventful postoperative course.



**Figure 2:** PEG was located into the transverse colon.



**Figure 3:** Regular open gastrostomy performed.

## Discussion

Percutaneous endoscopic gastrostomy is an effective, simple, inexpensive and widely used procedure to provide a safe route for enteral feeding. First introduced by Ponsky and Gauderer in 1980, the gastrostomy tube can be used in different types of acute and chronic diseases associated with malnutrition and/or swallowing disorders [1].

Despite the precautions and using a proper technique, complications are described, generally minor with peristomal infection being the most common and easily manageable, with low rates that range between 13–43% and major complications that do not exceed 22%. Complications mainly occur in elderly, multi-pathological, malnourished patients and those with a history of bronchospasm or infections. Furthermore, the technique has a very low mortality rate (0–2%), although this percentage increases at 30 days (6.7–26%), especially in patients with cardiovascular comorbidities. [1].

Colocutaneous fistula is a rare complication that occurs as a result of the interposition of the colon between the anterior abdominal and gastric wall, it may present as intractable diarrhea after feeding (watery or white colored diarrhea), abdominal pain, fecal leakage around the tube and other symptoms (upper gastrointestinal symptoms) [3]. In some patients as reported in the literature, symptoms can start soon after the tube replacement [4].

Our patient had some risk factors for PEG related complications as reported by Lucendo et al [5]. as being older than 75 years old, malnutrition (low serum albumin levels) and multiple comorbidities (coexistence of congestive heart failure, renal failure, urinary tract infection, previous aspiration, chronic pulmonary disease, coagulopathy, circulation disorders, metastatic cancer, and liver disease). Another risk factor reported in the literature is the presence of infection, demonstrated with a high C-reactive protein levels and abnormal leukocyte counts [5]. but our patient didn't meet these criteria.

Complications can be minimized when using a proper technique during the procedure, the reasons for failure include an inappropriate transillumination or position (bed elevation up to 30 degrees), with inappropriate techniques (approximation of the gastric and abdominal walls) and unsafe tract (air return and endoscopic visualization of the

needle). With the proper technique, the success rate ranges from 76% to 100% [5-6].

A CT scan, colonoscopy and a fistulogram can be useful to determine the location of the gastrostomy tube and to plan a surgical repair, with treatment options ranging from the conservative tube extraction to surgical management (exploratory laparotomy). The small number of cases reported in the literature makes it difficult to draw conclusions on the best treatment [7].

We were surprised to find that the stomach didn't show evidence of perforation and that the gastric wall was completely intact, without any scare tissue, and we can speculate that the gastrostomy tube migrated to the colon probably secondary to a high tension.

In any case in our report, which is unique, it is difficult to determine if the gastrostomy tube migrated from the stomach to the colon after PEG or if it was a colon perforation after gastrostomy tube replacement without an endoscopic view. This case demonstrates the importance of: a) Using a proper technique during the procedure and b) Using an endoscopic view for gastrostomy tube replacement.

## References

1. Molina C, Vázquez JA, Gallardo F. (2019). Percutaneous endoscopic gastrostomy. Indications, care and complications. *Med Clin (Barc)*, 152(6):229-236.
2. Burke DT, Geller AI, Carayannopoulos AG, Goldstein R. (2011). Inadvertent Percutaneous Endoscopic Gastrostomy Tube Placement through the Transverse Colon to the Stomach Causing Intractable Diarrhea: A Case Report. *Diagn Ther Endosc*, 2011:849460.
3. Emmett DS, Polter DE. (2008). Colocutaneous fistula after a PEG. *Gastrointest Endosc.*, 68(4):770.
4. Aschl G, Fritz E, Stadler B, Fleischer M, Priglinger H, Knoflach P. et al. (2010). Kolokutane Fistel nach PEG-Anlage mittels Introducer-Technik mit Gastropexie [Colocutaneous fistula after a PEG procedure with introducer technique and gastropexy]. *Z Gastroenterol*, 48(7):760-762.

5. Lucendo AJ, Friginal-Ruiz AB. (2014). Percutaneous endoscopic gastrostomy: An update on its indications, management, complications, and care. *Rev Esp Enferm Dig*, 106(8):529-539.
6. Blumenstein I, Shastri YM, Stein J. (2014). Gastroenteric tube feeding: techniques, problems and solutions. *World J Gastroenterol*, 20(26):8505-8524.
7. Okutani D, Kotani K, Makihara S. (2008). A case of gastrocolocutaneous fistula as a complication of percutaneous endoscopic gastrostomy. *Acta Med Okayama.*, 62(2):135-138.



This work is licensed under Creative Commons Attribution 4.0 License

To Submit Your Article Click Here: [Submit Manuscript](#)

DOI:10.31579/2693-2156/075

**Ready to submit your research? Choose Auctores and benefit from:**

- ❖ fast, convenient online submission
- ❖ rigorous peer review by experienced research in your field
- ❖ rapid publication on acceptance
- ❖ authors retain copyrights
- ❖ unique DOI for all articles
- ❖ immediate, unrestricted online access

At Auctores, research is always in progress.

Learn more at: <https://auctoresonline.org/journals/journal-of-thoracic-disease-and-cardiothoracic-surgery>