

# Spontaneous Skin Infection Secondary to *Mycobacterium Abscessus Var Massiliense* in An Immunocompetent Patient

Pérez-Campos Laura Areli <sup>1</sup>, Pérez-Nieto José E <sup>2\*</sup>, Olmedo-Reneaum Alejandro <sup>3</sup>, and Molina-Jaimes Aaron <sup>4</sup>

<sup>1</sup> Internal Medicine Resident, Hospital Regional de Alta Especialidad Bicentenario de la Independencia ISSSTE, Tultitlan, State of México, México.

<sup>2</sup> Internal Medicine Resident, Hospital General Tacuba, Mexico City, Mexico.

<sup>3</sup> Infectology resident, Instituto Nacional de Cancerología, Mexico City, Mexico.

<sup>4</sup> Infectologist, Infectology Service, Hospital Regional de Alta Especialidad Bicentenario de la Independencia ISSSTE, Tultitlan, State of México, México.

**\*Corresponding Author:** José Eduardo Pérez Nieto, Hospital General Tacuba, Ciudad de México, México.

**Received date:** December 29, 2023; **Accepted date:** January 17, 2024; **Published date:** February 12, 2024

**Citation:** Pérez-Campos Laura A., Pérez-Nieto José E., Olmedo-Reneaum Alejandro, and Molina-Jaimes Aaron, (2024), Spontaneous Skin Infection Secondary to *Mycobacterium Abscessus Var Massiliense* in An Immunocompetent Patient, *J. Dermatology and Dermatitis*, 9(2); DOI:10.31579/2578-8949/114

**Copyright:** © 2024, José Eduardo Pérez Nieto. This is an open-access article distributed under the terms of The Creative Commons Attribution License, which permits unrestricted use, distribution, and reproduction in any medium, provided the original author and source are credited.

## Abstract

*M. abscessus var. abscessus* and *M. abscessus var. massiliense* are fast growing non-tuberculous mycobacteria that cause skin and soft tissue infections. We present a 32-year-old female that initiated her current condition two years ago prior her medical assessment due to an event of cellulitis in the front part of her legs and later on being in contact with contaminated water. Two weeks later after the exposure she developed a dermatosis in the same region characterized by disabling pain, intermittent fever and edema without achieving improvement after being treated with multiple topic treatments. For these reasons, extension studies were carried out to get to the diagnosis of infection related to *Mycobacterium abscessus var. massiliense*, this gave the opportunity to give a successful therapeutic approach. Finally, after being treated for a month, an adequate evolution was obtained.

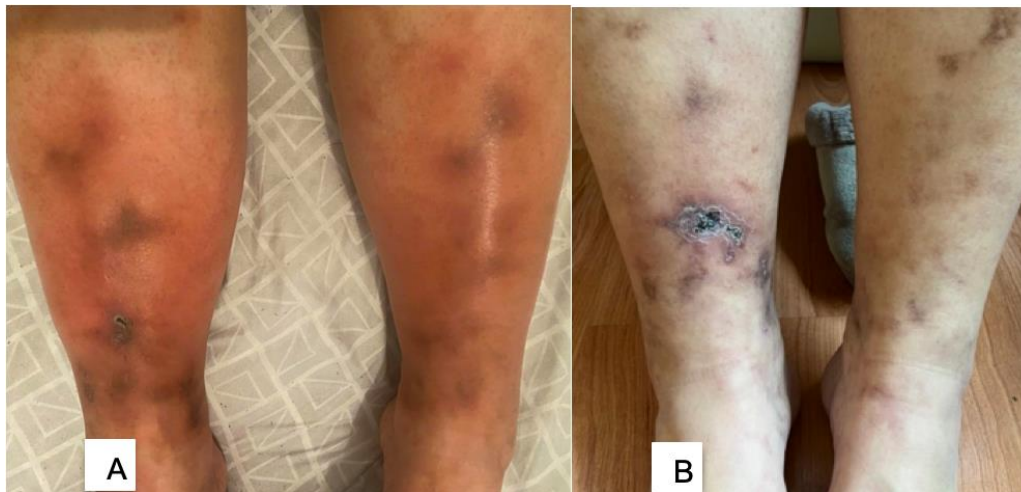
**Keywords:** mycobacterium abscessus; mycobacterium infections; massiliense, immunocompetent; soft tissue

## Introduction

Over time, there has been an increase in the number of cases of skin and soft tissue infections related to non-tuberculous mycobacteria. One of the most common of these kinds of mycobacteria that cause complicated infections is precisely *Mycobacterium abscessus*. There is a well-defined association to the existence of previous skin injury through trauma and precedent of any kind of aesthetics procedure that could have been compromised. This is why we consider it an emerging pathogen of medical and microbiological interest. So far we know that this mycobacteria has three varieties: *M. abscessus var. abscessus*, *M. abscessus var. bolletii* y *M. abscessus var. massiliense*. [1] The specific diagnosis of the variety, the difficulty of its determination in ok antimicrobial susceptibility profiles, together with the multiple resistance mechanisms [2] make it a pathogen that is difficult to diagnose and treat.

## Case Presentation

A 32-year-old woman without any other risk factor but overweight who asked for medical assistance. At physical examination she presented a located dermatosis on both legs, ankles, and dorsum of feet consisting of multiple, well-defined, erythematous plaques 1-3 cm in diameter (Figure 1A) with central ulcers covered by blood crust and multiple diffuse erythematous-violaceous macules approximately 1 cm in diameter. (Figure 1B) She referred this lesion had a chronic evolution associated with (incapacitating pain, intermittent fever and edema in both legs).



**Figure 1:** (A). Localized dermatosis on the lower extremities, legs, ankles, and dorsum of the feet consisting of multiple, well-limited, erythematous plaques 1-3 cm in diameter. (B). Central ulcer covered by blood crust and multiple diffuse erythematous-violaceous macules approximately 1 cm in diameter.

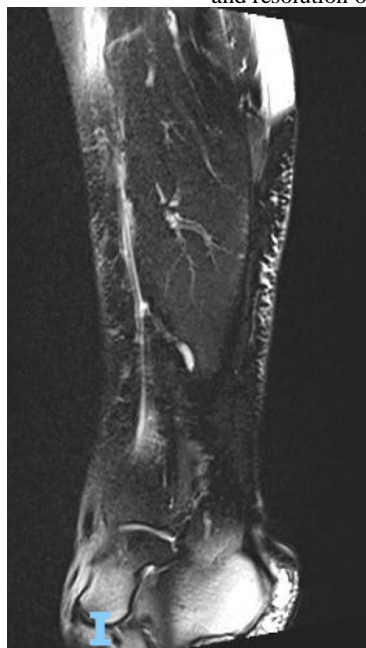
The patient initiated her current condition two years prior her medical assessment due to an event of cellulitis in the front part of her legs due to mosquito bites which settled after 5 days and later on approximately at day 7 were in contact with contaminated water (stagnant water). Two weeks later after the exposure she developed a dermatosis in the same region and she received multiple topic treatments that included antibiotics, antiseptics and anti-inflammatories without clinical improvement.

Initial assessment and laboratory studies were directed under the suspicion of an autoimmune cause, however these came back negative. An incisional biopsy was made and in the histopathological result reported cutaneous necrotizing neutrophilic vasculitis of small and medium vessels. Periodic acid Schiff, Ziehl-Neelsen and Fite Faraco stains did not show the presence of microorganisms. The analysis of the tissue did not show microorganisms with the usual stains (Gram, Ziehl Neelsen). Tissue culture was negative for bacteria and fungi.

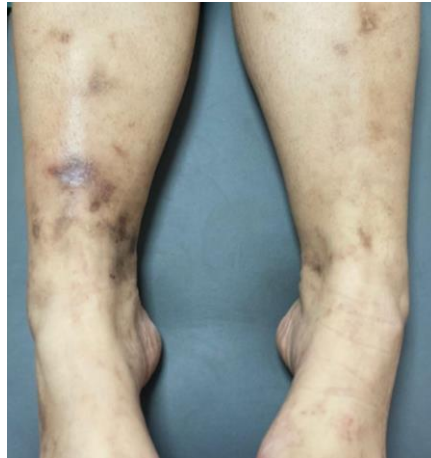Therefore in search of the infectious agent a PCR multiplex was made for the detection of *Mycobacterium* spp and molecular approach with 16S rRNA, amplifying a fragment of the 16S rRNA subunit gene (506 bp), mab3265c and mab3266c region (310 bp), for *M. abscessus* and mass3209 and mass3211 region for *M. mageritense* (1145 bp), considering positive the amplification for *M. abscessus* var. *mageritense*.

Intravenous treatment was prescribed for 21 days with amikacin (20mg/kg/day), linezolid (600mg bid), azithromycin (500mg qd) and imipenem 500mg (tid) with no evidence of adverse clinical or biochemical effects.

Magnetic resonance imaging is performed to demonstrate a collection of fluid itself that disappears on day 14 of treatment (Figure 2). With the good clinical and radiographic evolution, azithromycin 500mg qd, linezolid 600mg bid and minocycline 100mg bid were prescribed as outpatient treatment for one month, appreciating clinical improvement and resolution of lesions. (Figure 3)



**Figure 2:** Magnetic resonance. Soft tissue edema and collection of liquid with a laminar appearance in the infrapatellar region of the right leg.



**Figure 3:** Hyperchromic macules and residual post inflammatory scars.

### Discussion:

Skin and soft tissue infection by *Mycobacterium abscessus* can follow minor trauma, inadvertent inoculation, and cosmetic procedures. Being a potential pathogen that contaminates water sources and can be resistant to standard disinfectants. We believe that the risk factor for our patient was the exposure of previous skin lesions to stagnant contaminated water, since the presence of *M. abscessus* has been documented in municipal tap water in some places [3].

The clinical findings of *M. abscessus* infection in skin and soft tissues are signs and symptoms of local inflammation and manifest as papules [4], abscesses, sporotrichoid nodules and ulcers, painful erythematous violaceous plaques and cellulitis. It could be present as vasculitis that are histologically indistinguishable from autoimmune diseases [5], likewise skin infections by *M. abscessus* tend to be paucibacillary [6], so the clinical presentation, the risk factors and the microbiological and molecular study are the cornerstone in the accurate diagnosis of infections by this microorganism.

The importance of identifying the *Mycobacterium abscessus* subspecies lies in the choice of treatment, through genotype analysis and PCR sequencing. In this context, *M. massiliense* is unique in that it lacks the effective erm (41) gene due to deletions within gene [7], which confers less probability of resistance to macrolides, while *M. abscessus sensu stricto* contains a erm (41) complete gene [8], which will make *M. massiliense* more susceptible to antibiotics than *M. abscessus sensu stricto* and *M. bolletii*. [9]

There is no consensus on treatment for skin infections caused by non-tuberculous mycobacteria. Treatment is often prescribed based on the species isolated and its possible lower susceptibility pattern based on epidemiological studies of other cases.

Currently, only one case has been reported in Korea of a 34-year-old healthy patient with skin and soft tissue infection which was not caused by medical appliances, which was successfully treated using clarithromycin monotherapy [10]. Therefore, we think our case may be one of the few published cases that has been reported with this features.

### Conflict of interest

We have no conflict of interest.

### References

1. Mougari F, Guglielmetti L, Raskine L, Sermet-Gaudelus I, Veziris N, Cambau E. (2016), Infections caused by *Mycobacterium abscessus*: epidemiology, diagnostic tools and treatment. *Expert Rev Anti Infect Ther.* 2016 Dec; 14(12):1139-1154.
2. Luthra S, Rominski A, Sander P. (2018), The Role of Antibiotic-Target-Modifying and Antibiotic-Modifying Enzymes in *Mycobacterium abscessus* Drug Resistance. *Front Microbiol.* 2018 Sep 12; 9:2179.
3. Thomson R, Tolson C, Sidjabat H, Huygens F, Hargreaves M. (2013), *Mycobacterium abscessus* isolated from municipal water - a potential source of human infection. *BMC Infect Dis.* 2013 May 25; 13:241.
4. Mora AD, Giraldo S, Castillo DA, Ferro BE. (2021), Comportamiento clínico de la infección y enfermedad causada por micobacterias no tuberculosas en Latinoamérica: Revisión de alcance [Clinical behavior of infection and disease caused by non-tuberculous mycobacteria in Latin America: Scoping review]. *Rev Peru Med Exp Salud Publica.* 2021 Apr-Jun;38(2):318-325. Spanish.
5. Gordon MM, Wilson HE, Duthie FR, Jones B, Field M. (2002), When typical is atypical: mycobacterial infection mimicking cutaneous vasculitis. *Rheumatology (Oxford).* 2002 Jun;41(6):685-690.
6. Li JJ, Beresford R, Fyfe J, Henderson C. (2017), Clinical and histopathological features of cutaneous nontuberculous mycobacterial infection: a review of 13 cases. *J Cutan Pathol.* 2017 May;44(5):433-443.
7. Summers NA, Kempker R, Palacio F. (2018), *Mycobacterium abscessus* subspecies massiliense infection after skin graft and cholecystectomy in a burn patient. *Int J Infect Dis.* 2018 Nov; 76:29-31.
8. Nessar R, Cambau E, Reyrat JM, Murray A, Gicquel B. (2012), *Mycobacterium abscessus*: a new antibiotic nightmare. *J Antimicrob Chemother.* 2012 Apr;67(4):810-818.
9. Koh WJ, Jeon K, Lee NY, Kim BJ, Kook YH, Lee SH, Park YK, Kim CK, Shin SJ, Huitt GA, Daley CL, Kwon OJ. (2011), Clinical significance of differentiation of *Mycobacterium massiliense* from *Mycobacterium abscessus*. *Am J Respir Crit Care Med.* 2011 Feb 1; 183(3):405-410.
10. Kwon YH, Lee GY, Kim WS, Kim KJ. (2009), A Case of Skin and Soft Tissue Infection Caused by *Mycobacterium abscessus*. *Ann Dermatol.* 2009 Feb;21(1):84-87.



This work is licensed under Creative Commons Attribution 4.0 License

To Submit Your Article Click Here:

**Submit Manuscript**

DOI:10.31579/2578-8949/114

**Ready to submit your research? Choose Auctores and benefit from:**

- fast, convenient online submission
- rigorous peer review by experienced research in your field
- rapid publication on acceptance
- authors retain copyrights
- unique DOI for all articles
- immediate, unrestricted online access

At Auctores, research is always in progress.

Learn more <https://auctoresonline.org/journals/dermatology-and-dermatitis>