

“Life Hack” for Stem Revision in Total Hip Arthroplasty with Metal on Metal. Case Report

A.V. Tsybin *, V.V. Lubchak, and R.V. Malygin

Vreden National Medical Research Center of Traumatology and Orthopaedics, Ministry of Health of Russian Federation, St. Petersburg, Russia.

Corresponding Author: Tsybin Aleksandr Vladimirovich, Vreden National Medical Research Center of Traumatology and Orthopedics, Academica Baykova Str., 8, 195427, St. Petersburg, Russia; Alex_Tsybin@mail.ru, +79112205890.

Received date: January 06, 2024; **Accepted date:** January 16, 2024; **Published date:** January 26, 2024

Citation: A.V. Tsybin, V.V. Lubchak, and R.V. Malygin. (2024), Sport, Medicine and Health: The Biggest Public Health Problem of the 21st Century, *J Clinical Orthopaedics and Trauma Care*, 6(1); DOI: [10.31579/2694-0248/079](https://doi.org/10.31579/2694-0248/079)

Copyright: © 2024, Tsybin Aleksandr Vladimirovich. This is an open access article distributed under the Creative Commons Attribution License, which permits unrestricted use, distribution, and reproduction in any medium, provided the original work is properly cited.

Abstract

Revision hip arthroplasty often involves significant intraoperative difficulties due to approach, debridement, removal of unstable components, bone cement, and implantation of new ones in conditions of bone loss. One of the main factors influencing the choice of surgical tactics is the experience of the surgeon and the options that he is able to implement according to his skills. For example, a simple revision due to wear of a polyethylene liner can result in the implantation of complex revision systems, massive blood loss and a long duration of the operation, and vice versa. In the publication, the authors describe an original solution in hip revision due to stem instability with metal-to-metal, which may be useful for surgeons who perform such operations.

Keywords: revision arthroplasty; instability of the stem; metal on metal; ASPID; hip arthroplasty; post-traumatic deformity of the acetabulum

Introduction

Revision hip arthroplasty is a complex surgical procedure that requires the surgeon to have careful preoperative planning, manual skills, and a wide range of hardware, including special revision components of prostheses. Modern technologies in orthopedics expand the capabilities of surgeons, providing highly accurate diagnostics, visualization and, if necessary, the production of custom-made implants.

The debut of modern hip endoprosthetics was described in 1961 by Sir J. Chanley [1]. Since then, materials for the manufacture of endoprostheses and friction pairs have been improved. One of the stages in the evolution of hip arthroplasty was the introduction of a metal-on-metal bearings in combination with a large diameter of the head. The peak use of endoprostheses with metal on metal occurred in 2006, when in the United States alone, approximately 35% of implanted prostheses were metal on metal, and among patients under 55 years this figure sometimes reached 45% [2].

However, an analysis of the results of using metal on metal revealed serious specific complication - pseudotumor, which develops as a result of an acute reaction of soft tissues to metal wear particles (primarily cobalt and chromium ions) [3]. Information on the frequency of this complication varies greatly among different authors. So, M.H. Hjorth et al. note the development

of complications in 19.5% of cases [4], while S. Konan et al. 32% of complications are recorded [5].

In addition to local destruction of soft tissue and bone, pseudotumor also has systemic manifestations - an increase in metal ions in the blood, which ultimately can have a general toxic effect on the patient's body and a teratogenic effect on the fetus during pregnancy. Considering the formation of pseudotumors with a metal on metal, an article was published in the *Lancet* in 2012 [6], in which the European Orthopedic Society recommended abandoning the use of this bearing. However, as research results show, pseudotumor does not form in all patients. Literature data indicate in some cases good long-term results [7].

Thus, there remains a large number of patients in the world with metal-on-metal total hip endoprostheses, who currently or in the future require hip revision surgery.

The specifics of complications of metal on metal influence the choice of surgical tactics during hip revision surgery and require an individual approach to get the best result. Bone loss and the reliability of primary fixation of revision components are the main aspects when carrying out preoperative planning and performing revision surgery.

This publication is devoted to a case of revision arthroplasty of metal on metal which was performed in our clinic.

Case Report:

Patient K., 49 years old, male, was admitted to the clinic of our center due to instability of the stem of the left hip joint endoprosthesis for revision. Upon admission, the patient complained of pain in the left thigh when walking. History of fracture of the acetabulum as a result of an accident. Conservative treatment was performed.

According to the computed tomography data provided by the patient before endoprosthetics, post-traumatic deformation of the walls of the acetabulum was revealed - displacement of the posterior wall by 9 mm, the medial wall by 4 mm, the upper wall by 11 mm, the integrity of the pelvic ring was not compromised (Figure 1).

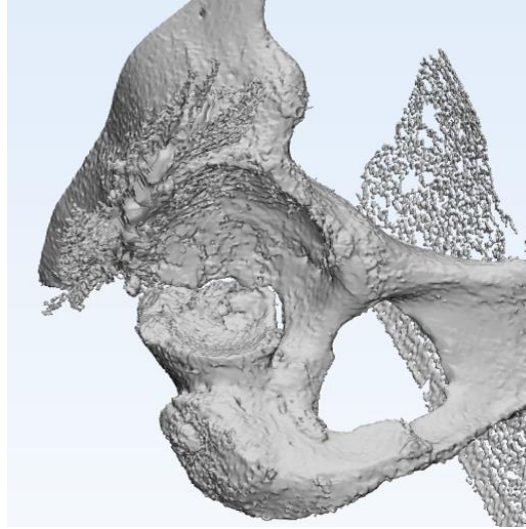


Figure 1: Three-dimensional model of the acetabulum of patient K. before primary arthroplasty.

According to the ASPID classification, the patient's formula is presented as follows: A0S1P1I0D0 [8, 9].

Two years after the injury total hip arthroplasty was performed using a metal-on-metal friction pair (Duron, Avenir, Zimmer (Figure 2).

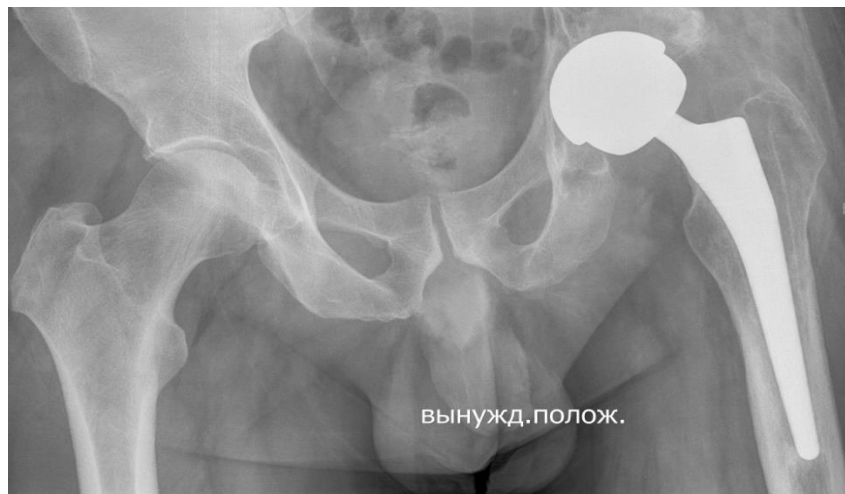

Figure 2: Plain radiograph of the pelvis before surgery.

Local status on admission: lameness on the left leg, walking with additional support on a cane. Range of motion in the left hip joint: flexion 90 degrees, extension 180 degrees, external rotation 10 degrees, internal rotation 5 degrees, abduction 10 degrees, adduction 5 degrees. Trendelenburg's sign is positive. Pain with axial loads on the left lower limb. There is a postoperative scar without any features along the anterolateral surface of the left hip joint.

The patient underwent stem revision arthroplasty. Using a revision set of instruments, the femoral component of the endoprosthesis and the large-diameter metal head were removed. Upon examination, there were no obvious signs of wear in the bearing, the acetabular component was not deformed and stable. No visible damage to the head cone was detected.

A femoral revision component Wagner SL revision stem 16/225 was installed (Figure 3). The metal head was resterilized and installed.

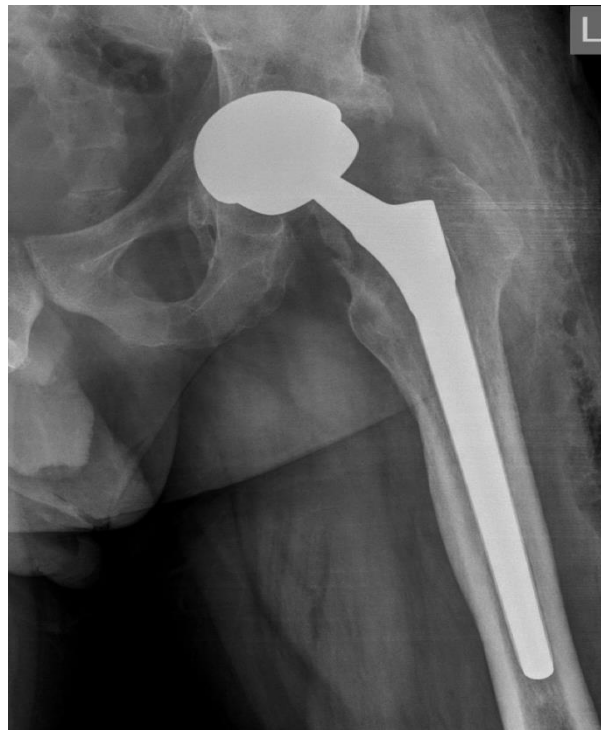

Figure 3: Postoperative radiograph of the left hip.

The presented surgical tactics reduced the operation time, blood loss and bone loss, but requires observation.

Discussion

In the publication, we proposed an original solution that made it possible to perform revision arthroplasty for instability of the stem of a metal-on-metal hip endoprosthesis with minimal bone loss, blood loss and operation time, which ultimately was a predisposing factor for obtaining a good long-term result. Considering the presence of a metal on metal, an alternative solution in this case is a total replacement of the endoprosthesis, however, taking into account the post-traumatic deformation of the acetabulum before primary total hip replacement, deformation and defects of the acetabular walls, when removing a well-fixed acetabular component in this case, an extensive defect is obtained, requiring implantation of special revision systems (type 3B acetabular defect according to the W. Paprosky classification). Moreover, removal of the acetabular component in this patient could lead to pelvic discontinuity, which could require custom made implant, which significantly increases the cost of treatment.

Conclusion

Of course, analysis of the results of revision arthroplasty in patients with metal-on-metal bearings is necessary to develop an algorithm for choosing tactics, the ultimate goal of which is to improve the results of hip arthroplasty.

References

1. Charnley J. Arthroplasty of the hip: a new operation. *Lancet*. Volume 1, 1961. Pages 1129–1132.
2. Bozic K.J., Kurtz S., Lau E. et al. The epidemiology of bearing surface usage in total hip arthroplasty in the United States. *J. Bone Joint Surg. Am.* Volume 91, Issue 7, 2009. Pages 1614-1620.
3. Langton D.J., Jameson S.S., Joyce T.J. et al. Early failure of metal-on-metal bearings in hip resurfacing and large-diameter total hip replacement: A consequence of excess wear. *J. Bone Joint Surg. Br.* Volume 92, 2010. Pages 38-46.
4. Hjorth M.H., Stilling M., Soballe K. et al. No association between pseudotumors, high serum metal-ion levels and metal hypersensitivity in large-head metal-on-metal total hip arthroplasty at 5–7-year follow-up. *Skeletal Radiology*. Volume 45, Issue 1, 2016. Pages 115–125.
5. Konan S., Duncan C.P., Masri B.S., Garbuz D.S. What is the natural history of asymptomatic pseudotumors in metal-on-metal THAs at mid-term followup? *Clin. Orthop. Relat. Res.* Volume 475, Issue 2, 2017. Pages 433-441.
6. Smith A.J., Dieppe P., Howard P.W., Blom A.W. National Joint Registry for England and Wales. Failure rates of metal-on-metal hip resurfacings: Analysis of data from the National Joint Registry for England and Wales. *Lancet*. 2012a; 380(9855): 1759–1766.
7. Lyubchak V.V., Sivkov V.S., Tsybin A.V., Denisov A.O., Malygin R.V., Shubnyakov M.I. Medium-term and long-term results of hip endoprosthetics using a metal-on-metal friction pair. *Surgery. Journal named after N.I. Pirogov*. Volume 10, 2019. Pages 55-61.
8. Tsybin A. V., Lyubchak V.V. ASPID classification of post-Traumatic Acetabular Deformities in Primary total hip Arthroplasty. *J. Clinical Orthopedics and Trauma Care*. Volume 4, Issue 3, 2021.
9. Tsybin A.V., Lyubchak V.V., Sivkov V.S., Shilnikov V.A., Malygin R.V., Shubnyakov M.I. Rationale for the use of the original classification of post-traumatic deformities of the acetabulum during primary hip replacement. *Genius of orthopedics*. Volume 5, Issue 27, 2021. Pages 508-513.



This work is licensed under Creative Commons Attribution 4.0 License

To Submit Your Article Click Here:

Submit Manuscript

DOI:[10.31579/2694-0248/079](https://doi.org/10.31579/2694-0248/079)

Ready to submit your research? Choose Auctores and benefit from:

- fast, convenient online submission
- rigorous peer review by experienced research in your field
- rapid publication on acceptance
- authors retain copyrights
- unique DOI for all articles
- immediate, unrestricted online access

At Auctores, research is always in progress.

Learn more at: <https://www.auctoresonline.org/journals/clinical-orthopaedics-and-trauma-care->