

# Congenital Tessier Type 7 Bilateral Maxillary Duplication: A Rare Craniofacial Deformity

**Arvinder Singh\***

Associate Professor in department at Government Medical College, Amritsar, Punjab Government Medical College.

**\*Corresponding Author:** Arvinder Singh, Associate Professor in department at Government Medical College, Amritsar.**Received date:** January 02, 2023; **Accepted date:** January 08, 2023; **Published date:** January 15, 2023**Citation:** Arvinder Singh, (2024), Congenital Tessier Type 7 Bilateral Maxillary Duplication: A Rare Craniofacial Deformity, *J Clinical Research and Reports*, 15(1); DOI:10.31579/2690-1919/350**Copyright:** © 2023, Arvinder Singh. This is an open access article distributed under the Creative Commons Attribution License, which permits unrestricted use, distribution, and reproduction in any medium, provided the original work is properly cited.

## Abstract

It is uncommon for these rare congenital abnormalities to manifest as craniofacial clefts. The Tessier clefting scheme is one classification technique that is used for diagnosis. A maxillary duplication is an extra bone that is situated behind the maxillary tuberosity. The case of a six-year-old child with bilaterally supernumerary teeth who presented to the Department of Radiodiagnosis of our institute to assess and treat enlarged asymptomatic cheek swelling is presented. On the basis of the patient's medical history, physical examination, and radiological tests, the accessory maxillae were diagnosed. Later, there was a surgical reconstruction.

**Keywords:** tessier clefting system; maxilla; radiograph; computed tomography

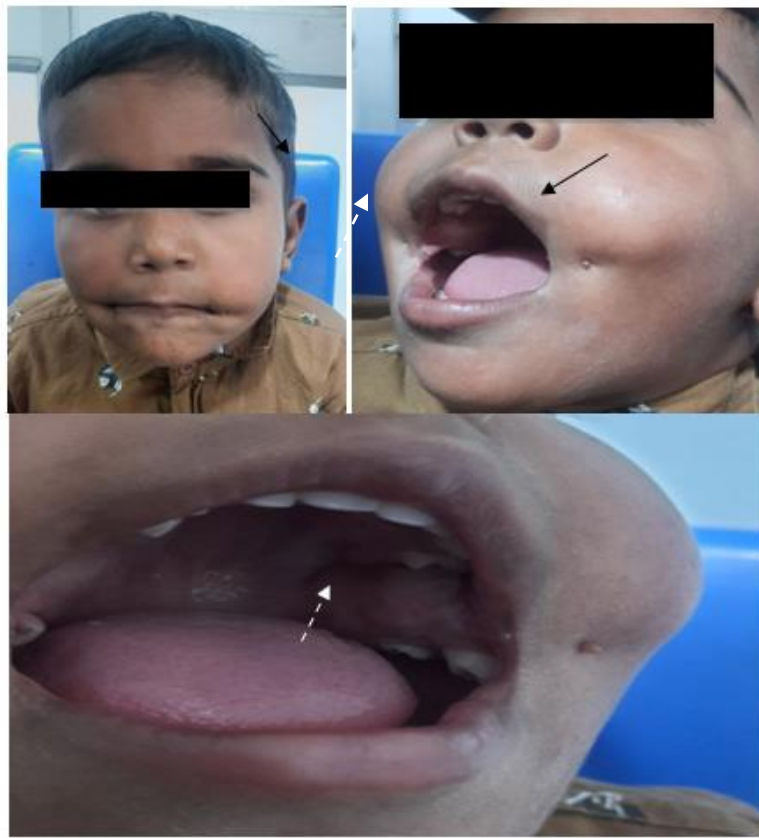## Introduction

The presentation of craniofacial clefts is unusual for these rare congenital malformations. The exact cause of craniofacial clefts is unknown; however, it is thought to be a combination of environmental (eg, radiation, medication, illness) and genetic predisposition.<sup>1</sup> According to estimates, the incidence ranges from 1.4 to 4.9 per 100,000 live births. One classifying method that is used is the Tessier cleft scheme. Various cleft locations are numbered (1–30) in this classification based on their anatomical connection to the sagittal midline.<sup>2</sup> Type 0 craniofacial clefts are the most common type, while Tessier nos. 8, 13, and 30 are the least common. Tessier, no. 7 is associated with maxilla and zygomatic bone anomalies, fascial muscular diastasis, and macrostomia.<sup>3</sup> The specific pathogenic factors leading to these clefts remains unidentified; they could result from an unsuccessful attempt to fuse the embryonic mandibular and maxillary processes in the first pharyngeal arch.<sup>4</sup> Clefts in Tessier, No. 7 may be linked to further abnormalities such as an auxiliary maxilla or mandible. A rare clinical phenomenon known as the "accessory maxilla" or the "maxillary duplication" is defined by additional bone posterior to the maxillary tuberosity.<sup>5</sup> The accessory maxilla is frequently linked to

facial clefts, especially Tessier, no. 7 clefts, and is most likely the result of aberrant zygomatic arch growth. Here, we report on a 4-year-old boy with bilateral Tessier, no. 7 clefts and bilateral accessory maxilla.<sup>6</sup>

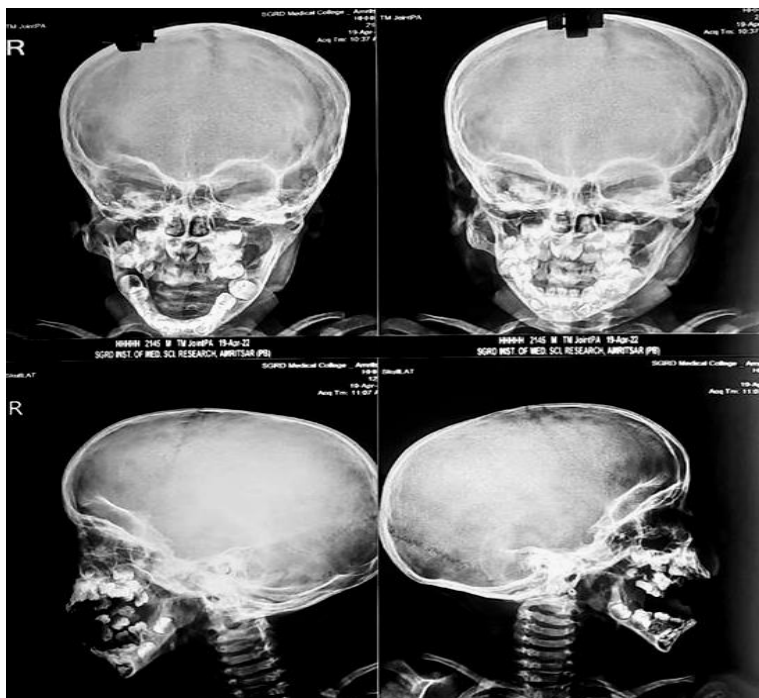
## Materials and Method:

A four-year-old child arrived at our institute's Department of Radiodiagnosis to assess and treat enlarged, asymptomatic cheek tumors accompanied by bilateral supernumerary teeth. The youngster did not regularly take any vitamins or drugs. There were no genetic diseases or facial defects in the family. An extraoral examination did not show any enlarged salivary glands or regional lymphadenopathy. The left zygomatic bone of the patient was more noticeable than the right zygomatic bone. The patient's mouth opened somewhat narrowly. (Figure 1a-c) There were no visible anomalies in the middle or external ears. The bilateral posterior maxilla showed bone outgrowths with additional teeth on intraoral inspection. No alveolar cleft was seen during the current examination. The other oral structures were in average condition.



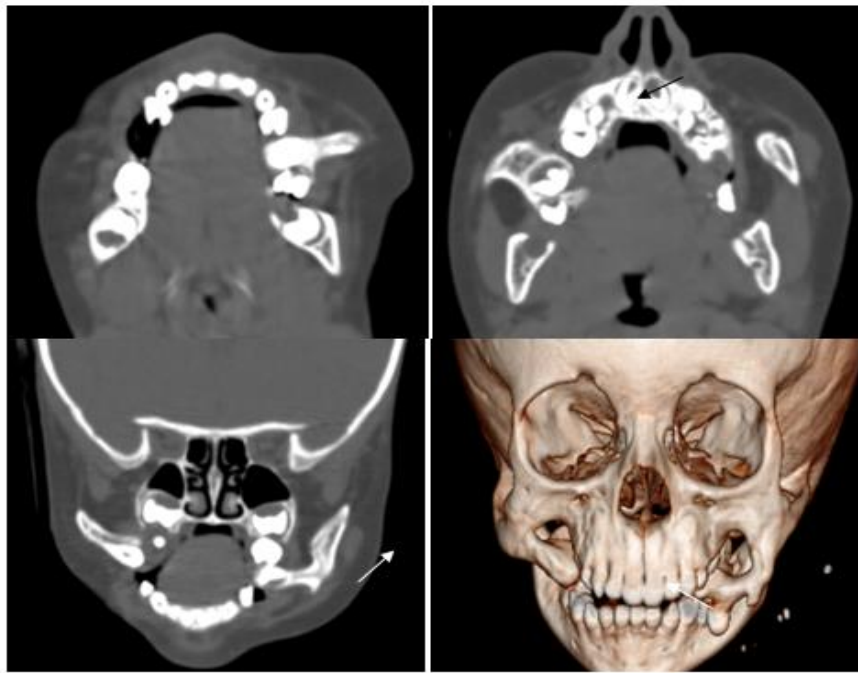
**Figure (1a-c):** Photograph of the child showing protuberances in to both cheek regions since birth, left more than right (black arrows). An open-mouth view shows supernumerary teeth in relation to the maxilla (dotted arrow).

An AP and lateral view of the X-ray face revealed two bony maxillary outgrowths on either side [Figure 2a-d].



**Figure (2a-d):** X-Ray facial bones PA & lateral views, shows bilateral bony outgrowths arising from the maxilla(white arrows).Note is also made of maxillary supernumrery teeth (dotted arrow).

Together with a 3D reconstruction, a CT scan of the face revealed significant bone outgrowths from both maxillary regions, particularly on the left side, with more teeth than needed [Figs.3a-d].



**Figure (3a-d):** NCCT face along with 3D volume rendering shows bilateral maxillary bony outgrowths (arrows) left more than right with overlying soft tissue swellings. Superumerary teeth are also noted in relation to the maxilla (black arrows).

An accessory maxilla was diagnosed on the basis of the patient's medical history, physical examination, and radiological investigation. Subsequently, surgical reconstruction was carried out.

## Discussion

Prenatal screenings should include examinations of fetal craniofacial structures, since abnormalities involving these tissues can indicate chromosomal abnormalities, infectious diseases, metabolic disorders, or syndromes. Six prenatal ultrasound testing methods that are accurate, consistent, and noninvasive can be used to detect craniofacial defects. Therefore, current worldwide standards recommend routine mid-trimester ultrasound scans to assess the entire fetal face.<sup>7</sup>

This report details a child with bilateral Tessier, no. 7 clefts and bilateral accessory maxilla who came in for treatment. Tessier, no. 7 clefts are unknown in origin; failure of mesodermal migration, amniotic membrane syndrome, or failed maxillary fusion of the first branchial arch are among the potential reasons. Soft and hard tissue anomalies exist in patients with Tessier, no. 7 abnormalities.<sup>8</sup>

Complex tissue abnormalities include deformation of the maxillary tuberosity and pterygoid process, as well as deformation of the cranial base, glenoid fossa, sphenoid, condyle, coronoid process, mandibular ramus, posterior maxilla, alveolar process, and maxillary cleft in the molar region. Macrostomia, anomalies related to the temporalis, external and middle ears, and cranial nerves occasionally, as well as anomalies of the parotid gland and cranial nerves 5 and 7 are characteristics of soft tissue abnormalities.

The most common clinical manifestation of Tessier, no. Seven clefts, affecting 66.7% of the patients, were bilateral facial clefts. Dandy-Walker

syndrome, Amniotic band syndrome, Goldenhar syndrome, brain malformations of the posterior fossa, arterial lesions, cardiac abnormalities, and ocular abnormalities syndrome (PHACE) were among the five syndromes that at least one of the individuals had. Five patients

were present: two had unilateral accessory maxillae, three had bilateral accessory maxillae, and one had a right accessory mandible. Seven patients had alveolar clefts and mandibular dysplasia, while five had jaw

duplication. Each patient was described in case reports. After obtaining a prenatal diagnosis, most people underwent reconstructive surgery.

Duplication of the jaws with additional teeth in the maxilla or mandible can occur as an accessory protrusion or throughout the jaw.<sup>4</sup> Jaw duplication is expected to affect 1 in 80,000 births in the general population. However, its incidence is unclear. Boys are more likely to be affected than girls, and the maxilla is more likely to be affected than the mandible.<sup>9</sup> Although unilateral involvement was reported in most published publications, less than 20% of the patients had bilateral involvement. Other cranial clefts, such as the cleft lip or palate, often coincide with maxillary duplication, a rare congenital illness.<sup>10</sup> To the best of our knowledge, there are not many occurrences of maxillary duplication documented in the literature.<sup>11</sup>

Because jaw duplication can affect the development of the craniomaxillofacial region (including tooth eruption and facial growth), early detection is essential.<sup>12</sup> We recommend routine patient follow-up and rapid referral to tertiary facilities to rule out additional craniofacial disorders and abnormalities.

## Conclusion:

The most common clinical manifestation of Tessier, no. 7 clefts in people are bilateral facial clefts. It is more common for men to have them. Only 24 occurrences have been reported in the literature, making it unusual for a patient to have additional teeth in an auxiliary maxilla. This article focuses on the importance of early detection of craniofacial abnormalities for a patient's prognosis and course of treatment.

## References:

1. Kalantar-Hormozi, A, Abbaszadeh-Kasbi, A, Goravanchi, F, et al. (2017) Prevalence of rare craniofacial clefts. *J CraniofacSurg* 28: e467–e470.
2. Fearon, JA. (2008) Rare craniofacial clefts: a surgical classification. *J CraniofacSurg* 19: 110–112.
3. Woods, RH, Varma, S, David, DJ. (2008) Tessier, no. 7 cleft: a new subclassification and management protocol. *PlastReconstrSurg* 122: 898–905.

4. Chauhan, DS, Guruprasad, Y. (2015) Bilateral Tessier's 7 cleft with maxillary duplication. *J Maxillofac Oral Surg* 14: 108–112.
5. Borzabadi-Farahani, A, Yen, SL, Yamashita, DD, et al. (2012) Bilateral maxillary duplication: case report and literature review. *Oral Surg Oral Med Oral Pathol Oral Radiol* 113: e29–e32.
6. Mak, ASL, Leung, KY. (2019) Prenatal ultrasonography of craniofacial abnormalities. *Ultrasonography (Seoul, Korea)* 38: 13–24.
7. Salomon, LJ, Alfirevic, Z, Berghella, V, et al. (2008) Practice guidelines for performance of the routine mid-trimester fetal ultrasound scan. *Ultrasound ObstetGynecol* 2011; 37: 116–126. Fearon, JA. Rare craniofacial clefts: a surgical classification. *J CraniofacSurg* 19: 110–12.
8. Woods, RH, Varma, S, David, DJ. (2008) Tessier, no. 7 cleft: a new subclassification and management protocol. *PlastReconstrSurg* 122: 898–905.
9. Chauhan, DS, Guruprasad, Y. Bilateral Tessier's 7 cleft with maxillary duplication. *J Maxillofac Oral Surg* 2015; 14: 108–112.
10. Borzabadi-Farahani, A, Yen, SL, Yamashita, DD, et al. (2012) Bilateral maxillary duplication: case report and literature review. *Oral Surg Oral Med Oral Pathol Oral Radiol* 113: e29–e32.
11. Mak, ASL, Leung, KY. (2019) Prenatal ultrasonography of craniofacial abnormalities. *Ultrasonography (Seoul, Korea)* 38: 13–24.
12. Salomon, LJ, Alfirevic, Z, Berghella, V, et al. (2011) Practice guidelines for performance of the routine mid-trimester fetal ultrasound scan. *Ultrasound Obstet Gynecol* 37: 116–126.



This work is licensed under Creative Commons Attribution 4.0 License

To Submit Your Article Click Here: [Submit Manuscript](#)

DOI:10.31579/2690-1919/350

**Ready to submit your research? Choose Auctores and benefit from:**

- fast, convenient online submission
- rigorous peer review by experienced research in your field
- rapid publication on acceptance
- authors retain copyrights
- unique DOI for all articles
- immediate, unrestricted online access

At Auctores, research is always in progress.

Learn more <https://www.auctoresonline.org/journals/journal-of-clinical-research-and-reports>