

# Cutaneous Mastocytosis: A Rare Disease of the Immune System

Gladys Castillo S<sup>1\*</sup>, María Victoria Santofimio<sup>2</sup>, Yadira Aguilar B<sup>3</sup>, Jessica Sandoval R<sup>1</sup>, Carla Verdugo M<sup>1</sup>, Francisco Mejia S<sup>4</sup>

<sup>1</sup> Postgraduate Dermatology Physician – UTE – Ecuador.

<sup>2</sup> Dermatology Attending Physician, Service Leader. Eugenio Espejo Specialty Hospital-HEEE – Ecuador.

<sup>3</sup> Treating Physician of Dermatology – HEEE – Ecuador.

<sup>4</sup> Rural Doctor of the Health Subcenter of Huaca – Ecuador.

**\*Corresponding Author:** Gladys Castillo Soto, Postgraduate Dermatology Physician – UTE – Ecuador.

**Received date:** December 15, 2023; **Accepted date:** December 27, 2023; **Published date:** January 17, 2024

**Citation:** Gladys Castillo S, María Victoria Santofimio, Yadira Aguilar B, Jessica Sandoval R, Carla Verdugo M, Francisco Mejia S, (2024), Cutaneous Mastocytosis: A Rare Disease of the Immune System, *Dermatology and Dermatitis*, 9(1); DOI:10.31579/2578-8949/137

**Copyright:** © 2024, Gladys Castillo Soto. This is an open-access article distributed under the terms of The Creative Commons Attribution License, which permits unrestricted use, distribution, and reproduction in any medium, provided the original author and source are credited.

## Abstract

Mastocytosis, a chronic disease of unknown etiology, presents with a variety of symptoms, including redness, itching, blistering, bloating, abdominal pain, bone pain, fatigue, dizziness, and fainting. Diagnosis is based on the presence of an abnormally high number of mast cells in the skin or other tissues of the body. Treatment depends on the severity of your symptoms and the extent of the disease. In most cases, it's about controlling symptoms and avoiding triggers for mast cell reactions.

**Keywords:** matocytes; chronic disease; mast cells

## Introduction

Mastocytosis is a chronic disease, which can be caused by mutations in the KIT gene, which codes for a protein called receptor tyrosine kinase (RTK) found on the surface of mast cells. Mutations in the KIT gene can cause mast cells to produce too many mast cells, leading to mastocytosis. In addition, other risk factors have been identified, such as exposure to certain chemicals, radiation, and other diseases of the immune system [1,2,3,4].

Mastocytosis is classified into two main types: cutaneous mastocytosis and systemic mastocytosis. Cutaneous mastocytosis is limited to the skin, while systemic mastocytosis can affect multiple organs and systems, which can be life-threatening. Most patients with cutaneous mastocytosis have a good outlook, while patients with systemic mastocytosis may have a reduced life expectancy. [2,5,6].

The diagnosis is made through clinical evaluation, however, the symptoms are similar to other disorders such as: chronic urticaria, Carcinoid syndrome, gastrinoma etc., so a skin biopsy is required [2].

Treatment for mastocytosis may include antihistamines, corticosteroids, medications to reduce mast cell production, and in severe cases, chemotherapy. In addition, patients with mastocytosis should avoid known triggers of mast cell reactions, such as certain foods, medications, and environmental factors [7,2,8].

## Clinical case:

A 39-year-old female patient, incomplete secondary school, resident of Quito.

APP: no refiere

APF: mother with renal impairment

AGO: G3, P0, C3, A0

Patient reports that 12 years ago, apparently after a blood transfusion, hyperpigmented spots appeared on the neck that caused itching, which persisted over time, without receiving treatment, later becoming asymptomatic. A week ago, he began to have edema of the lower limbs, a burning sensation and pain of the limbs with difficulty in walking.

## Physical exam:

Dermatosis located in the neck and anterior thorax and abdomen characterized by light brown hyperpigmented macules, with regular borders in large numbers disseminated. And few macules of the same characteristics on the upper extremities (Figures. 1 and 2).

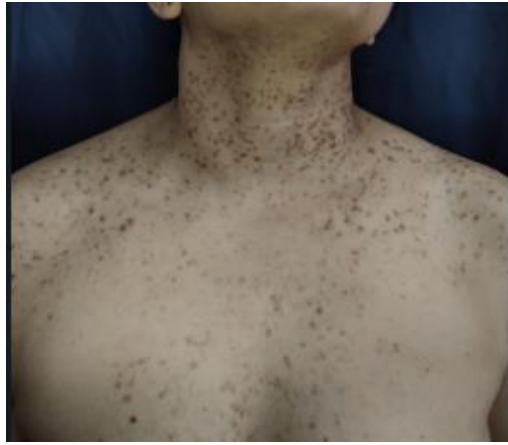

Figure: 1

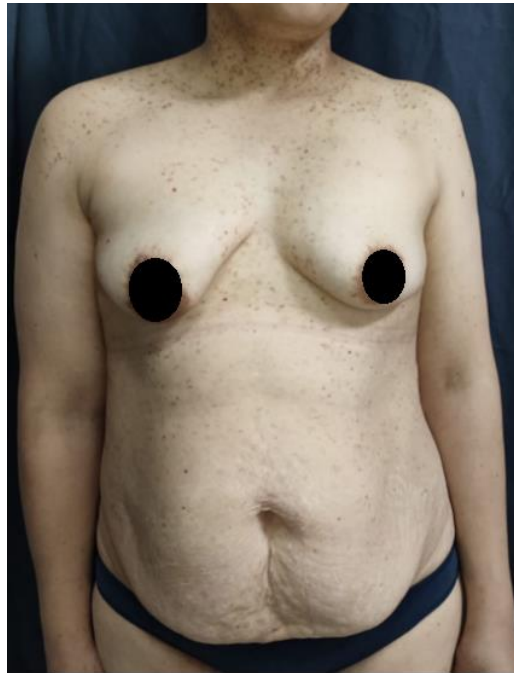


Figure 2

Presence of erythematoviolaceous lesions plus edema (Figure. 3).

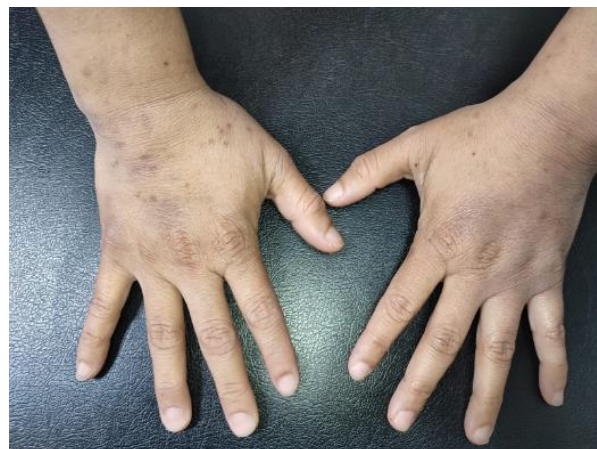

Figure 3

In the lower extremities: oedema leaving fovea ++/+++, plus pain on palpation on the soles of the feet (Figure. 4).

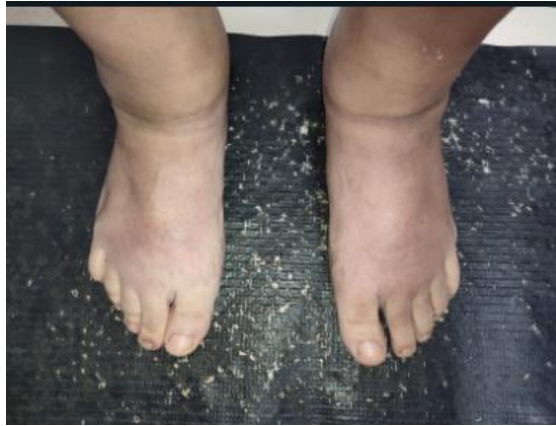

Figure 4

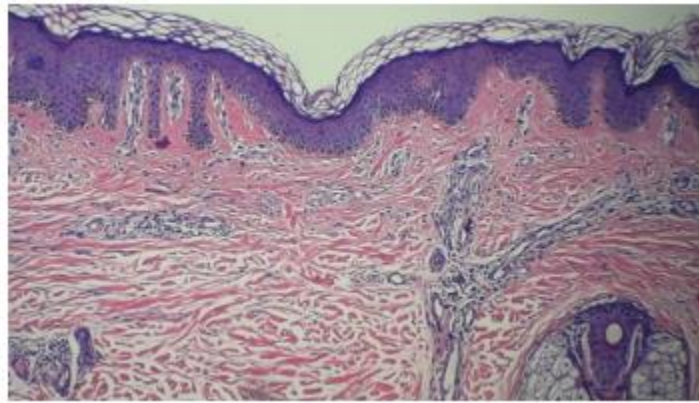


Figure 5

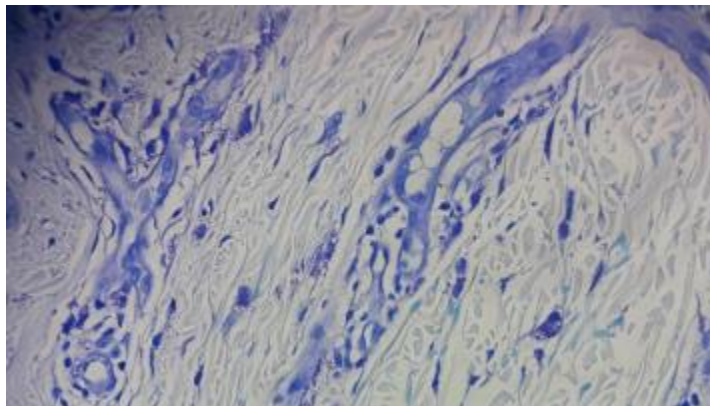


Figure 6

Lesions were scheduled for biopsy, which were obtained from erythematoviolaceous lesions on the back of the right hand and light brown macula on the ventral aspect of the right forearm.

Laboratory tests showed severe hypochromic microcytic anemia (HB: 7.80g/dl, HTO: 28.90%, transferrin saturation 3.27%), leukopenia and eosinophilia.

**Histopathology:** Skin with thin epidermis, dermis with scarce perivascular lymphocyte infiltrate, accompanied by isolated polygonal cells with broad granular cytoplasm that are metachromatically stained with toluidine blue and reactive ectatic capillaries.

**Histochemistry:** Toluidine blue: The presence of mast cells is recognized.

**Diagnosis:** Compatible With Cutaneous Mastocytosis

### Discussion:

Mastocytosis is a rare disease characterized by the abnormal accumulation of mast cells in various tissues of the body. These mast cells are cells of the immune system that release chemicals in response to external or internal stimuli, such as allergens or infections. When mast cells accumulate excessively, they can cause a variety of symptoms,

ranging from rashes and itching to gastrointestinal issues and anaphylaxis [9].

Most of the time, mastocytosis is a benign disease that mainly affects the skin. However, in rare cases, it can affect other organs, including the liver, spleen, lymph nodes, gastrointestinal system, and central nervous system [8].

Although mastocytosis can affect people of all ages, it is most common in children and young adults. It is often diagnosed after years of vague, recurring symptoms, which can delay treatment and worsen the patient's quality of life [2].

### Conclusion:

In conclusion, mastocytosis is a rare, rare but significant disease that can have a significant impact on the quality of life of those who suffer from it. Excessive accumulation of mast cells in various tissues of the body can cause a wide variety of symptoms, ranging from rashes and itching to gastrointestinal problems and anaphylaxis.

While diagnosing mastocytosis can be difficult due to the nature of the symptoms, it is important to seek medical attention if the disease is suspected. Treatment may include measures to control symptoms, such as antihistamines and corticosteroids, as well as therapies aimed at reducing mast cell accumulation.

While there is still much to learn about mastocytosis, current research is helping to improve our understanding of the disease and develop new treatments that can improve patients' quality of life. With early diagnosis and proper treatment, many patients can lead full and active lives despite mastocytosis.

### Conflict of interest:

The authors declare that they have no conflicts of interest.

### References

1. Acevedo MJ. (2016). SYSTEMIC MASTOCYTOSIS AND KIT MUTATION: FREQUENCY, DEGREE OF HEMATOPOIESIS INVOLVEMENT, AND CLINICAL AND BIOLOGICAL BEHAVIOR OF THE DISEASE.
2. James F. (2022). Mastocytosis and Mast Cell Activation Syndrome. MSD Manual.
3. Maldonado Guadalupe CBGM. (2015). Cutaneous Mastocytosis: What the Pediatrician Needs to Know. Allergy, asthma, pediatric immunology, 24(3).
4. Brockow K JCBHRJ. (2008). Anaphylaxis in patients with mastocytosis: a study on history, clinical features and risk factors in 120 patients. Allergy, 2.
5. Escribano L ACCMea. (2002). Mastocytosis: current concepts in diagnosis and treatment. Ann Hematol, 12.
6. M C. (2006). MAST cell mediators in allergic inflammation and mastocytosis. Immunol Allergy Clin North Am, 3.
7. Mordeling GJ HBBSHJMDFea. (2016). Pharmacological treatment options for mast cell activation disease. Naunyn Schimiedebergs Arch Pharmacol, 7.
8. Scribe L ATMASLHA. (2022). POTENTIALLY TRIGGERING FACTORS FOR THE RELEASE OF MAST CELL MEDIATORS. Spanish Mastocytosis Network.
9. Valent P ACAMBKBJCMea. (2012). Definitions, criteria and global classification of mast cell disorders with special reference to mast cell activation syndromes: a consensus proposal. In Arch Allergy Immunol:3.



This work is licensed under Creative Commons Attribution 4.0 License

To Submit Your Article Click Here:

**Submit Manuscript**

DOI: [10.31579/2578-8949/137](https://doi.org/10.31579/2578-8949/137)

**Ready to submit your research? Choose Auctores and benefit from:**

- fast, convenient online submission
- rigorous peer review by experienced research in your field
- rapid publication on acceptance
- authors retain copyrights
- unique DOI for all articles
- immediate, unrestricted online access

At Auctores, research is always in progress.

Learn more <https://auctoresonline.org/journals/dermatology-and-dermatitis>