

Description of a Case of Treatment of a Combined wound with Partial Scalping with SR -19 Ointment

Sergey Ros Yak *

independent researcher, associate professor of the Ukrainian State University of Food Technologies, Kiev, Ukraine

***Corresponding Author:** Sergey Ros Yak, independent researcher, associate professor of the Ukrainian State University of Food Technologies, Kiev, Ukraine.

Received date: November 01, 2023; **Accepted date:** December 01, 2023; **Published date:** January 18, 2024

Citation: Sergey Ros Yak, (2024), Description of a Case of Treatment of a Combined wound with Partial Scalping with SR -19 Ointment. *J. Pharmaceutics and Pharmacology Research*, 7(1); DOI:10.31579/2688-7517/153

Copyright: © 2024, Sergey Ros Yak. This is an open access article distributed under the Creative Commons Attribution License, which permits unrestricted use, distribution, and reproduction in any medium, provided the original work is properly cited.

Abstract

In terms of the number of industrial injuries in the world over the past 20 years, there has been a positive trend; occupational safety is increasing. At the same time, the mechanization of domestic work has led to a significant increase in the number of domestic injuries. The rate of growth in the number of domestic injuries outpaces the rate of decline in the number of industrial injuries. Among household injuries, combined injuries, which can combine signs of two or more types of injuries, become dominant. This determines the difficulty in their treatment and the frequent occurrence of severe complications. The goal is to evaluate and determine the effectiveness of the ointment and suspension we developed in the treatment of combined wounds.

Key words: cbd; cannabis; hemp; rheumatologic disease; treatment

Introduction

the case of domestic injury in question occurred on September 21, 2020 in the garden, while the author (67 years old) of this message was pruning a fruit tree with an electric band saw. The cut branch sprung and threw away the tire of the working band saw. The blow struck the interphalangeal joint of the left index finger. The bleeding was stopped by pressing the edges of the wound with fingers. The nature of the wound was established - cut and torn, with partial (approximately 30%) scalping of the joint. The wound was examined to its full depth in order to detect foreign bodies and possible damage. It was visually determined that the wound was relatively clean, uninfected, the collateral ligaments were torn, and there was no bone damage or penetration into the joint. Therefore, the wound was closed immediately and no cleansing was performed, as was no local anesthesia or tetanus immunization (no need). The time was less than 20 minutes. The wound is located above the joint. Classification: By number – multiple. By localization - index finger. By type of damage - combined injuries. According to the circumstances of receipt - household. According to depth - partial (partially deep). By the nature of tissue damage - from external influences - mechanical; by the appearance of the wounding agent - torn - scalped. In appearance (color) it is pale pink. According to the degree of wound exudation - moderately exuding. In relation to body cavities - non-penetrating. The shape of the wound cavity is deep. The shape is like wounds with uneven contours. The wounds are small in size (up to 50 sq. cm). According to the degree of contamination - bacterially contaminated. According to the duration of

the wound process – acute. According to the nature of the wound process – uncomplicated. The length of the two main wounds is 3.5 cm. The depth is about 0.5 cm, the total area is about 5 sq. cm.

Materials

We have developed a composition of ointment SR-19 with native (not subject to external interference and retaining its appearance and properties) royal jelly and propolis. The absence of a medicinal base for the ointment made it possible to achieve maximum effectiveness of the medicinal substances. The main components of the ointment: royal jelly and propolis. Royal jelly is a secret secreted by the glands of young (non-flying) bees when laying queen cells, where they place an egg intended for hatching a queen. A worker bee is fed nectar and a small amount of milk and lives for about 30 days. A queen bee fed with milk lives up to 8 years, laying 1,500 eggs per day. The chemical composition of milk is very complex and at the current level of scientific development it is impossible to synthesize it (as, indeed, propolis and zabrus wax). It has a powerful ability for tissue regeneration and a strong general strengthening effect. In fact, it is a biogenic stimulant with a multifunctional spectrum of action, capable of having a stimulating effect and accelerating regeneration processes when introduced into the body. Propolis is a substance produced by bees to protect the hive from fungi, microorganisms, microbes, and viruses. The only antibiotic to which microorganisms do not develop resistance. This uniqueness is determined

by the fact that the composition of the propolis substance is constantly changing, as it depends on the types of honey plants, climatic conditions, and the morphology of bees. It has analgesic and hemostatic properties, promotes the rejection of necrotic tissue and enhances reparative processes. Wax obtained from shingles (at a temperature of no more than 68°C!) is a biologically active substance that has a number of unique bactericidal and preservative properties. Wax prevents infection from entering the wound surface, being absorbed through the skin and facilitating the penetration of other medicinal components. Highly effective as an anti-inflammatory agent. It was used by us in the manufacture of dressing material.

Treatment

After stopping the bleeding, a bandage with a therapeutic component was applied - a unique ointment SR-19, which allowed the body to compensate for the damage caused by the injury by starting the wound healing process and closing the damage as quickly as possible. When developing CP-19 ointment, we proceeded from the main effect of royal jelly - it mobilizes the body to fight diseases, propolis - it has anti-inflammatory and antioxidant properties. To achieve the set goals when developing the composition of the combined ointment CP-19, the ratio and quantity of the components of the composition were selected in such a way as to ensure the necessary medicinal properties, as well as their rapid and long-term action. As a result of experimental studies conducted earlier, it was

found that native royal jelly, in contrast to freeze-dried, exhibits a more pronounced pharmacological effect, in addition, its effect is significantly enhanced in combination with propolis. Fabric (with a density of up to 200 grams/sq. m.) impregnated with beeswax was used as a bandage. This dressing ensured: healing of the wound surface, simplification and acceleration of the dressing process, making it painless, maintaining a moist environment; prevented infection from entering the wound area, created a favorable environment that helped accelerate the healing process; does not stick to the wound, does not injure granulation tissue, is easily removed after healing, does not stick when touched with medical gloves, and its constituent components are non-toxic. This dressing itself has antimicrobial activity against gram-positive microorganisms. SR-21 ointment with zabrus wax was applied daily: the first and second days - 4 times with an interval of 2 hours, the third and fourth days - 3 times with the same interval (see Figure 1.1. September 23, 2020(the third day), Figure 1. 2. September 23, 2020(the third day) and Figure 2.1. September 24,2020(fourth day), Figure 2.2. September 24, 2020(fourth day)), fifth and sixth times (see Figure 3.1. September 2, 2020(fifth day), Figure 3.2. September 27, 2020(fifth day) and Figure 4.1. September 28 2020(sixth day) ,4.2. September 28 2020(sixth day)); seventh and eighth -1 times (see Figure 5.1. September 29, 2020 (seventh day), Figure 5 .2. September 29, 2020 (seventh day) and Figure 6.1. September 30, 2020 (eighth day), Figure 6 .2. September 30 2020 (eighth day)).

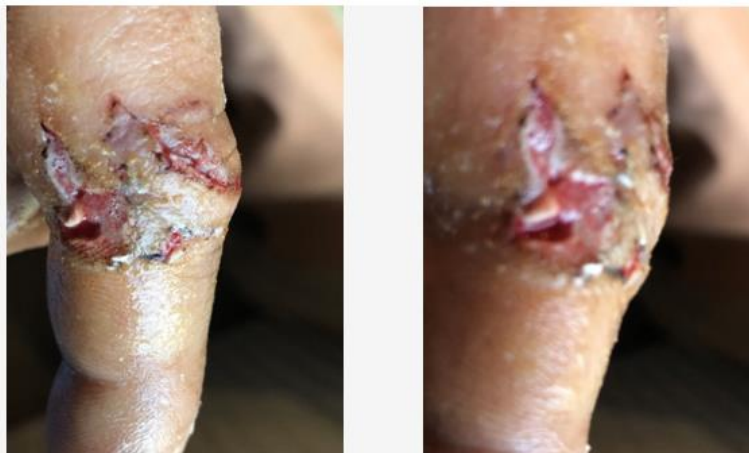

Figure 1.1. September 23, 2020(the third day).

Figure 1.2. September 23, 2020(the third day).

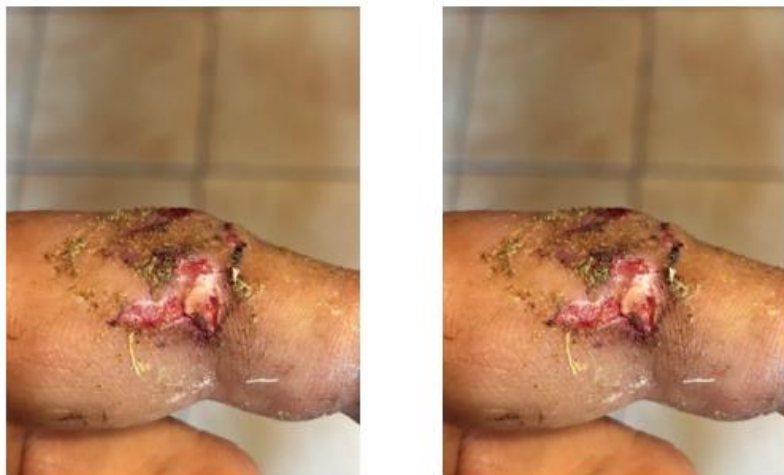


Figure 2 .2. September 24, 2020(fourth day).

Figure 2 .2. September 24, 2020(fourth day).

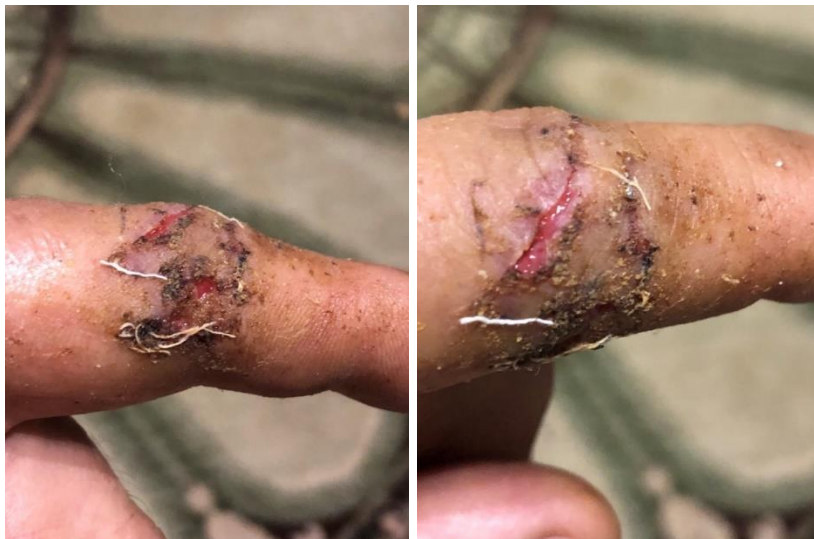

Figure 3 .1.September 27, 2020(fifth day).

Figure 3 .2. September 27, 2020(fifth day).

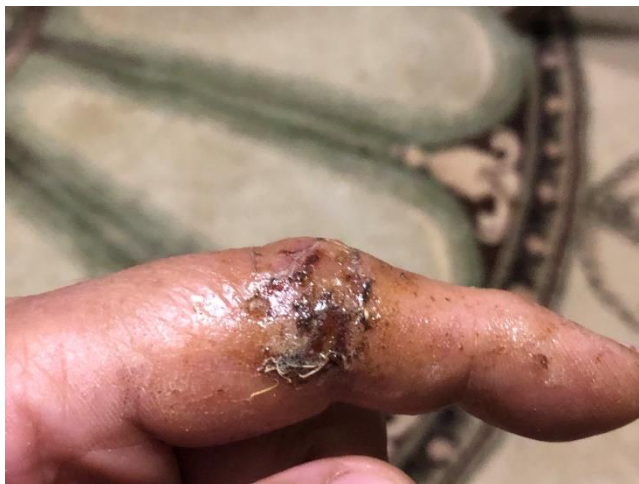

Figure 4 .1 . September 28 2020 (sixth day)

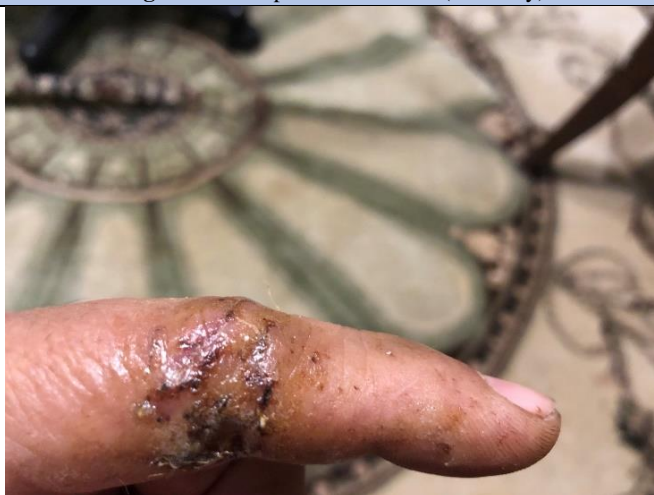

Figure 4.2. September 28 2020 (sixth day).

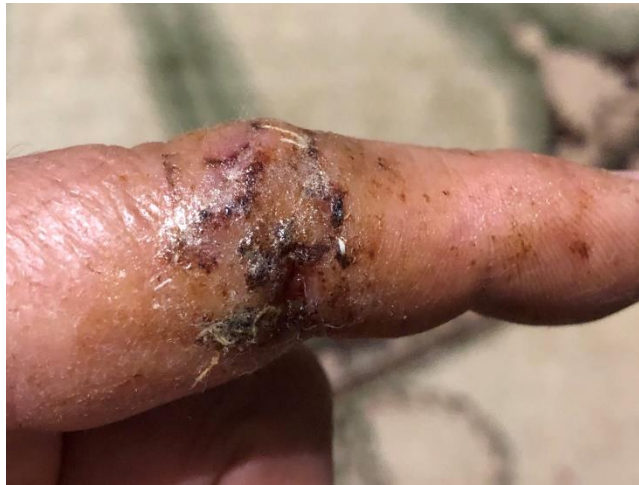

Figure 5 .1. September 29 2020(seventh day).

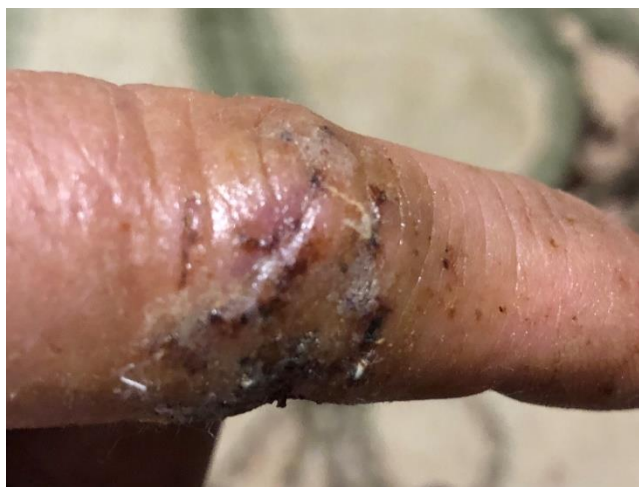

Figure 5 .2. September 29 2020(seventh day).

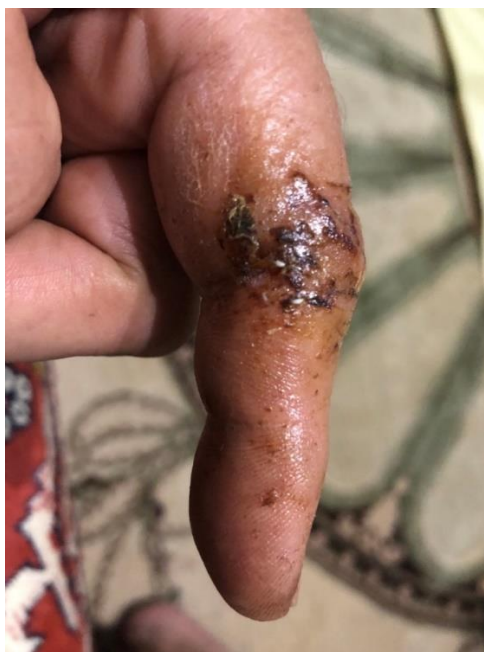

Figure 6 .1. September 30 2020(eighth day).

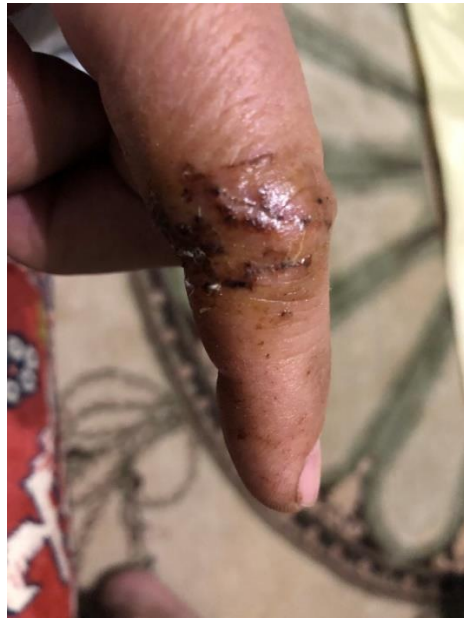

Figure 6 .2. September 30 2020(eighth day).

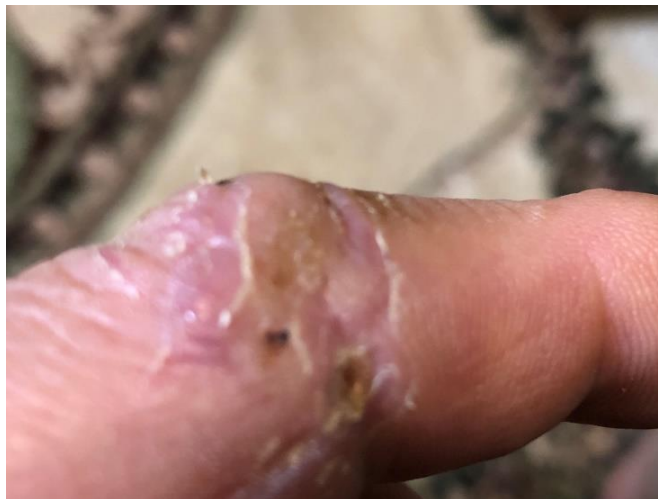

Figure 7. 1. October 9, 2020(seventeenth day).

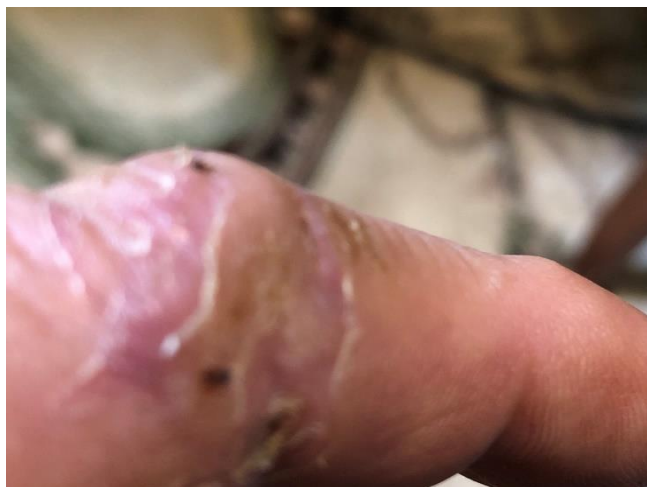

Figure 7.2. October 9, 2020(seventeenth day).

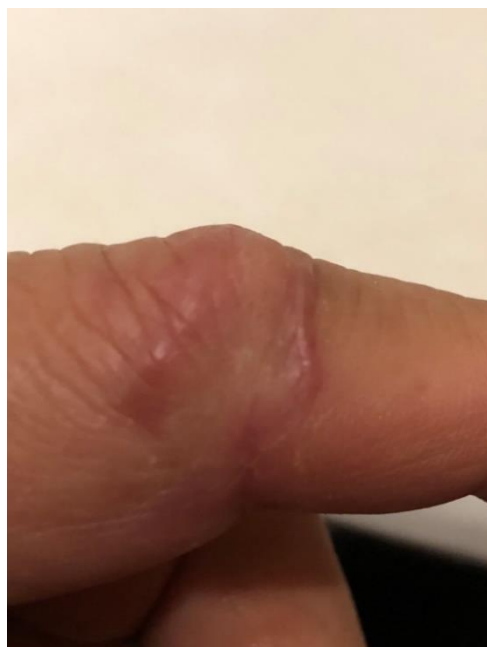

Figure 8 .1. October 21, 2020(a month later).

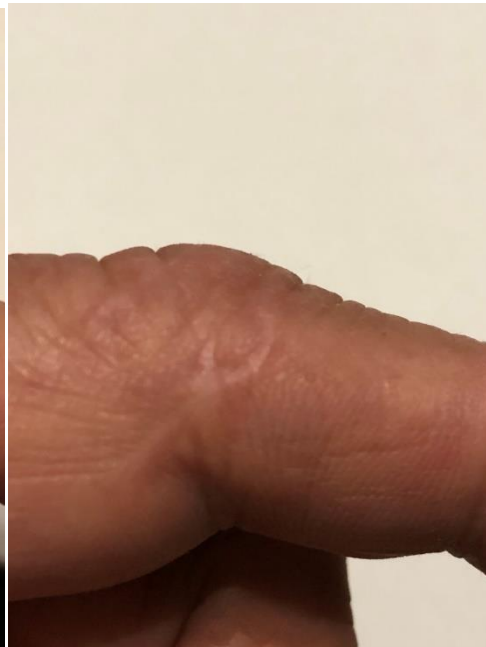

Figure 9 .1. October 21 ,2023(in 3 years).

No wound infection developed (see Figure 7.1. October 9, 2020(seventeenth day), Figure 7.2. October 9, 2020(seventeenth day)). The healing process took place: the bleeding stop phase - through direct pressure on the wound, the inflammation phase lasted 2 days after the wound (usually 4-5 days in the absence of complications); the regeneration and proliferation phase lasted 3 days (see Figure 3.1. September 27, 2020(fifth day), Figure 3.2. September 27, 2020(fifth day) (on average lasts 2-4 weeks) and the phase of epithelialization and reorganization of the scar lasted 8 days (see Figure 6.1. September 30 2020(eighth day), Figure 6.2. September 30 2020(eighth day) ; Figure 7.1. October 9, 2020(seventeenth day), Figure 7.2. October 9, 2020(seventeenth day) and Figure 8.1 October 21, 2020(a month later)) (usually, depending on the morphology of the tissue, lasts from a month to a year). Healing occurred by primary intention, without suppuration, with the formation of a linear scar without the formation of interstitial tissue, with the absence of an unpleasant odor. The wound is normal, should heal in 8 weeks, in our case - in 2 weeks. There was no need to take painkillers. Treatment of wounds with SR-19 ointment and dressings with zabrus wax lasted 8 days, during which 20 changes of dressings were made. We proceeded from that the adequacy of the inflammatory response, the body's ability to resist the addition of a secondary infection, and the timing of healing largely depend on the state of the immune system. Therefore, supporting the body is an important component of therapy for healing injuries, regardless of the nature of their occurrence. For this purpose, in 2020, the suspension mixture SR-21 was developed and used for the first time. Its composition: native (live) royal jelly (100% Native Royal Jelly), powder from crushed ginseng roots (Pánax), coenzyme Q10, excipient - white acacia honey (as low-allergenic). For patients undergoing rehabilitation or antibacterial therapy, the use of this suspension mixture enhances the therapeutic effect of antibiotics (in our case natural), ensures accelerated wound healing, reduces toxicity, and reduces the side effects of chemotherapy drugs. When developing the SR-21 suspension, we were based on the main effect of royal jelly - this is the mobilization of the body to fight the disease; ginseng - improvement of the immune system, anti-inflammatory and antioxidant properties, general tonic and restorative effect, reduction of fatigue and exhaustion; Coenzyme Q 10 - destroys free radicals, restores immunity, protects cells from the destructive effects of oxidative processes, viruses and bacteria. The results of practical application indicate that a single dosage for

preventive purposes of a standardized substance (2% royal jelly, 1.5% ginseng, 1.5% coenzyme Q 10.95% white acacia honey) is 18 ml; for injuries and diseases, it is recommended to take the SR-21 suspension of the following composition: - native royal jelly - 4%, ginseng root powder - 1.5%, coenzyme Q 10-1.5%, excipient - white acacia honey - 93%, daily dose - about 20 ml. The duration of administration of the suspension was 4 weeks, followed by repeated cycles after a 2-week period.

Complications. Patients with scalp wounds face two types of undesirable consequences - suppuration and tissue necrosis and associated associated damage. In our case, the scalp wound was accompanied by damage to the collateral ligaments of the interphalangeal joint of the index finger, which led to the inability to flex it. After some time, pain appeared, the finger became bent, the victim could not bend it, and swelling occurred near the bone joint. After conservative treatment, rehabilitation actions were aimed primarily at restoring range of motion in the joint, restoring sensitivity and fine motor skills, biomechanics of grip and coordination of movements. The time for complete recovery with active exercise was about a month.

Results and conclusions

the use of SR-19 ointment with dressings with zabrus wax allows you to quickly and painlessly treat the wound. The wide spectrum of antimicrobial activity of these agents ensures the neutralization of all microorganisms - viruses, bacteria, fungi and spores. The components of SR-19 ointment are natural highly effective antibiotics and biogenic stimulants. A wound covered with a wax dressing with SR-18 ointment is protected from secondary infection, and therefore the first phase of the wound process proceeds more quickly and is not complicated. The wound was not accompanied by complications, both immediately after the wound was inflicted and in the long term. The actual duration of wound healing phases is several times less than generally accepted. The dressing process was almost painless. The use of the developed SR-21 suspension provided an effective addition to the main treatment, enhanced the therapeutic effect of the main drugs, increased the immune status and resistance of the body.

Discussion

A wax bandage with SR-19 ointment was also used for lacerated wounds inflicted by a dog of the wolf-dog breed (a cross between a wolf and a husky, hence the specificity of the wounds). The wounds (hand, 10-15 mm deep) were washed with peroxide, tightly bandaged and closed 1 hour after the injury. SR-21 ointment with a bandage with zabrus wax was applied daily: the first and second days - 4 times with an interval of 2 hours, the third and fourth days - 3 times with the same interval, the fifth day - 1 time. No wound infection developed. Treatment of wounds with SR-19 ointment and dressings with zabrus wax lasted 5 days, during which 15 dressing changes were made. SR-21 ointment with a bandage with zabrus wax was also used in the treatment and prevention of recurrent ulcers due to diabetes mellitus. A group of volunteers (8 people, age group 61-82 years), with purulent-necrotic complications of diabetic foot syndrome, applied the recommended ointment 14 days 3 times a day in the first year - quarterly, the second - as needed. The appearance of a clear clinical effect depended on the severity of the purulent process and intoxication and ranged from 5 to 10 days. The maximum therapeutic effect was ensured with minimal impact on the body of the patient, who usually suffers from severe concomitant diseases. At the same time, preventive measures were carried out, which consisted of taking the SR-21 suspension we developed, which was taken for 14 days every three months for 2 years. Positive results from the use of developed drugs based on native royal jelly and propolis represent an attractive concept for the development of new pharmaceutical products in the treatment and prevention of recurrent ulcers, open traumatic wounds of soft tissue, open fractures with soft tissue defects; wounds that developed after surgical treatment of abscesses, postoperative wound purulent complications. The duration of treatment for patients is reduced significantly, dressing procedures are ensured painless, and the number of repeated amputations is reduced. Although this study has many strengths (high efficacy, low

cost of the drug, accessibility, possibility of concomitant use of pharmaceuticals, absence of complications), there are limitations. First of all, these include the insufficient volume of clinical studies.

Conflict of interest

The author Sergey Roslyak is an independent researcher and is not an employee of government agencies or private companies offering contract development services for the pharmaceutical industry. Funding This study was fully funded by the author.

Acknowledgments

I would like to thank my wife Svetlana Roslyak for her patience, beekeeper Vladimir Malykhin for technical advice on collecting royal jelly, Dr. Irina Roslyak and Dr. Sergei Dakhnov for critical reading.

References

1. Дейкало В. П. Повреждения кисти: эпидемиология, потери трудоспособности, медицинская реабилитация: автореф. дис. д-ра мед. наук: / В. П. Дейкало. – Минск. , 2003. –41с.
2. Мальных В.Е. Креативное пчеловодство. Харьков: 2012.
3. Мальных В.Е. Материнское молоко, гомогенат. Вывод маток. Харьков: 2013.
4. Руководство по лечению ран. С.В.Горюнов, И.С.Абрамов, Б.А.Чапарьян, М.А.Егоркин, С.Ю.Жидких – Москва: 2013.
5. Страчунский Л.С., Белоусов Ю.Б., Козлов С.Н. Практическое руководство по антиинфекционной химиотерапии. Москва:2009.
6. Толмачева Е. А. Трофическая язва голени, стопы ru
7. Reiber G.E., Boyko E.J., Smith D.G. Lower extremity foot ulcer and amputations in diabetes. In: M.I. Harris, C. Cowie, M.P. Stern (Eds.) Diabetes in America: 2002.



This work is licensed under Creative Commons Attribution 4.0 License

To Submit Your Article Click Here:

[Submit Manuscript](#)

DOI: [10.31579/2688-7517/153](https://doi.org/10.31579/2688-7517/153)

Ready to submit your research? Choose Auctores and benefit from:

- fast, convenient online submission
- rigorous peer review by experienced research in your field
- rapid publication on acceptance
- authors retain copyrights
- unique DOI for all articles
- immediate, unrestricted online access

At Auctores, research is always in progress.

Learn more <https://auctoresonline.org/journals/pharmaceutics-and-pharmacology-research>