

## A Survey of Monkey Pox Disease in Humans

Nallabothula Priyanka

Department of Pharm.D, Krishna Teja Pharmacy College, JNTU Anantapur, A.P, India

\*Corresponding Author: Nallabothula Priyanka, Department of Pharm.D, Krishna Teja Pharmacy College, JNTU Anantapur, A.P, India

Received date: October 11, 2023; Accepted date: November 17, 2023; Published date: November 22, 2023

Citation: Nallabothula Priyanka, (2023). A Survey of Monkey Pox Disease in Humans, *J Clinical Research and Reports*, 14(2); DOI:10.31579/2690-1919/326

Copyright: © 2023, Nallabothula Priyanka. This is an open access article distributed under the Creative Commons Attribution License, which permits unrestricted use, distribution, and reproduction in any medium, provided the original work is properly cited.

### Abstract

Human monkey pox is a zoonotic Orthopoxvirus with a presentation similar to smallpox. Clinical differentiation of the disease from smallpox and varicella is difficult. Laboratory diagnostics are principal components to identification and surveillance of disease and new tests are needed for a more precise and rapid diagnosis. The majority of human infections occur in Central Africa, where surveillance in rural areas with poor infrastructure is difficult but can be accomplished with evidence-guided tools and educational materials to inform public health workers of important principles. Contemporary epidemiological studies are needed now that populations do not receive routine smallpox vaccination. New therapeutics and vaccines offer hope for the treatment and prevention of monkey pox; however, more research must be done before they are ready to be deployed in an endemic setting. There is a need for more research in the epidemiology, ecology, and biology of the virus in endemic areas to better understand and prevent human infections.

**Keywords:** monkey pox; orthopoxvirus; smallpox

### Introduction:

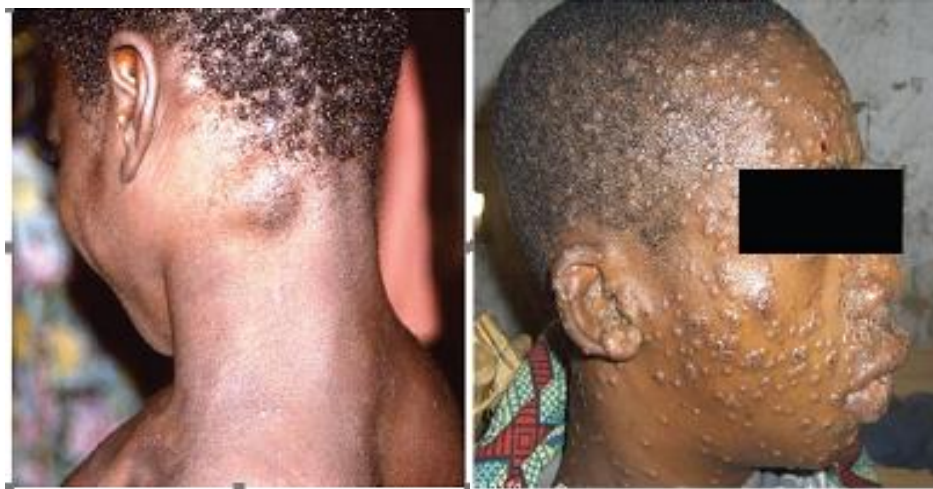Monkeypox virus is an Orthopoxvirus, a genus that includes camelpox, cowpox, vaccinia, and variola viruses. The virus is the foremost Orthopoxvirus affecting human populations since smallpox eradication, confirmed by the World Health Organization in 1980. Clinical recognition, diagnosis, and prevention still remain challenges in the resource-poor endemic areas where monkeypox is found. Monkeypox epidemiology is informed by studies conducted at the end of smallpox eradication, but new assessments are needed now that routine smallpox vaccination has ended and there is associated waning herd immunity. Additionally, foundational ecological studies are necessary to better understand the animal species involved in transmission and maintenance of the virus, and to further inform prevention measures.

### Clinical Picture

Human monkeypox was not recognized as a distinct infection in humans until 1970 during efforts to eradicate smallpox, when the virus was isolated from a patient with suspected smallpox infection in The Democratic Republic of the Congo (DRC) [1]. The majority of the clinical characteristics of human monkeypox infection mirror those of smallpox (discrete ordinary type or modified type, Table 1) [2–4]. An initial febrile prodrome is accompanied by generalized headache and fatigue. Prior to, and concomitant with, rash development is the presence of maxillary, cervical, or inguinal lymphadenopathy (1–4 cm in diameter) in many patients. Enlarged lymph nodes are firm, tender, and sometimes painful. Lymphadenopathy was not characteristic of smallpox. The presence of lymphadenopathy may be an indication that there is a more effective immune recognition and response to infection by monkeypox virus vs variola virus, but this hypothesis requires further study [5].

| Key Clinical Characteristics of Smallpox, Monkeypox, and Varicella |   |   |   |
|--|---|---|---|
| Characteristic   | Smallpox  | Monkeypox   | Varicella   |
| <b>Time period</b>   |   |   |   |
| Incubation period  | 7-17 d  | 7-17 d  | 10-21 d   |
| Prodromal period   | 1-4 d   | 1-4 d   | 0-2 d   |
| Rash period (from the appearance of lesions to desquamation)       | 14-28 d   | 14-28 d   | 10-21 d   |
| <b>Symptoms</b>  |   |   |   |
| Prodromal fever  | Yes   | Yes   | Uncommon, mild fever if present   |
| Fever  | Yes, often >40°C  | Yes, often between 38.5°C and 40.5°C  | Yes, up to 38.8°C   |
| Malaise  | Yes   | Yes   | Yes   |
| Headache   | Yes   | Yes   | Yes   |
| Lymphadenopathy  | No  | Yes   | No  |
| Lesions on palms or soles  | Yes   | Yes   | Rare  |
| Lesion distribution  | Centrifugal   | Centrifugal*  | Centripetal   |
| Lesion appearance  | Hard and deep, well-circumscribed, umbilicated  | Hard and deep, well-circumscribed, umbilicated*   | Superficial, irregular borders, "dew drop on a rose petal"                        |
| Lesion progression   | Lesions are often in one stage of development on the body; slow progression with each stage lasting 1-2 d | Lesions are often in one stage of development on the body; slow progression with each stage lasting 1-2 d | Lesions are often in multiple stages of development on the body; fast progression |

**Table 1:** Key Clinical Characteristics of Smallpox, Monkeypox and Varicella

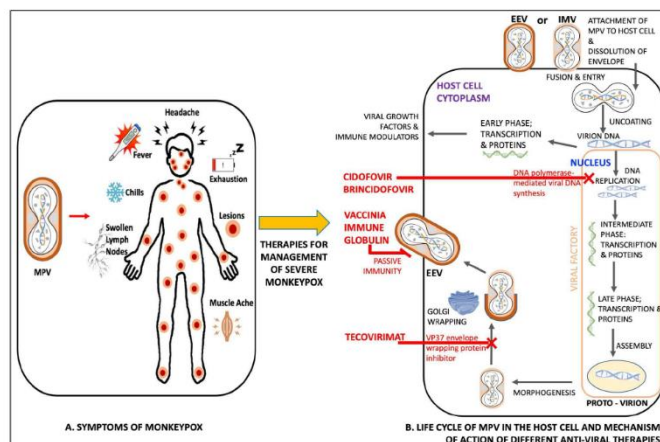


**Figure 1:** Cervical Lymphadenopathy in a Patient with Active Monkeypox

**Clinical Symptoms:**

Antiviral use for those with clinical features of aberrant disease in atypical locations, severe disease, complications, and those at high risk for severe disease has been suggested. Risk factors for severe disease includes age < 8 years, atopic or other exfoliative dermatitis, pregnancy, lactation and immunocompromise. Immunocompromising conditions include uncontrolled HIV, acquired immunodeficiency syndrome, leukemia, lymphoma, other malignancy, radiation, solid organ transplantation,

hematopoietic stem cell transplantation <24 months post-transplant or >24 months post-transplant with graft-versus-host disease or disease relapse, autoimmune disease with immunodeficiency; and lastly iatrogenic immunosuppression as a result of the use of alkylating agents, antimetabolites, tumor necrosis factor inhibitors or high dose corticosteroids. Additionally, symptomatic, and supportive care along with effective pain management are paramount [16].



**Figure 2:** Symptoms of Monkeypox and Life Cycle of MPV inside the Host Cell Cytoplasm to Elicit the Mechanism of Action of Four Different Antiviral Therapies: Cidofovir, Brincidofovir, Vaccinia Immune Globulin and Tecovirimat

## Four different antiviral therapies Tecovirimat

Tecovirimat (TPOXX) was approved by the FDA in 2018 for the treatment of smallpox in adults and children. It inhibits VP37, a viral envelope wrapping protein and disrupts viral replication and release. It is currently available for use in the US under an expanded access investigational new drug protocol at no cost (EA-IND) [10]. Tecovirimat is available as oral and intravenous formulations. While efficacy data on the use of TPOXX against Monkey pox are lacking, a favorable safety profile with common adverse effects such as headache, nausea, vomiting and abdominal pain has been reported. Neutropenia has also been reported among one trial participant [11]. Intravenous formulation use may result in infusion site erythema, pain and swelling [10]. Thornhill et reported on the treatment of recent Monkey pox cases with TPOXX [15]. Adler et al describe management of a human Monkey pox case with TPOXX with a favorable outcome [12]. Monkey pox in a returning traveler from Nigeria to the US, treated with TPOXX has also been recently described [13].

### Brincidofovir

Brincidofovir was approved by the FDA for use against smallpox in adults and pediatric patients, in June 2021. It is a prodrug of Cidofovir and contains a lipid conjugate. Intracellularly, it is converted to Cidofovir and eventually its active metabolite, Cidofovir diphosphate (CDP), which incorporates into viral DNA and inhibits viral DNA polymerase, thereby inhibiting viral replication. Large scale human data on the use of Brincidofovir against MPV are lacking but an animal model showed trends of protection against lethal Monkey pox with 29-57% survival rates among infected prairie dogs, depending on the time of treatment initiation [14].

Adler et al also described 3 human cases of Monkey pox treated with Brincidofovir. Treatment cessation occurred due to elevation of liver enzymes [8]. Brincidofovir is available as an oral formulation (tablet and oral suspension) and has a better renal safety profile compared to Cidofovir [9].

### Cidofovir

Cidofovir has the same mechanism of action as its prodrug, Brincidofovir. Large scale human data on efficacy of Cidofovir against Monkey pox are lacking. However, animal data on its use against orthopox viruses including Cowpox, Vaccinia, Ectromelia and Rabbitpox exist [18]. Thornhill et al reported cases amid the 2022 Monkey pox outbreak that were treated with Cidofovir. It is only available as an intravenous formulation and can have significant renal toxicity [19].

Vaccinia Immune Globulin Intravenous (Vigiv)

VIGIV is FDA licensed for treatment of complications after Vaccinia vaccination, including Vaccinia (progressive or severe generalized), eczema vaccinatum and aberrant infections due to Vaccinia virus. It can also be used for Vaccinia infections in those with certain skin conditions [16]. Data for its use against Monkey pox are lacking; but, in the US, it is available as a response measure in the event of Orthopoxvirus outbreaks under an EA-IND.

### Prevention

Some measures can help prevent spread of MPV. Direct contact based prevention strategies include - avoiding close, direct contact with people who have skin lesions resembling monkey pox, avoid touching the rash and scabs, avoiding close contact including hugging, kissing; avoiding sexual contact with infected individuals and avoiding contact with animals that exhibit monkey pox like symptoms [17]. Other prevention measures include - avoid sharing utensils with a person who has monkey

pox, avoid touching items that have been in contact with a person infected with monkey pox, such as bedding and clothes [16]. Washing hands frequently with soap and water or use of an alcohol-based hand sanitizer can be very effective. Healthcare professionals caring for patients should wear proper personal protective equipment, cover their entire body with a waterresistant gown, be double-gloved and use N-95 masks. Patients should be placed under contact isolation in a single patient room until all lesions have crusted and fully re epithelialized [18].

Studies have shown that the smallpox vaccine provides significant protection against monkey pox and may improve disease outcomes [8,18]. The two US FDA approved vaccines - JYNNEOS and ACAM2000 can be useful in prevention strategies for monkey pox. JYNNEOS contains live Vaccinia virus that is not replication competent in human cells and is administered as two subcutaneous doses, 28 days apart, with full protection being afforded 14 days after completion of the vaccine series. JYNNEOS is licensed by the FDA for adults 18 years and older against v1smallpox and Monkey pox. Unlike ACAM2000, JYNNEOS can be given to those with HIV, atopic or other exfoliative dermatitis. ACAM2000 on the other hand, contains live replication-competent Vaccinia virus, and is given a single percutaneous dose by multiple puncture technique. After inoculation, a lesion (also called "take") develops at the injection site and may take upto 6 weeks to heal. Protective immunity is achieved at least 4 weeks after vaccination. ACAM2000 is licensed for use against smallpox and can be used against Monkey pox with an EA-IND. Since this is a live viral vaccine, it should not be given to certain individuals. ACAM2000 has been linked to cases of vaccination induced myocarditis and pericarditis [19].

The US CDC's recommendation on 'post-exposure prophylaxis' (PEP), coupled with isolation and utilizing other preventive methods, is vaccinating individuals 4 days after monkey pox exposure to prevent disease and administration between 4-14 days can improve disease outcome [19]. PEP plus plus (PEP++) is an expanded approach aimed to reach people with certain risk factors even if they have not had documented exposure to confirmed Monkey pox cases, with the objective of flattening the epidemiological curve and slowing disease spread in areas with high levels of transmission [10]. These strategies can help prevent transmission and control disease outbreak further. Additionally, the pre-exposure prophylaxis (PrEP) guidelines by CDC suggests vaccinating individuals at high-risk for monkeypox [9]. While these vaccines have been tested for efficacy against monkeypox in animal studies (JYNNEOS) or allowed for clinical use under FDA's EA-IND, there is no data hitherto on their efficacy for PEP, PEP++ or PrEP for the current global outbreak [9-12]. Additionally, the administration of ACAM2000 is contraindicated in individuals with immunosuppression or immunocompromise, atopic dermatitis, eczema, pregnancy or breastfeeding, infants, underlying heart disease and among those with major cardiac risk-factors [14,15].

## Conclusion

Human monkey pox has the potential for spread via zoonotic reservoirs, as was demonstrated by the US outbreak. Civil conflict and displacements cause concerns for movement of the virus into an area without monkey pox, or movement of individuals to more heavily forested areas more prone for interaction with wildlife and a range of zoonoses. The documented rise in incidence of human disease needs further evaluation and consideration with additional studies to better understand the range of factors involved in disease transmission and spread. There are still many unanswered questions about human disease, animal reservoirs, and

the virus itself—advances in our understanding of this important zoonosis will help better guide prevention strategies and mitigate human disease.

## References

1. Ladnyj ID, Ziegler P, Kima E (1972). A human infection caused by monkeypox virus in Basankusu Territory, Democratic Republic of the Congo. *Bull World Health Organ* 46:593–597.
2. Breman JG, Henderson DA (2002). Diagnosis and management of smallpox. *N Engl J Med* 346:1300–1308.
3. Breman JG, Kalisa R, Steniowski MV, Zanotto E, Gromyko AI, Arita I (1980). Human monkeypox, 1970–1979. *Bull World Health Organ* 58: 165–182.
4. Jezek Z, Fenner F (1988). *Human monkeypox*. New York: Karger,
5. Damon IK (2011). Status of human monkeypox: clinical disease, epidemiology and research. *Vaccine* 29(suppl 4): D54–59.
6. Di Giulio DB, Eckburg PB (2004). Human monkeypox: an emerging zoonosis. *Lancet Infect Dis* 4:15–25.
7. Jezek Z, Szczeniowski M, Paluku KM, Mutombo M (1987). Human monkeypox: clinical features of 282 patients. *J Infect Dis* 156: 293–298.
8. Learned LA, Reynolds MG, Wasswa DW, et al (2005). Extended interhuman transmission of monkeypox in a hospital community in the Republic of the Congo, 2003. *Am J Trop Med Hyg* 73:428–434.
9. Macneil A, Reynolds MG, Braden Z, et al (2009). Transmission of atypical varicella-zoster virus infections involving palm and sole manifestations in an area with monkeypox endemicity. *Clin Infect Dis* 48: e6–8.
10. Seward JF, Galil K, Damon I, et al (2004). Development and experience with an algorithm to evaluate suspected smallpox cases in the United States, 2002–2004. *Clin Infect Dis* 39:1477–1483.
11. Kulesh DA, Loveless BM, Norwood D, et al (2004). Monkeypox virus detection in rodents using real-time 3'-minor groove binder TaqMan assays on the Roche LightCycler. *Lab Invest* 84:1200–1208.
12. Li Y, Olson VA, Laue T, Laker MT, Damon IK (2006). Detection of monkeypox virus with real-time PCR assays. *J Clin Virol* 36:194–203.
13. Olson VA, Laue T, Laker MT, et al (2004). Real-time PCR system for detection of orthopoxviruses and simultaneous identification of smallpox virus. *J Clin Microbiol* 42:1940–1946.
14. Shchelkunov SN, Shcherbakov DN, Maksyutov RA, Gavrilova EV (2011). Species-specific identification of variola, monkeypox, cowpox, and vaccinia viruses by multiplex real-time PCR assay. *J Virol Methods* 175:163–169.
15. Karem KL, Reynolds M, Braden Z, et al (2005). Characterization of acute phase humoral immunity to monkeypox: use of immunoglobulin M enzyme-linked immunosorbent assay for detection of monkeypox infection during the 2003 North American outbreak. *Clin Diagn Lab Immunol* 12:867–872.
16. Townsend MB, Macneil A, Reynolds MG, et al (2013). Evaluation of the Tetracore Orthopox BioThreat® antigen detection assay using laboratory grown orthopoxviruses and rash illness clinical specimens. *J Virol Methods* 187:37–42.
17. Reynolds MG, Damon IK (2012). Outbreaks of human monkeypox after cessation of smallpox vaccination. *Trends Microbiol* 20:80–87.
18. Formenty P, Muntasir MO, Damon I, et al (2010). Human monkeypox outbreak caused by novel virus belonging to Congo Basin clade, Sudan, 2005. *Emerg Infect Dis* 16:1539–1545.
19. Berthet N, Nakoune E, Whist E, et al (2011). Maculopapular lesions in the Central African Republic. *Lancet* 378:1354.



This work is licensed under Creative Commons Attribution 4.0 License

To Submit Your Article Click Here: **Submit Manuscript**

DOI:10.31579/2690-1919/326

**Ready to submit your research? Choose Auctores and benefit from:**

- fast, convenient online submission
- rigorous peer review by experienced research in your field
- rapid publication on acceptance
- authors retain copyrights
- unique DOI for all articles
- immediate, unrestricted online access

At Auctores, research is always in progress.

Learn more <https://www.auctoresonline.org/journals/journal-of-clinical-research-and-reports>