

Tragal Cartilage Support for Temporalis Fascia Graft in type I Tympanoplasty

Nirmala Mahadev Yamagar ¹, Shreeya Vinay Kulkarni ², Kirankumar Burse ³, Rushika Patel ⁴, Suramya Dhamija ⁵

¹ MBBS, MS ENT- Junior resident Department of otorhinolaryngology & head, neck surgery, Dr. Vasanttrao Pawar medical college and research Centre. City-Nashik, State- Maharashtra, Country- India.

² MBBS, MS ENT, DNB ENT-Professor and Head of Department of otorhinolaryngology & head, neck surgery, Dr. Vasanttrao Pawar medical college and research Centre. City-Nashik, State- Maharashtra, Country- India.

³ MBBS, MS ENT-Professor Department of otorhinolaryngology & head, neck surgery, Dr. Vasanttrao Pawar medical college and research Centre. City-Nashik, State- Maharashtra, Country- India.

⁴ MBBS, MS ENT-Associate Professor Department of otorhinolaryngology & head, neck surgery, Dr. Vasanttrao Pawar medical college and research Centre. City-Nashik, State- Maharashtra, Country- India.

⁵ MBBS MS ENT-Junior resident Department of otorhinolaryngology & head, neck surgery, Dr. Vasanttrao Pawar medical college and research Centre. City-Nashik, State- Maharashtra, Country- India.

***Corresponding Author:** Nirmala Yamagar, Yamagar niwas, house no-879, ward no-2, Mayakanagar, bamnoli, kupwad, taluka- miraj, district- sangli, state- Maharashtra, pincode- 416436.

Received date: October 23, 2023: Accepted date: November 01, 2023: Published date: November 10, 2023

Citation: Cándido Adalberto Benítez Lorenzo, (2023), Tragal Cartilage Support for Temporalis Fascia Graft in type I Tympanoplasty, *J Clinical Otorhinolaryngology*, 5(6); DOI:10.31579/2692-9562/099

Copyright: © 2023, Nirmala Yamagar. This is an open access article distributed under the Creative Commons Attribution License, which permits unrestricted use, distribution, and reproduction in any medium, provided the original work is properly cited

Abstract

Aims & objectives: To evaluate the success rate of tympanoplasty type I in terms of closure of perforation when the graft is supported by tragal cartilage and to evaluate the auditory outcomes in patient undergoing tympanoplasty type I with tragal cartilage support.

Background: An observational study was carried out on 43 patients over a period of 2 yrs. From August 2020-December 2022. Patients with subtotal perforation, large central perforation, anterior and inferior perforation, perforation with tympanosclerotic plaques, revision surgery for failed myringoplasty in Age group of 18-60 yrs. were included. While those with small central perforation, posterior/ posterosuperior perforations, traumatic perforation was excluded. In this procedure, a portion of semi-lunar-shaped tragal cartilage is implanted medial to the anterior remnant of the tympanic membrane. A graft of the temporalis fascia is positioned between cartilage and the anterior portion of the tympanic membrane.

Result: Out of 43 patients, it was observed that 36 (83.72%) of the patients had healthy fascia grafts and 7 (16.28%) of the patients had reperforation in fascia graft.

It was observed that there was a drastic improvement in the hearing dysfunction of the patients. In the pre-operative audiometry, 41 (95.35%) had conductive hearing loss which was reduced to 7 (16.28%) patients in the postoperative study. There was no change in mixed hearing loss patients. The pre- and post-operative audiometry are statistically significant with a p-value <0.001.

Conclusion: In type I tympanoplasty, this study shows that cartilage support for fascia graft is a very dependable approach that significantly improves graft take-up and hearing status.

Keywords: large perforation; subtotal perforation; tragal cartilage; temporalis fascia; tympanoplasty; narrow anterior rim

Abbreviations

CSOM - Chronic suppurative otitis media Dr- Doctor

Fig- figure dB- Decibel k- Thousand

TM- Tympanic membrane mm- Millimeter

Std.- Standard

Introduction

Chronic suppurative otitis media (CSOM) tubotympanic type is the most common infective condition of ear, especially in developing nations like India.[1]

Tympanoplasty has been well established since decades as surgery of choice for CSOM. Heermann was the first to introduce the cartilage palisade technique, in 1962 [2].

There is a high risk of failure with subtotal or total perforations, tympanosclerosis and recurrent perforations after tympanoplasty.[3]

Though various methods are practiced for placement of graft in tympanoplasty for Subtotal perforation, failure of perforation is seen in 10 % of cases. The reasons of residual perforations are poor adaptation of graft, displacement of graft which may sink medially or may shift posteriorly or may shrink when the graft is supported medially only by gelfoam.[4].

A novel technique has been introduced in which a small semilunar-shaped piece of tragal cartilage is placed medial to the narrow anterior rim in case of a large or subtotal perforation. The temporalis fascia graft is placed lateral to this cartilage support and medial to the thin anterior rim. [4,5]

This cartilage supports the fascia graft medially firmly and remains in place. It stops the graft from sinking or contracting. This method has a very high percentage of success and significantly improves hearing.

The cartilage graft's extremely low metabolic rate has long been considered its greatest benefit. It gets nutrients by diffusion, is malleable and simple to deal with, and is resistant to deformation due to pressure changes. [6,7,8]

Methodology

The current study was carried out at Dr. Vasant Rao Pawar Medical College Hospital and Research Centre in Adgaon, Nashik. The institutional ethics committee gave its approval to the study protocol and consent documents. Patients had thorough examinations that included clinical, otoscopy, microscopic, and audiometry examinations. Tympanoplasty type I surgery with tragal cartilage support was then performed.

Inclusion criteria

1. Subtotal perforation
2. Large central perforation
3. Anterior and inferior perforation
4. Perforation with tympanosclerotic plaques
5. Revision surgery for failed myringoplasty
6. Age group-18-60 yrs.

Exclusion Criteria

1. Small central perforation
2. Posterior/ posterosuperior perforations

3. Traumatic perforation

4. Age group below 18 and above 60

Operative Procedure

- A 1:200,000 ratio of adrenaline to 2% xylocaine is used to infiltrate tragal area.
- The incision is made at the medial margin to retain the tragus's natural curve and hide any scarring.
- The tragal cartilage is harvested. Over the tragal cartilage, the perichondrium is divided. As it is thin, flat, and somewhat elastic, this tragal cartilage is perfect because it splays and adheres to the anterior rim when positioned medially.
- Post auricular Wilde's incision is taken. Temporalis fascia graft is taken. After that, the tympanomeatal flap is lifted, and a meatotomy is performed around 6-8 mm from the annulus.
- The perforation margins are freshened up. The flap is raised using the on lay technique, and the epithelium is lifted from the TM annulus until it reaches the posterior boundary of the perforation. At six o'clock, the fibro-mucosal layer is cut all the way to the annulus. Malleus handle is denuded along with de-epithelialization superiorly. On the fibrous layer, a clean cut is made anterior to the malleus handle. (This is done to ensure that the fascia graft is placed precisely later.) As seen in FIG I, the cartilage is cut in a semi-lunar form.
- The cartilage graft's dimensions are around 6-8 mm superoinferiorly and 3-4 mm antero-posteriorly. The amount of middle ear space may affect it. It is positioned softly medially to the anterior rim border, with the inferior tapering end in the hypo tympanum and the superior tapering end going anterior to the malleus.
- As illustrated in FIG II, the cartilage's antero-posterior curvature matches and blends with the anterior mesotympanum's curvature. The cartilage and TM's anterior rim margin should be in touch with one another.
- To guarantee this contact, gel foam is positioned medially to the cartilage in the middle ear. After that temporalis fascia graft is positioned anteriorly between the cartilage and the rim.
- It is positioned as inlay graft anterior to malleus handle superiorly and at 6 o'clock position inferiorly (where fibro-mucous layer was cut). Posteriorly it stays over the fibrous layer to become on lay graft and extends over the bony canal.
- Then posterior tympanomeatal flap is repositioned back.
- Gel foam is kept on the graft. Closure is done.

Postoperative follow/up-

- Postoperatively patients were followed up for 3 months duration.
- Days- 1week, 2week, 1month, 2month, 3month
- At 3 months follow-up was with a post-operative pure tone audiogram.
- Post-operative closure of perforation was noted.
- Pure tone pre and post-operative air bone gap in dB at 250, 500, 1000, 2000, 4000 and 8000 were compared.
- The success rate was measured in terms of graft uptake and air bone gap closure for hearing improvement.



Figure I: Tragal Cartilage.

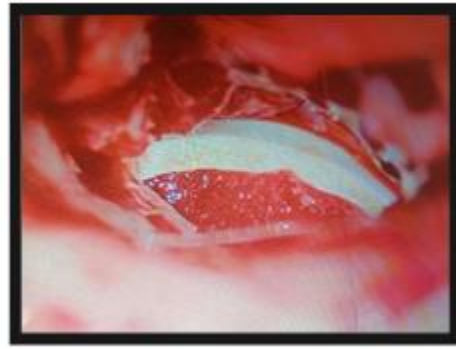


Figure II: Intraoperative Picture of Tragal Cartilage

Results

ALL the results obtained were properly recorded in the excel spreadsheet. The results were analysed on SPSS 25 software. The frequency, mean, percentage, standard deviation, and p-value were calculated. A p-value less than

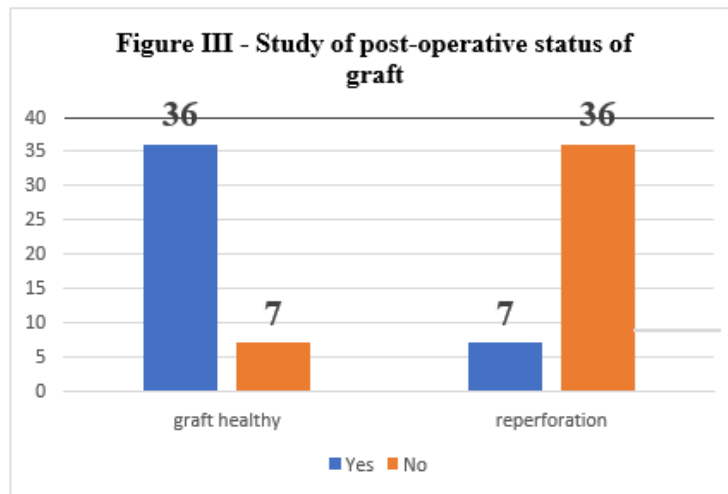
0.05 was taken as significant. All the obtained results are presented in a tabular and graphical format below. The variables that have been used to assess the outcome of tragal support for fascia graft are perforation size, preoperative hearing loss, tuning fork test, otomicroscopic examination, pure tone pre & post- operative audiometry.

Size of tympanic membrane perforation	Frequency (N)	Percentage (%)
Large	10	23.26
Small	1	2.33
Moderate	22	51.16
Subtotal	10	23.26
Total	43	100

Table I- Study of the size of tympanic membrane perforation

Graft status	Yes (Y)	Percentage (%)	No (N)	Percentage (%)
Graft healthy	36	83.72	7	16.28
Reperforation	7	16.28	36	83.72
Total	43	100	43	100

Table II – Study of the post-operation status of graft



Type	Pre-operative audiometry		Post-operative audiometry	
	Frequency (N)	Percentage (%)	Frequency (N)	Percentage (%)
CHL	41	95.35	7	16.28
Mixed	2	4.65	2	4.65
Normal	0	0.00	34	79.07
Total	43	100	43	100

Analysis	Value	DF	P value
Pearson	58.083	4	< 0.001
Fishers	61.045		< 0.001

Table III – Comparison of pre & post-operative audiometry

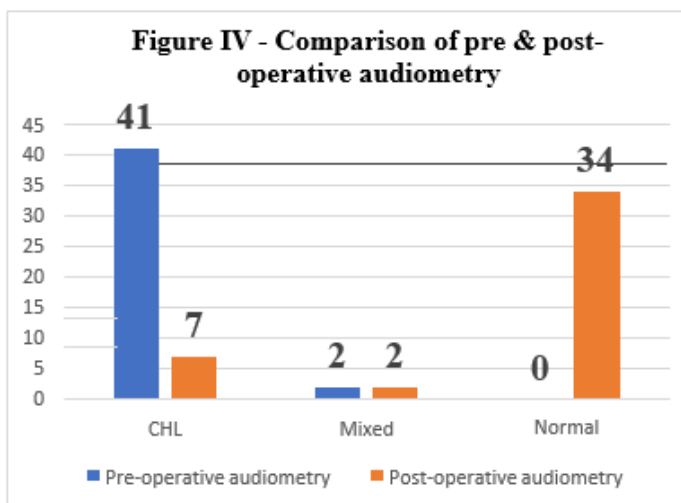
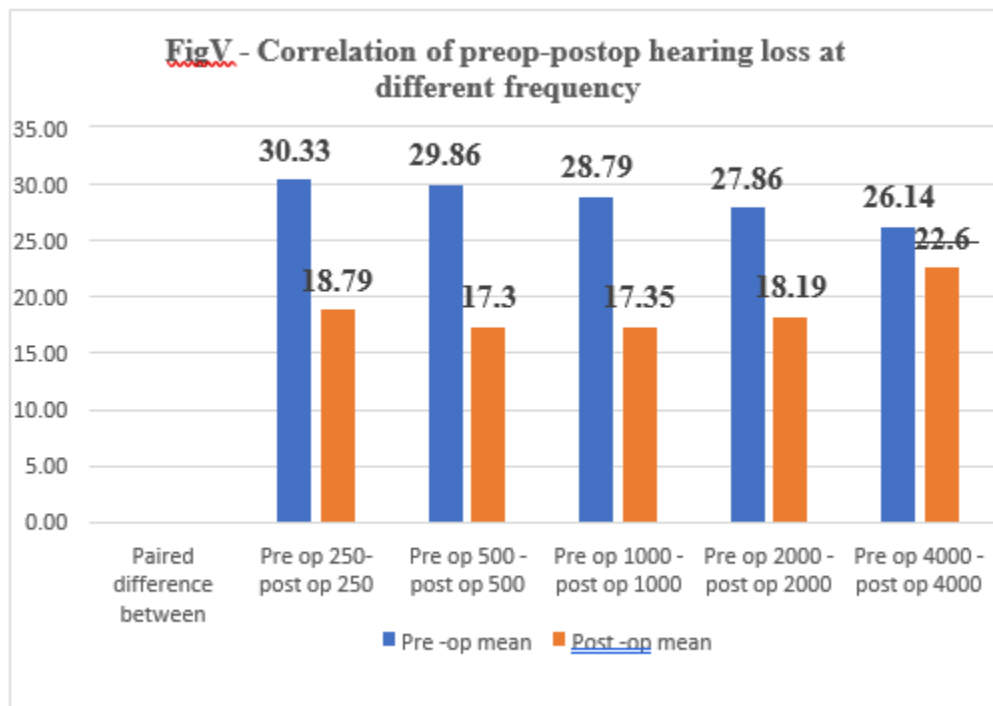


Table IV – Correlation of pre & post-operative hearing loss at different frequencies

Paired difference between	Pre - op mean	Post - op mean	Mean	Std. Deviation	Std. error mean	95 % CL of the difference				P- value
						Lower	Upper	t-test	df	
Pre op 250 - post op 250 Hz	30.33	18.79	11.54	10.34	1.58	8.45	14.63	7.312	42	< 0.001
Pre op 500 - post op 500 Hz	29.86	17.3	12.56	8.17	1.25	10.12	15.00	10.08	42	< 0.001
Pre op 1000 - post op 1000 Hz	28.79	17.35	11.44	7.87	1.20	9.09	13.79	9.53	42	< 0.001
Pre op 2000 - post op 2000 Hz	27.86	18.19	9.67	9.58	1.46	6.81	12.53	6.621	42	< 0.001
Pre op 4000 - post op 4000 Hz	26.14	22.6	3.535	10.55	1.61	0.38	6.69	2.20	42	0.0036



Discussion

The tympanic membrane has been reconstructed using a variety of graft materials, including fat, cartilage, periostia, perichondria, and temporalis fascia. Whatever the graft material utilized, subtotal perforations have always been a challenge to otologists [9]

Currently, temporalis fascia and tragal perichondrium are the most often utilized materials for tympanoplasty. [6]

Because of its accessibility, location, availability, minimal baseline metabolic rate, thickness that is comparable to the tympanic membrane, and great absorption rates in middle ear clefts that are routinely ventilated, temporalis fascia grafts have withstood the test of time. [10]

In cases of tympanic fibrosis, total perforation, an adhesive process, tubal dysfunction, and revision surgery, the healing of the temporalis fascia is significantly worse. [11]

However, in "high risk" situations such as large perforations, revision cases, middle ear disease, eustachian tube dysfunction, and atelectatic ears, cartilage myringoplasty produces satisfactory outcomes. [12]

Because it is readily available, flexible, resistant to negative middle ear pressures, stable, elastic, well-tolerated by the middle ear, and resistant to resorption, cartilage is a satisfactory grafting material. There has been debate over the audiological aspect because of its distinctive stiffness and thickness, but several investigations have shown that the audiological outcomes are satisfactory. [13]

We have made the most of both in this study. To ensure that the perforation closes completely, we are employing a temporalis fascia graft and supporting it with a tiny piece of tragal cartilage.

36 of the 43 patients in our research, or 83.72% of the total, had a successful surgical closure of their perforation. Since resident doctors performed the majority of these surgeries, more experience will produce better outcomes as observed with other comparable studies.

The statistical tests indicated that hearing had significantly improved. All of the following frequencies showed a good degree of air bone gap closure: 250, 500, 1k, 2k, and 4k. The closure was at its lowest at 4k.

Although the precise cause of this finding is unknown, the following theories might be valid. Though they are stiffer and thicker than fascia, perichondrium and cartilage are also mesenchymal tissue. They somewhat impede functional outcomes, particularly in the higher tones, by mechanically decreasing the tympanic membrane's vibratory pattern.[14]. Further research and analysis are needed for this finding.

Conclusion

In this study different variables like size of perforation, type of hearing loss, and degree of hearing loss were studied pre- operatively and post-operatively to evaluate the success rate of type I tympanoplasty and the auditory outcome. It was observed that post-operative closure rate of the tympanic membrane was high and audiology improvement was satisfactory. Stable postoperative outcomes are provided by tragal cartilage graft, with significant maintenance of auditory function and lower rates of reperforation.

Furthermore, cartilage is an excellent grafting material since it is easily accessible, adaptable, resistant to negative middle ear pressures, stable, elastic, well tolerated by the middle ear, and resistant to resorption. It provides strong support for the temporalis fascia graft. The anterior boundary becomes more effective. Graft does not sink in middle ear. If the temporalis fascia graft is properly tucked in, the graft does not retract backward. The anterior tympanic membrane is only supported by 1-2 mm. Therefore, it does not impair TM's movement. The eustachian tube continues to operate normally.

This approach is effective and a good substitute for traditional tympanoplasty for big or subtotal central perforations.

References

1. World Health Organisation/CIBA Foundation workshop reports, Prevention of Hearing Impairment from chronic otitis media, 1996.
2. Heermann J. Auricular cartilage palisade tympano-, epitympano-, antrum- and mastoid plasties. Clin Otolaryngology 1978;3:443-6.
3. Mirko Tos. Mirko Tos manual of middle ear surgery Vol.2 pg23-50

4. Finerman Wilmore B. Causes of failure in tympanoplasty. *J Natl Med Assoc.* 1964;56:136–138.
5. Dornhoffer J. Cartilage tympanoplasty: indications, techniques and outcomes in 1000 patient series. *Laryngoscope.* 2003; 113:1844–1856.
6. Amedee RG, Mann WJ, Riechelmann H (1989) Cartilage palisade tympanoplasty. *Am J Otol* 10:447–450. Vaidya S, Sharma H, Cartilage tympanoplasty for management of TM perforation: review of literature [internet]. 2012. URL: <http://www.waent.org/archives/2012/Vol5-1/20120120-cartilage-tympanoplasty/type-1-tympanoplasty.htm>. Accessed 20 Jan 2012
7. Dornhoffer J (2003) Cartilage tympanoplasty: indications, techniques and outcomes in 1000 patient series. *Laryngoscope* 113:1844–1856
8. Heermann J, Heermann H, Kopstein E (1970) Fascia and cartilage palisade tympanoplasty. *Arch Otolaryngol* 91:228–241
9. Fernandes VLG, Goel HC, De Sousa E, De Gouveia Pinto NM. A Comparative Study of Type-I Underlay Tympanoplasty with Temporalis Fascia Graft Alone and with Conchal Cartilage. *Indian J Otolaryngol Head Neck Surg.* 2019 Nov;71(Suppl 2):1320-1326. doi: 10.1007/s12070-018-1397-1. Epub 2018 May 11. PMID: 31750172; PMCID: PMC6841881.
10. Bhandarkar AM, Krishnan NV, Mathew NM. Interlay Cartilage Rim Augmented Fascia Tympanoplasty: An Effective Graft Model in Mucosal Chronic Otitis Media. *Indian J Otolaryngol Head Neck Surg.* 2022 Mar;74(1):32-38. doi: 10.1007/s12070-020-02150-y. Epub 2020 Sep 19. PMID: 35070923; PMCID: PMC8743324.
11. Kolethekkat AA, Al Abri R, Al Zaabi K, Al Marhoobi N, Jose S, Pillai S, Mathew
12. J. Cartilage rim augmented fascia tympanoplasty: a more effective composite graft model than temporalis fascia tympanoplasty. *J Laryngol Otol.* 2018 Jun;132(6):497-504. doi: 10.1017/S0022215118000762. Epub 2018 Jun 11. PMID: 29888699.
13. Diss-Altuna X, Navarro JJ, Martínez Z, Lobato R, Algaba J. Miringoplastia con cartilago "en isla". Resultados anatómicos y funcionales de 122 casos [Island cartilage myringoplasty. Anatomical and functional results in 122 cases]. *Acta Otorrinolaringol Esp.* 2010 Mar-Apr;61(2):100-5. Spanish. doi: 10.1016/j.otorri.2009.09.002. Epub 2009 Nov 7. PMID: 19897170.
14. Dornhoffer JL. Hearing results with cartilage tympanoplasty. *Laryngoscope.* 1997 Aug;107(8):1094-9. doi: 10.1097/00005537-199708000-00016. PMID: 9261014.
15. Kulkarni S, Kulkarni V, Burse K, Sancheti V, Roy G. Cartilage support for fascia graft in type I tympanoplasty. *Indian J Otolaryngol Head Neck Surg.* 2014 Sep;66(3):291-6. doi: 10.1007/s12070-014-0705-7. Epub 2014 Feb 1. PMID: 25032117; PMCID: PMC4071426.



This work is licensed under Creative Commons Attribution 4.0 License

To Submit Your Article Click Here: [Submit Manuscript](#)

DOI:10.31579/2692-9562/099

Ready to submit your research? Choose Auctores and benefit from:

- fast, convenient online submission
- rigorous peer review by experienced research in your field
- rapid publication on acceptance
- authors retain copyrights
- unique DOI for all articles
- immediate, unrestricted online access

At Auctores, research is always in progress.

Learn more <https://www.auctoresonline.org/journals/journal-of-clinical-otorhinolaryngology>