

Adenoid Cystic Carcinoma of Lacrimal Gland

Krishnappa Ramchandruppa¹, Rahul Kumar Shah^{2*}

¹ M.c.h. Surgical Oncology, Department of Head and Neck Oncology, Kidwai Memorial Institute of Oncology.

² M.c.h. Head and Neck Surgery Resident, Department of head and Neck Oncology, Kidwai Memorial Institute of Oncology.

***Corresponding Author:** Rahul Kumar Shah, M.c.h. Head and Neck Surgery Resident, Department of Head and Neck Oncology, Kidwai Memorial Institute of Oncology.

Received date: November 17, 2023; **Accepted date:** November 24, 2023; **Published date:** December 04, 2023

Citation: Krishnappa Ramchandruppa, Rahul K. Shah (2023), Adenoid Cystic Carcinoma of Lacrimal Gland, *Journal of Clinical Otorhinolaryngology*, 5(6); DOI:10.31579/2692-9562/100

Copyright: © 2023, Rahul Kumar Shah. This is an open access article distributed under the Creative Commons Attribution License, which permits unrestricted use, distribution, and reproduction in any medium, provided the original work is properly cited

Abstract

The lacrimal gland is a common site of various neoplastic and inflammatory diseases as orbital fossa masses differential diagnosis. [1-3]. Out of these ~50% are epithelial and 50% are nonepithelial in origin. Among epithelial origin, 50% are benign mixed tumor (pleomorphic adenomas), and 50% are carcinomas like- adenoid cystic carcinomas {50%}, malignant mixed tumors, primary adenocarcinomas, mucoepidermoid carcinomas, or squamous carcinomas

Keywords: adenocystic tumor; pleomorphic adenomas; primary adenocarcinomas

Introduction

The lacrimal gland is a common site of various neoplastic and inflammatory diseases as orbital fossa masses differential diagnosis. [1-3]. Out of these ~50% are epithelial and 50% are nonepithelial in origin. Among epithelial origin, 50% are benign mixed tumor (pleomorphic adenomas), and 50% are carcinomas like- adenoid cystic carcinomas {50%}, malignant mixed tumors, primary adenocarcinomas, mucoepidermoid carcinomas, or squamous carcinomas. [5-7]. Among nonepithelial origin, 50% are lymphoid tumors and 50% are infections and inflammatory- pseudotumors. Here we are presenting short case report of rare lacrimal gland adenocystic tumor.

Case Report

A 38 yrs. old female patient presented to us with history of pain in right eye, right sided headache since last 6 months. Patient also developed protrusion of right eye and difficulty in vision on right side since last 2 months. Patient was first consulted by an ophthalmologist and then she was referred to us.

On examination, patient had eccentric proptosis of right eye with globe displaced inferomedially with fullness in the superotemporal area associated with mild tenderness. Visual field restriction noted on temporal side. Pre auricular and neck lymphnodes were non palpable. Rest head and neck

examination was normal. Preoperative CT SCAN (plain+contrast) showed a well-defined heterogeneously enhancing lesion of 25*21 mm in superolateral aspect of right orbit in extraconal space, displacing the right globe anteroinferiorly without evidence of internal calcification and lacrimal gland was not seen separately. MRI (plain+ contrast) showed a well defined altered signal intensity in superolateral aspect of right orbit in extraconal compartment, with few areas of necrosis. Lesion measure 27*22*26 mm with anterior proptosis of right orbit. lesion is not showing lateral rectus infiltration. Bony remodelling of lateral wall of orbit seen. Optic nerve appeared normal. No intracranial involvement seen. USG guided FNAC was done outside and we did biopsy at our centre. On microscopic examination, it showed small round cell tumor with roset like formation. Histopathology report suggestive of tumor cells with focal tubular formation and hyalinized stroma, suggestive of salivary type of tumor of lacrimal gland origin. On immunohistochemistry, tumor cells were positive for CK, CD117 and P63 NKX2.2.- confirmatory of adenocystic carcinoma. Patient was underwent right orbital exenteration with sparing of eyelids. Histopathological examination of specimen confirmed it to be adenoid cystic carcinoma of lacrimal gland. Post op patient was stable and no any adverse event. Patient had taken radiotherapy and is now recurrence free since last 2 years.

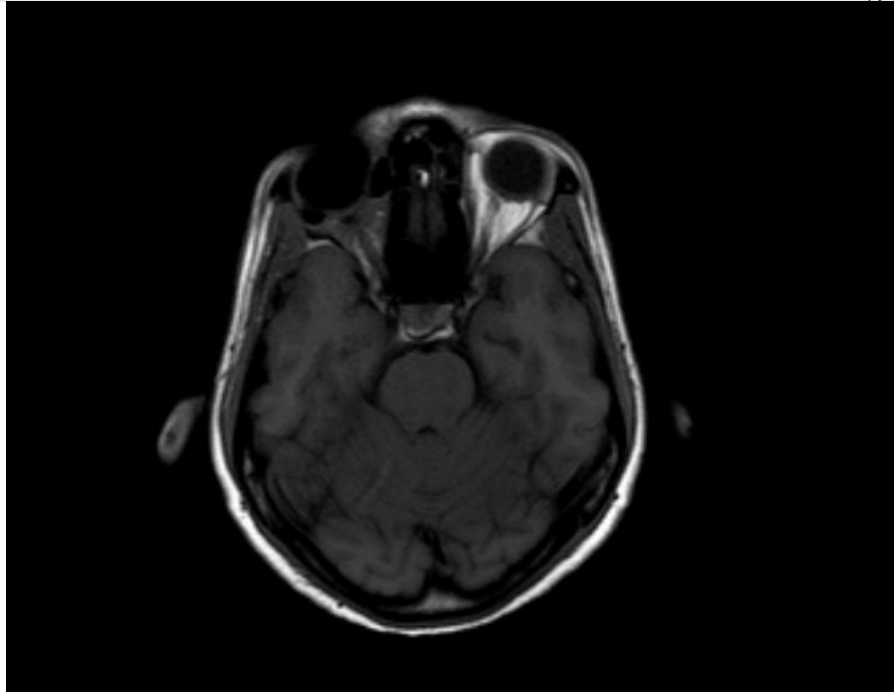


Figure 1: Mri Image T1 Se

Discussion

Adenoid cystic carcinoma (ACC) is the most common malignant tumor of the lacrimal gland and shows bimodal distribution with peak incidences in the second and fourth decades of life with no apparent sex predilection.[10] Patients with ACC usually complain of periocular pain, mild ptosis, and proptosis, along with downward and inward displacement of the globe. Pain is the predominant symptom due to perineural invasion and bony infiltration by the tumor. The tumor usually extends into the posterior orbit because of its capacity to infiltrate and its lack of true encapsulation. Computed tomography (CT) reveals a globular lacrimal gland mass with irregular borders, bony erosion, bone destruction and soft tissue calcification. Contiguous tumor extension toward the medial orbit, apex and the temporalis fossa is typical of an adenoid cystic carcinoma. Posterior tumor extension toward the superior orbital fissure secondary to retrograde tracking along the lacrimal nerve is another well-recognized aggressive behavior of this malignancy. On USG, it appear as a hard irregular mass with medium to high reflectivity. Five histopathologic subtypes have been identified: cribriform (Swiss cheese), sclerosing, basaloid, comedocarcinoma, and tubular (ductal). Cribriform pattern is associated with low tumor grade and better prognosis.² Young patient usually have this subtype [2]. Basaloid pattern connotes a worse prognosis. [3]. Controversy remains regarding the optimal local therapy ranging from local surgical approaches to a radical multidisciplinary intervention. Most widely used approach is orbital exenteration with or without removal of the contiguous bone, followed by external beam radiation therapy with or without chemotherapy. Despite extensive surgery and radiation therapy, the survival outcome for these patients remains dismal.[11] Local recurrence is common, seen in about 50% of patients within two years,[9ss] with soft tissues or orbital bone as the most frequent sites. Bone and lung are common foci of distant metastases .[11]

References:

1. Shields JA, Bakewell B, Augsburger JJ, Flanagan JC: (1984),. Classification and incidence of space-occupying lesions of the orbit: a survey of 645 biopsies. *Arch Ophthalmol*; 102:1606–1611.
2. Reese AB: (1971),.Expanding lesions of the orbit. Bowman Lecture. *Trans Ophthalmol Soc UK*; 91:85–104.
3. Kennedy RE: (1984),.An evaluation of 820 orbital cases. *Trans Am Ophthalmol Soc*; 82:134–157.
4. Reese AB (1956),.The treatment of expanding lesions of the orbit: with particular regard to those arising in the lacrimal gland. The Seventh Arthur J Bedell Lecture. *Am J Ophthalmol* ; 41:3–11.
5. Font RL, Gamel JW: (1980),.Adenoid cystic carcinoma of the lacrimal gland: a clinicopathologic study of 79 cases. In: Nicholson DH, ed. *Ocular pathology update*. New York: Mason:271–275.
6. Goder GJ: Tumours of the lacrimal gland. *Orbit* 1982; 1:91–96.
7. Rootman J: (1988),.Diseases of the orbit: a multidisciplinary approach. Philadelphia: JB Lippincott; 384–405.
8. Henderson JW, Campell RJs, Farrow GM, Garrity JA: (1994),.Orbital tumors. 3rd edn. New York: Raven Press Ltd.;323–342.
9. Jakobiec FA, Font RL: Orbit. In: Spencer WH, ed. (1986),.Ophthalmic pathology: an atlas and textbook. 3rd edn. Philadelphia: WB Saunders:2496–2525.
10. Wright JE: (1982),.Factors affecting the survival of patients with lacrimal gland tumours. *Can J Ophthalmol* 1982; 17:3–9.
11. Lee DA, Campbell RJ, Waller RR, et al: (1985),.A clinicopathologic study of primary adenoid cystic carcinoma of the lacrimal gland. *Ophthalmology*; 92:128–134.



This work is licensed under Creative Commons Attribution 4.0 License

To Submit Your Article Click Here: **Submit Manuscript**

DOI: [10.31579/2692-9562/100](https://doi.org/10.31579/2692-9562/100)

Ready to submit your research? Choose Auctores and benefit from:

- fast, convenient online submission
- rigorous peer review by experienced research in your field
- rapid publication on acceptance
- authors retain copyrights
- unique DOI for all articles
- immediate, unrestricted online access

At Auctores, research is always in progress.

Learn more <https://www.auctoresonline.org/journals/journal-of-clinical-otorhinolaryngology>