

## Aortic Subvalvular Stenosis in Adults: A Clinical Case

Gutenberg Navarro-Zambrano \*, Felipe Santibáñez-Escobar, Humberto J. Martínez-Hernández, Ricardo G. Mero-Vélez, Mauricio Soule-Egea

Department of Cardiothoracic Surgery, National Institute of Cardiology Ignacio Chavez, Mexico City, Mexico.

**\*Corresponding Author:** Gutenberg Navarro-Zambrano. Department of Cardiothoracic Surgery. Instituto Nacional de Cardiología Ignacio Chávez. Vasco de Quiroga, Belisario Domínguez Sección 16, Mexico City, Mexico

**Received date:** August 30, 2023; **Accepted date:** September 10, 2023; **Published date:** September 17, 2023

**Citation:** Gutenberg N. Zambrano, Felipe S. Escobar, Humberto J. Martínez-Hernández, Ricardo G. Mero-Vélez, Mauricio S. Egea, (2023), Aortic Subvalvular Stenosis in Adults: A Clinical Case, *J Thoracic Disease and Cardiothoracic Surgery*, 4(4); DOI:10.31579/2693-2156/062

**Copyright:** © 2023, Gutenberg Navarro-Zambrano. This is an open access article distributed under the Creative Commons Attribution License, which permits unrestricted use, distribution, and reproduction in any medium, provided the original work is properly cited.

### Abstract

We present the clinical case of a 55-year-old patient, with deterioration of her functional class, subvalvular aortic stenosis caused by the presence of a subvalvular aortic ridge was diagnosed. The definitive treatment was surgical resection with preservation of the aortic valve, which ensures a satisfactory long-term post-surgical result. In addition, a brief bibliographic review of the disease is carried out.

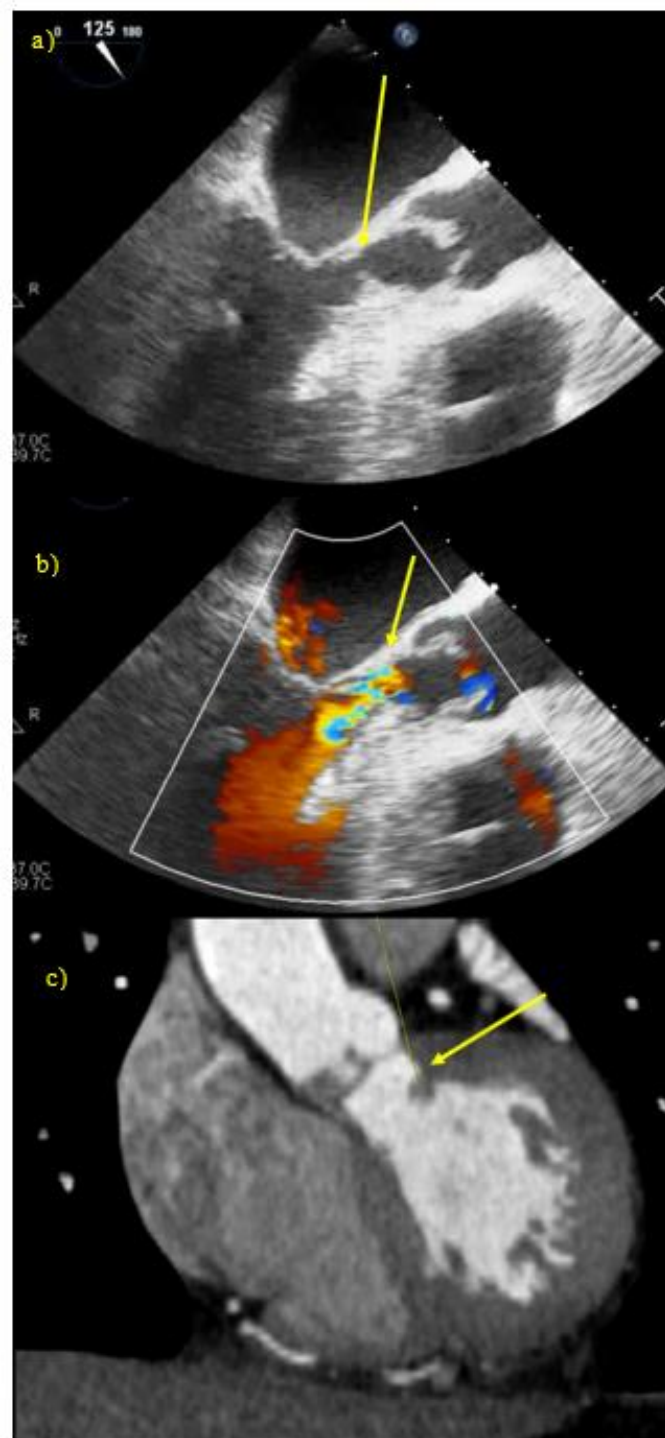
**Keywords:** aortic stenosis; aortic subvalvular stenosis; aortic subvalvular ridge

### Introduction

Aortic subvalvular stenosis, also known as subaortic stenosis, is infrequent in adults, although more frequent in males. The etiology of this pathology is unclear and its clinical presentation is variable.

It accounts for 10-20% of obstructions of the left ventricle outflow tract, with a prevalence of up to 6.5% of congenital cardiopathies in adults [1]. It may present itself as an isolated lesion in 50% of cases, along with other congenital malformations (interventricular communication, bivalve aorta, aortic coarctation, persistent ductus arteriosus and pulmonary stenosis) [2]. We present here the case of a female 55-year-old patient with a personal history of hypertension and dyslipidemia, who sustained 4 months of functional class deterioration with dyspnea on moderate exertion typical facies; synchronic, symmetric carotid pulses were visible with palpable thrill, and systolic murmur at auscultation. The thorax examination revealed the presence of precordium with apex beat; auscultation in aortic focus presented II/IV expulsive murmur extending to the suprasternal and supraclavicular notch, peripheral, symmetric

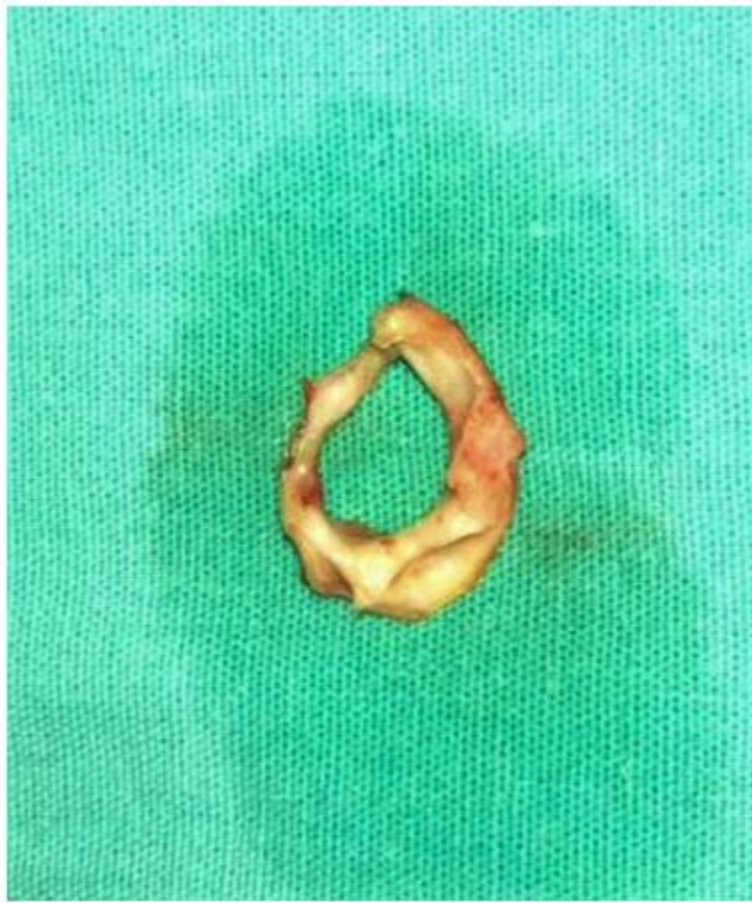pulses of reduced intensity. Laboratory results were normal. Electrocardiographic findings were sinus rhythm, heart rate of 73 bpm, ++P wave, v1 0.1mv 80 ms, PR 160 ms, QRs 90 ms, QRS axis 0 degrees in horizontal position, levorotated with no ischemic lesion data. Transesophageal echocardiogram reported mild tricuspid insufficiency, dilated left atrium, mild mitral insufficiency, left ventricle hypertrophy with a LVEF of 62%, trivalve aortic valve and outflow tract that increased after minor efforts and accompanied obstruction by a 0.93 cm<sup>2</sup> subvalvular aortic ridge by oppressive precordial pain during physical activity for less than 5 minutes that improved with rest. During 20 prior to hospitalization the patient continued to present dyspnea, chest pain and a syncope episode that lasted less than 1 minute. Physical exploration revealed no particular signs or (Figure 1). The coronary angio CT showed the presence of a subvalvular aortic ridge, creating a valvular area of 0.98 cm<sup>2</sup>, and accessory mitral tissue with a 0.68 cm<sup>2</sup> reduction of the left ventricle outflow tract (Figure 1).



**Figure 1:** Transesophageal echocardiography: A) Aortic subvalvular ridge with aortic outflow obstruction; aortic ring 0.93 cm. B) Doppler: aortic subvalvular ridge is observed creating stenosis. C) Thorax angio CT: evidence of aortic subvalvular ridge with a valvular area of 0.98 sq. cm, accessory mitral tissue, reduction of left ventricle outflow tract of 0.68 cm<sup>2</sup>.

With these findings we established the diagnosis of “subvalvular aortic stenosis”, for which reason it was decided to proceed to surgical treatment by resection of the subaortic ridge with preservation of the aortic valve by median sternotomy. The procedure was performed with a clamping time

of 46 minutes and extracorporeal circulation time of 59 minutes. Findings were the following: trivalve aortic valve with normal appearance veils, adequate coaptation and membranous subvalvular aortic ridge (Figure 2).



**Figure 2:** Surgical treatment: macroscopic view of aortic subvalvular ridge following surgical resection.

The patient had a favorable evolution with extubation at 12 hours, hemodynamically requiring no vasopressor or inotropic support in sinus rhythm; thoracic drains were removed at 48 hours, and discharge from the intensive care unit took place on day 2 post-op. Transthoracic ultrasound showed preserved LVEF with no data of subaortic gradients fibromuscular collar, abnormal connections of the mitral valve, and occasionally accessory tissue of the endocardial cushion [3]. Clinically, they remain asymptomatic for long periods in the form of silent disease in children, and in most cases the diagnosis is reached as a result of studies for other cardiopathies; symptoms are related directly with the degree of obstruction and start in moderate-severe or severe stages of the disease. Patients may present dyspnea, dizziness, precordial pain and syncope. Cases of hemodynamic progression in adult age are scarce [4,5]. In the physical examination a notable finding is a systolic ejective murmur that is more audible at the level of the left parasternal line. The diagnosis is confirmed with echocardiography, which shows the anatomy of the subaortic lesion as well as its dimensions, function of the left ventricle, and no aortic valvular insufficiency. The patient was mitral-aortic valve integrity, the degree of involvement discharged from hospital at 6 days of hospitalization without complications. Aortic subvalvular stenosis is defined as an obstruction of the left ventricle outflow located under the aortic valve; this may be induced by fixed stenosis or have a dynamic component, mainly due to the genetic hypertrophic cardiomyopathy (previously known as idiopathic hypertrophic subaortic stenosis) [1]. Most of these cases are considered as acquired of the left ventricle outflow tract, the degree of left ventricular hypertrophy and poststenotic aortic dilatation. Further, associated congenital lesions and non-obstructive membranes may be identified. Thin fibrous membranes are typically found close to the junction of the aortic root with the septum. The angle

between the outlet of the aorta and the long axis of the interventricular septum has been found by echocardiography to have a predictive value in the development of aortic subvalvular stenosis [6]. Lesions due to their evolution and progress in time. A hypothesis regarding its genesis has been proposed, based on the fact that a structural distortion of the left ventricle outflow tract produces turbulence and mechanic stress that in turn lead to cell proliferation with thickening, fibrosis and tissue scarring. Aortic subvalvular stenosis presents different varieties: membranous (the most common lesion), Surgical correction of the obstruction, which can be from the exeresis of the membrane or the extensive surgical resection of the ring with or without myomectomy, seems to be the effective treatment for aortic subvalvular stenosis; however, reported recurrence rates have been of up to 55% of cases, especially when early intervention is performed, requiring intervention in up to 30% of patients [6,7].

## References

1. Oliver J, González A, Gallego P. Discrete subaortic stenosis in adults: increased prevalence and slow rate of progression of the obstruction and aortic regurgitation. *J Am Coll Cardiol.* 2001; 38:835–842.
2. Soca G, Dayan V, León M, Domínguez E. Resección de válvula mitral normofuncionante para alivio de estenosis subvalvular aórtica residual. Un recurso a tener en cuenta y utilidad del ETE intraoperatorio. *Rev UrugCardiol.* 2017; 32.
3. Huan Z. An Anomalous Muscle Band Resulting in Severe Subaortic Stenosis in an Adult. *J Card Surg.* 2013; 28:503-505.
4. Van der Linde D, Takkenberg J, Rizopoulos D, Heuvelman H, Budts W, Van Dijk AP, et al. Natural history of discrete

- subaortic stenosis in adults: a multicentre study. *Eur Heart J.* 2013; 34:1548-1556.
5. Aroca A, Polo L, González A, Rey J, Greco R, et al. Estenosis congénita a la salida del ventrículo izquierdo. Técnicas y resultados. *CirCardiov.* 2014; 21:111–119.
  6. Theocharis P, Viola N, Papamichael ND, Markku K, Bharuc T. Echocardiographic predictors of reoperation for subaortic stenosis in children and adults. *European Journal of Cardio-Thoracic Surgery.* 2019; 56:549-556.
  7. Mulla S, Siddiqui WJ. Subaortic Stenosis. *StatPearls.* 2019.



This work is licensed under Creative Commons Attribution 4.0 License

To Submit Your Article Click Here: [Submit Manuscript](#)

DOI: [10.31579/2693-2156/060](https://doi.org/10.31579/2693-2156/060)

**Ready to submit your research? Choose Auctores and benefit from:**

- ❖ fast, convenient online submission
- ❖ rigorous peer review by experienced research in your field
- ❖ rapid publication on acceptance
- ❖ authors retain copyrights
- ❖ unique DOI for all articles
- ❖ immediate, unrestricted online access

At Auctores, research is always in progress.

Learn more <http://www.auctoresonline.org/journals/journal-of-thoracic-disease-and-cardiothoracic-surgery>