

# Veno-Venous Coiling as A Strategy to Wean Extracorporeal Membrane Oxygenator Post Adult Fontan Completion

Charlotte C. Frost <sup>1\*</sup>, Vinod Sharma <sup>1</sup>, Dale Murdoch <sup>2</sup>, Douglas Wall <sup>1</sup>

<sup>1</sup> Department of Cardiothoracic Surgery, Gold Coast University Hospital, 1 Hospital Blvd, Southport, QLD, Australia.

<sup>2</sup> Department of Interventional Cardiology, The Prince Charles Hospital, 627 Rode Road Chermside, QLD, Australia.

**\*Corresponding Author:** Charlotte C. Frost, Department of Cardiothoracic Surgery, Gold Coast University Hospital, 1 Hospital Blvd, Southport, QLD, Australia.

**Received Date:** October 10, 2023 | **Accepted Date:** October 27, 2023 | **Published Date:** November 08, 2023

**Citation:** Charlotte C. Frost, Sharma V., Murdoch D., Wall D., (2023), Veno-Venous Coiling as A Strategy to Wean Extracorporeal Membrane Oxygenator Post Adult Fontan Completion, *International Journal of Clinical Case Reports and Reviews*, 15(1);

**DOI:**10.31579/2690-4861/345

**Copyright:** © 2023, Charlotte C. Frost. This is an open-access article distributed under the terms of the Creative Commons Attribution License, which permits unrestricted use, distribution, and reproduction in any medium, provided the original author and source are credited.

## Abstract:

We discuss a case of veno-venous collaterals in a patient with Fontan circulation post complex redo-surgery, which impeded veno-venous extracorporeal membrane oxygenation (VV-ECMO) weaning.

A 31-year-old male, born with complex congenital heart disease (D-transposition of the great vessels, tricuspid atresia, aortic coarctation, ventricular septal defect, and hypoplastic right ventricle) with single ventricle physiology. The patient underwent multiple cardiac surgeries leading to Fontan completion. He subsequently developed significant aortic regurgitation with progressive left ventricular dilatation requiring multiple readmissions for congestive heart failure. Despite maximal medical optimisation he remained symptomatic and was offered further surgery. Complex 6th redo-operation with aortic valve replacement, modification to intracardiac fenestrated Fontan and insertion of intra-aortic balloon pump was performed. At 72 hours postoperative, VV-ECMO was required for refractory hypoxia. Right heart catheterisation was performed with coiling of two large fistulous venous connections. Post-coiling saturations improved from 92% to 98%. The patient was successfully weaned from VV-ECMO and decannulated the following day. This case demonstrates successful embolisation for veno-venous collaterals causing significant right to left shunt and hypoxia, in a patient with Fontan circulation.

**Key words:** fontan circulation; venous collaterals; coiling; extracorporeal membrane oxygenation; ECMO; ACHD; adult congenital heart disease

## Abbreviations:

**ACHD** – Adult Congenital Heart Disease

**LVEDD** – Left ventricular end diastolic volume

**VV-ECMO** – veno-venous extracorporeal membrane oxygenation

## Introduction

The Fontan procedure, a palliation procedure, has been successfully performed for over 30 years. These patients are now living into adulthood and developing long-term complications of single ventricle driven physiology. Veno-venous collateral formation is a known complication, with debated aetiology. The current theory is that decompressing collaterals form in response to systemic venous hypertension (1-3). The benefit of coiling chronic collateral vessels provides no advantage to these patients (1). We discuss a patient with significant venous collaterals identified postoperatively causing refractory hypoxia.

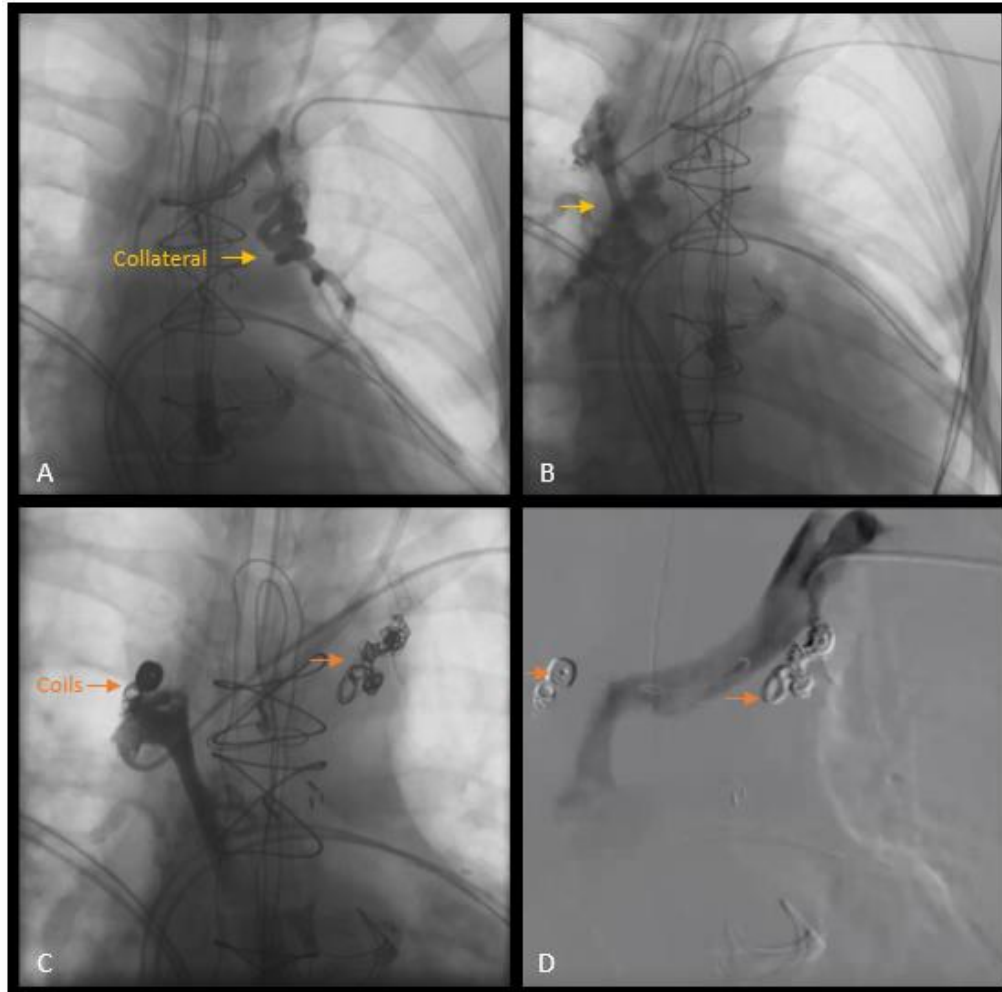
## Case Presentation:

A 31-year-old male, presented with heart failure. He was born with complex congenital heart disease and single ventricle physiology (D-transposition of the great vessels, tricuspid atresia, aortic coarctation, ventricular septal defect, and hypoplastic right ventricle). The patient had multiple cardiac surgeries as a child (two coarctation repairs, Damus-Kaye-Stansel procedure and Glenn shunt) leading to Fontan completion. He progressively developed severe symptomatic aortic regurgitation, left ventricular dilation and heart failure requiring multiple readmissions. A holter monitor demonstrated episodic atrial tachycardia. Preoperative CT demonstrated no collateral vessels and right heart catheter showed normal pulmonary pressure and no venous collaterals. Transthoracic echocardiogram demonstrated dilated left ventricle (LVEDD 70mm) EF 47%, neo-aortic valve with 3-4/4 regurgitation, 2-3/4 mitral regurgitation, hypoplastic right ventricle with tricuspid atresia, and neo-pulmonary

valve 2/4 regurgitation. Despite medical optimisation he remained symptomatic. Redo operation was performed with 6th sternotomy, neo-aortic valve replacement, central Alfieri type plication of the neo-pulmonary valve, modification to intracardiac fenestrated Fontan and insertion of intra-aortic balloon pump. The patient returned to intensive care on modest inotropes and acceptable haemodynamics.

At 72 hours postoperative, VV-ECMO was required for worsening refractory hypoxia. Despite VV-ECMO flow of 3.33L, sweep gas flow of 5L/min, FiO<sub>2</sub> 70 and ventilator settings of FiO<sub>2</sub> 60, PEEP 7cmH<sub>2</sub>O and tidal volumes of 430ml, saturations remained at 91%. Blood gas demonstrated pH 7.51, O<sub>2</sub> 62mmHg and pCO<sub>2</sub> 35mmHg. Postoperative CT demonstrated venous collaterals, and a right heart catheter was

performed to confirm. The tight heart catheterisation demonstrating two large fistulous venous connections from the innominate vein to the right and left superior pulmonary veins (Figure 1A, B) with significant right to left shunt Q<sub>p</sub>: Q<sub>s</sub> 1.5:1. Following multidisciplinary discussion, the two collateral vessels were coiled (Figure 1C, D) with multiple retrievable Boston Scientific Interlock™ coils 3 x (6mm x 10cm), 2 x (6mm x 20cm), 8mm x 20cm, 10mm x 30cm and 2 x (10mm x 50cm). Saturations rapidly improved from 92% to 98% and arterial blood gas demonstrated pH 7.41, pO<sub>2</sub> 69mmHg and pCO<sub>2</sub> 38mmHg. VV-ECMO was weaned rapidly post coiling with decannulation in under 24 hours. The patient is currently stable in medically managed compensated heart failure 4 years postoperatively.



**Figure 1:** Right heart catheter demonstrating significant veno-venous connections from the innominate vein to pulmonary veins. A) Collateral to the left pulmonary vein. B) Collateral to right pulmonary vein. C) Multiple Boston Scientific Interlock™ coils. D) Patent Innominate vein post-coiling with no residual fistulous venous connections.

## Discussion:

Advances in the diagnosis, medical management and surgical interventions for congenital heart disease has improved survival into adulthood for many patients (4). Adult congenital heart disease (ACHD) patients have unique anatomy and complex physiology that is not cured by current interventions. These patients require highly specialized medical and surgical services with experience in ACHD, including adult congenital cardiology, interventional cardiology, cardiac anesthesiology, intensive care, perfusionist, ECMO services, and congenital cardiac surgeons. This breadth of knowledge, with multidisciplinary teamwork was critical for the successful management of our patient.

Veno-venous collaterals are a known phenomenon in patients with a Fontan circulation (1). The benefits of coiling chronically present veno-venous collaterals are debated, as not all venous collaterals cause shunting and result in hypoxia. The indication for collateral coiling is often if they are large and cause resting hypoxia (3). However, when to intervene and how many collaterals to coil is unclear. This patient had no evidence of collaterals on preoperative investigation or visible intraoperatively. We believe the patient had collaterals present that were dormant preoperatively. They opened creating significant shunting due to an acute change in pathophysiology postoperatively. Significant opening of collateral vessels postoperatively caused refractory hypoxia in our patient.

These were rapidly identified and coiled, leading to successful VV-ECMO weaning with correction of hypoxia.

### Conclusions:

This case demonstrates successful weaning from VV-ECMO using embolisation for veno-venous collaterals with significant right to left shunt and hypoxia, in a patient with Fontan circulation. Acute refractory decompensation rapidly resolved following embolisation. Venous collateral coiling should be considered in the context of clinical condition and hypoxia. A low threshold is required to investigate for collateral vessels even when they are not present in the preoperative phase.

### Funding:

This work did not receive any specific grant from a funding agency.

### Conflict of interest:

none declared.

### Author contributions:

**Charlotte C. Frost:** Manuscript writing & editing.

**Vinod Sharma:** Manuscript editing.

**Dale Murdoch:** Manuscript editing.

**Douglas Wall:** Manuscript editing.

### References:

1. Poterucha JT, Johnson JN, Taggart NW, Cabalka AK, Hagler DJ, et al. (2015). Embolization of Venovenous Collaterals after the Fontan Operation Is Associated with Decreased Survival. *Congenit Heart Dis.* 10(5): E230-236.
2. Heinemann M, Breuer J, Steger V, Steil E, Sieverding L, et al. (2001). Incidence and impact of systemic venous collateral development after Glenn and Fontan procedures. *Thorac Cardiovasc Surg.* 49(3):172-178.
3. Sugiyama H, Yoo SJ, Williams W, Benson LN. (2003). Characterization and treatment of systemic venous to pulmonary venous collaterals seen after the Fontan operation. *Cardiol Young.* 13(5):424-430.
4. Stout KK, Daniels CJ, Aboulhosn JA, Bozkurt B, Broberg CS, et al. (2019). 2018 AHA/ACC Guideline for the Management of Adults with Congenital Heart Disease: A Report of the American College of Cardiology/American Heart Association Task Force on Clinical Practice Guidelines. *J Am Coll Cardiol.* 73(12): e81-e192.



This work is licensed under Creative Commons Attribution 4.0 License

To Submit Your Article Click Here:

[Submit Manuscript](#)

DOI:10.31579/2690-4861/345

#### Ready to submit your research? Choose Auctores and benefit from:

- fast, convenient online submission
- rigorous peer review by experienced research in your field
- rapid publication on acceptance
- authors retain copyrights
- unique DOI for all articles
- immediate, unrestricted online access

At Auctores, research is always in progress.

Learn more <https://auctoresonline.org/journals/international-journal-of-clinical-case-reports-and-reviews>