

Hydatid Cyst of the Heart: About a Series

M.Abelbaki *, H.Benalikhoudja, B Djafer, M Djenas, Mo Amrane, E. Boudiaf

Cardiovascular Surgery Department EHS M.A. MAOUCHE El Biar Algiers

*Corresponding Author: M. Abdelbaki, Cardiovascular Surgery Department Ehs M.A. Maouche El Biar Algiers.

Received Date: October 13, 2023; Accepted Date: October 23, 2023; Published Date: October 31, 2023

Citation: M.Abelbaki, H.Benalikhoudja, B Djafer, M Djenas, Mo Amrane, E. Boudiaf (2023), Hydatid cyst of the heart: About a series. *J. Clinical Cardiology and Cardiovascular Interventions*, 6(7); DOI:10.31579/2641-0419/337

Copyright: © 2023, M. Abdelbaki. This is an open-access article distributed under the terms of the Creative Commons Attribution License, which permits unrestricted use, distribution, and reproduction in any medium, provided the original author and source are credited.

Abstract

From January 1996 to December 2019, 16 patients were hospitalized in the cardiac surgery department and operated on for hydatid cyst of the heart. The majority were female. The average age was 29 years old. 25% of patients had an associated extracardiac location.

All patients underwent open heart surgery.

The purpose of this study is to report our experience, assess the results and compare them with data from the literature. Doppler echocardiography and MRI angiography allowed early and precise diagnosis. The prognosis is good except in the forms Complicated. Surgery remains the only therapeutic alternative. Anti-parasitic medical treatment is a complement to surgery advocated by certain teams.

Keywords: cardiac echinococcosis; pulmonary embolism; cardiac surgery; doppler echocardiography; extracorporeal circulation; albendazole

Introduction

During a period of 11 years, 16 patients were operated on in the hydatid cyst of the heart department. These are patients who have been entrusted to us by the medical or cardiology services. The mode of revelation of the disease was either rhythm disturbances, conduction disturbances or chest pain. All patients underwent an electrocardiogram, a chest x-ray, an echocardiogram and sometimes a chest CT angiogram. An extension assessment was carried out in all patients in search of other locations. All patients underwent open heart surgery under extracorporeal circulation. The postoperative results were satisfactory, however we regret two death.

During a period of 11 years, 16 patients were operated on in the hydatid cyst of the heart department. These are patients who have been entrusted to us by the medical or cardiology services. The mode of revelation of the disease was either rhythm disturbances, conduction disturbances or chest pain. All patients underwent an electrocardiogram, a chest x-ray, an echocardiogram and sometimes a chest CT angiogram. An extension assessment was carried out in all patients in search of other locations. All patients underwent open heart surgery under extracorporeal circulation. The postoperative results were satisfactory, however we regret two death.

Methods :

From June 1996 to December 2019, 16 patients were operated on in the department for hydatid cyst of the heart. The majority of patients were female with a F/M ratio of 12/4. The average age of the patients was 29 years with extremes of 11 and 60 years.

Clinically:

During a period of 11 years, 16 patients were operated on in the hydatid cyst of the heart department. These are patients who have been entrusted to us by the medical or cardiology services. The mode of revelation of the disease was either rhythm disturbances, conduction disturbances or chest pain. All patients underwent an electrocardiogram, a chest x-ray, an echocardiogram and sometimes a chest CT angiogram. An extension assessment was carried out in all patients in search of other locations. All patients underwent open heart surgery under extracorporeal circulation. The postoperative results were satisfactory, however we regret two death.

Methods :

From June 1996 to December 2019, 16 patients were operated on in the department for hydatid cyst of the heart.

The majority of patients were female with a F/M ratio of 12/4. The average age of the patients was 29 years with extremes of 11 and 60 years.

Clinically:

- the revealing complications :

Tachycardia	04
Atrio ventricular block	04
Chest pain	02

- The accidental discovery made during the extension assessment: 05 patients

Liver hydatid cyst	04
Brain hydatid cyst	01

The electrocardiogram :

Liver hydatid cyst	04
Brain hydatid cyst	01

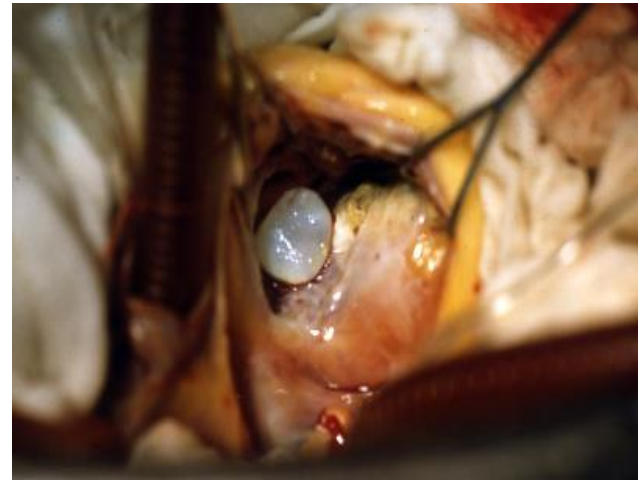The chest x-ray was normal for 14 patients; 02 patients presented cardiomegaly.

An echocardiographer was carried out in all patients as well as a thoracic angiogram, they allowed a topographical diagnosis, visualize the number of cysts, assess the volume and perform an extension assessment.

Chest angiogram Echocardiogram

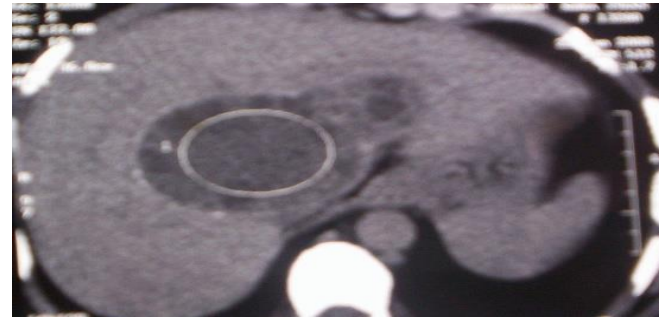
The locations found in our study:

Interventricular septum	09
Wall of the left ventricle	06
Sinus of Theile	01



Cyst of interventricular septum

All patients underwent an extension assessment to look for other locations, in particular an abdominal ultrasound. An abdominal CT angiogram was performed in one patient because the abdominal ultrasound was not informative.



Abdominal CT angiogram

All our patients underwent open heart surgery under extracorporeal circulation and aortic clamping. The approach was a Median Sternotomy. After protecting the operating field with compresses soaked in hypertonic serum, the treatment consisted of a puncture, aspiration of the cyst, sterilization of the parasite with hypertonic serum, resection of the pericyst and padding of the residual cavity.

The surgical outcomes were satisfactory for the majority of patients. However, we deplore two postoperative deaths due to myocardial incompetence and one death in the 4th month postoperatively. This was the patient who had an associated cerebral localization.

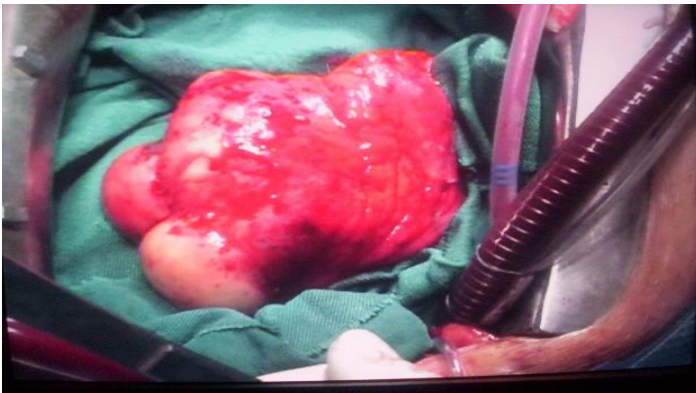Discussion :

Hydatid cyst is a rare condition [1,2]. In certain regions, hydatidosis remains a public health problem [3], particularly in our country [4]. the thoracic locations are dominated for some by the lung [5] while for others, it is the liver (70%) and the lung represents only 20%. cardiac locations are of the order of 0.5% to 2% [6].

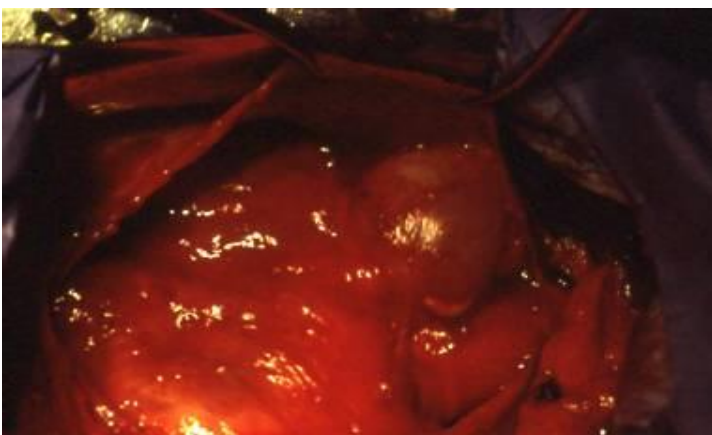
It is a condition of young adults since the average age is between 25 and 30 years [1, 2, 3,7], it is the same for our series.

We note a clear female predominance [1, 3, 7,8], it is also found in our study.

The diagnosis of hydatid cyst is difficult because the clinical symptoms are non-specific and highly variable. [9]. Claque signs appear either when there is a complication: ruptured septal cyst in the pulmonary artery [2,10], or rhythm or conduction disturbances as in our series, or



Left ventricular lateral wall cyst



Sinus of Theile cyst

as part of the assessment of extension of hydatid disease [1,8,11]. In our work, the diagnosis of hydatid cyst of the heart was made as part of the extension assessment in 25% of patients. It should also be looked for in any cardiac mass, especially in hydatid endemic areas [12]. Chest radiography only detects bulky forms responsible for cardiomegaly or possible calcifications [6].

In our study, as in the literature, most patients had a normal chest x-ray.

The electrocardiogram was carried out in all patients. It allows us to assess the impact of the cyst on the cardiac cavities [13].

Transthoracic echocardiography is the first-line examination. It often makes it possible to make the diagnosis and look for other locations [1,6]. Transesophageal echocardiography is the examination of choice for diagnosis [7].

CT and MRI allow morphological and extension assessment [6,14]. The interest of MRI finds its place in complicated cases and in cases of discrepancy between the ultrasound data and the scanner [13].

In our work, CT angiography was only performed once because the diagnosis could not be made with echocardiography.

The growth of the hydatid cyst is slow and asymptomatic, which explains an often late diagnosis at the stage of complications, such as compression or rarely rupture leading to cerebral [4], pulmonary [2] or pulmonary embolisms [10,15].

In the pericardium, it causes tamponade [16].

Cardiac localization is rare and mainly comes from the coronary circulation.

Intracardiac or pericardial forms are exceptional, while involvement of the free wall of the left ventricle (50 to 60% of cardiac locations) is the most common due to its rich parietal vascularization [6, 7,13].

In our series it is 37%. In the literature, localization at the interventricular septum level represents 5 to 20% of myocardial damage [13,17,18]. In our series, it is 56% and therefore more common than the location of the free wall of the right ventricle. This septal damage is the cause of conduction disorders [6,19].

The location in the right heart is rare [20,21], we did not encounter it in our study.

As for all our patients, the treatment of hydatid cyst is surgical [1]. The surgery is carried out under extracorporeal circulation [2] and aortic clamping [11]. Sternotomy is the approach used [8].

Sterilization of the parasite was carried out using hypertonic saline [22]. The residual cavity was closed in all cases [3,22] thus reducing the risk of recurrence. Clamping of the pulmonary artery is necessary during resection to avoid pulmonary dissemination [3].

Antiparasitic medical treatment is an adjunctive post-operative treatment to avoid recurrences, or in patients at a complicated stage and where surgical treatment is contraindicated [1,11, 23,24]. In our series, patients did not benefit from antiparasitic medical treatment.

The postoperative results are good, we had to deplore 2 deaths due to myocardial incompetence because the patients were operated on at the stage of heart failure. The same results are found in the literature [2, 3, 8, 22,25].

We did not observe any post-operative complications, even though the literature reports conduction disorders in cysts of the interventricular septum requiring the insertion of a pacemaker [8,22]. We did not observe any distant recurrence [2,22].

Conclusion :

Hydatid cyst of the heart is a rare condition compared to other locations such as the liver and lung. It is always necessary to look for a cardiac location when there is another location, particularly in endemic areas. The diagnosis is easy with echocardiography and especially CT.

Surgical treatment under extracorporeal circulation is the only alternative. Antiparasitic medical treatment is considered by some to be a complement to surgical treatment. The prognosis is good if patients are operated on early before the complication stage.

Bibliography

1. Kabbani SS, Ramadan A, Kabbani L, Sandouk A, Nabhani F, Jamil H. Surgical experience with cardiac echinococcosis. *Asian Cardiovascular Thorac Ann.* 2007 Oct; 15(5):422-426
2. S. Jerbi, N. Romdhan, A. Tarmiza, C. Kortas, S. Mlika, N. Khelil, M. Belghitha, F. Limayema Emboligenous hydatid cyst of the right heart. *Annales de Cardiologie et d'Angéiologie*
3. Volume 57, February 2008, Pages 62-65.
4. Orhan G, Ozay B, Tartan Z, Kurc E, Ketenci B, Sargin M, Demirtas MM, Aykut SA. Surgery of cardiac hydatid cysts. An experience of 39 years *Ann Cardiol Angeiol (Paris).* 2008 Feb; 57(1):58-61.
5. Asri F, Tazi I, Maaroufi K, El Moudden A, Ghannane H, Ait Benali S. Cerebral hydatid cyst and psychiatric disorders. Two cases] *Encephale.* 2007 Mar-Apr; 33(2):216-219
6. Grahiri Hedia (1) ; Mohamed Anis Khouadja (1) ; Abouda Maher (1) ; Kyste hydatique du coeur et des vaisseaux, 4 observations = Hydatid cyst of the heart and vessels, 4 cases *La Presse médicale* 2005, vol. 34, no2, CAH1, pp. 101-104
7. JBAqu [1], VHuart[1], JMPierrot,[1], BLouail[1], JMGrinda[1], MSapoval[1] et EMousseau[Kyste hydatique du septum interventriculaire du coeur : aspect en scanner multibarrette et en IRM *Journal de Radiologie* Vol 84, N  5 - mai 2003 pp. 614-616.
8. Jerbi S, Kortas C, Dammak S, Hamida N, Aly F, Mlika S, Romdhani N, Limayem F, Ennabli K. Cardio-pericardial hydatid cyst. Report of 19 cases. *Tunis Med.* 2004 Jan; 82 Suppl 1:152-157.
9. Erentuđ V, Bozbuđa N, Kirali K, Mataraci I, Kaymaz C, Balkanay M, Akinci E, Ipek G, Yakut C. Cardiac hydatid cysts: surgical treatment and results. *J Card Surg.* 2004 Jul-Aug; 19(4):358-60
10. Yaliniz H, Tokcan A, Salih OK, Ulus T. Surgical treatment of cardiac hydatid disease: A report of 7 cases. *Tex Heart Inst J.* 2006; 33(3):333-339.
11. Ilic S, Parezanovic V, Djukic M, Kalangos A. Ruptured hydatid cyst of the interventricular septum with acute embolic pulmonary artery complications. *Pediatr Cardiol.* 2008 Jul; 29(4):855-857.
12. Abid A, Ben Omrane S, Kaouel K, Marghli A, Dhiab M, Abid N, Ben Zarkouna S, Khayati A Intracavitary cardiac hydatid cyst. *Cardiovasc Surg.* 2003 Dec; 11(6):521-525
13. Rena O, Garavaglia M, Francini M, Bellora P, Oliaro A, Casadio C. Solitary pericardial hydatid cyst. *J Cardiovasc Surg (Torino).* 2004 Feb; 45(1):77-80.
14. Elhataoui M. (1) ; Charel N. (1) ; Bennis A. (1) ; Tahiri A. (1) ; Chraïbi N. (1) ; Haddani J. (2) ; Mehadjji B. A. Kyste hydatique du coeur : À propos de 10 cas *Archives des maladies du coeur et des vaisseaux* 2006, vol. 99, no1, pp. 19-25

15. Trigano JA, Mourot F, Talmoudi T, Malmejac C, Torresani J, Houel J. Sémiologie du kyste hydatique du coeur. Étude d'une série continue de 13 cas et intérêt du scanner. Arch Mal Coeur 1985;78: 1895-9.
16. Kammoun Ikram (1) ; Benhalima Afef (1) ; Ammar Jamel (2) ; Chine Samira (1) ; Chaabane Olfa (1) ; Zouaoui Walid (1) ; Rebeh Balsam (1) ; Keskes Hend (1) ; Gargouri Sami (1) ; Lefi Abdellatif (1) ; Hamzaoui Agnès (2) ; Kachboura Salem :Embolie pulmonaire hydatique compliquant un kyste hydatique du coeur. A propos d'un cas Tunisie médicale 2004, vol. 82, no8, pp. 777-780
17. Struillou L, Rabaud C, Bischoff N, Preiss MA, May T, Canton P. Complications of cardiac hydatid cyst. 2 cases] Presse Med. 1997 Sep 6; 26(25):1192-1194.
18. Elkouby A, Vaillant A, Comet B, Malmejac C, Houel J. L'hydatidose cardiaque. Revue de la littérature récente à propos d'une expérience de 15 cas. Ann Chir Thorac Cardiovasc 1990; 44:603-610.
19. El Abbassi Skalli A, El Alraoui F, Chikhaoui N, Kadiri R. Kyste hydatique du médiastin. À propos de 2 cas. J Radiol 2000; 81:154-157.
20. Gomez FP, Duran H, Tamames S, Perrote JL, Blames A. Cardiac echinococcosis: clinical picture and complications. Br Heart J 1973; 35:1326-1331
21. Murat V, Qian Z, Guo S, Qiao J. Cardiac and pericardial echinococcosis: report of 15 cases. Asian Cardiovasc Thorac Ann. 2007 Aug;15(4):278-279
22. Tandon S, Darbari A. Hydatid cyst of the right atrium: a rare presentation. Asian Cardiovasc Thorac Ann. 2006 Jun;14(3):e43-44.
23. Miralles A, Bracamonte L, Pavie A, Bors V, Rabago G, Gandjbakhch I, Cabrol C. Cardiac echinococcosis. Surgical treatment and results. J Thorac Cardiovasc Surg. 1994 Jan; 107(1):184-190
24. Bozbuga N, Erentug V, Akinci E, Yakut C. Is surgical therapy the only treatment of choice for cardiac echinococcosis with multiple organ involvement? Interact Cardiovasc Thorac Surg. 2003 Sep; 2(3):367-378.
25. Ozyazicioğlu A, Koçak H, Ceviz M, Balci AY. Surgical treatment of echinococcal cysts of the heart: report of 3 cases. Asian Cardiovasc Thorac Ann. 2002 Mar; 10(1):66-68.
26. Papo I, Ginsberg E, Albreht M, Martinović N, Sokolić J. Surgical treatment of cardiac echinococcosis: report of nine cases. Tex Heart Inst J. 1982 Mar; 9(1):3-9.



This work is licensed under Creative Commons Attribution 4.0 License

To Submit Your Article Click Here:

Submit Manuscript

DOI:10.31579/2641-0419/337

Ready to submit your research? Choose Auctores and benefit from:

- fast, convenient online submission
- rigorous peer review by experienced research in your field
- rapid publication on acceptance
- authors retain copyrights
- unique DOI for all articles
- immediate, unrestricted online access

At Auctores, research is always in progress.

Learn more <https://auctoresonline.org/journals/clinical-cardiology-and-cardiovascular-interventions>

