

Management of Coronary Artery Rupture During Transluminal Coronary Recanalization and Angioplasty in a Case of Chronic Coronary Syndrome

El Abasse Zeine *, Sid M'Hamed Ethmane, El Haj Ahmed NE, Ahmed Ebba

Department of Cardiology, National centre of cardiology (CNC) Nouakchott Mauritania.

*Corresponding Author: El Abasse Zeine, Department of Cardiology, National centre of cardiology (CNC) Nouakchott Mauritania.

Received Date: October 25, 2023; Accepted Date: November 06, 2023; Published Date: November 16, 2023

Citation: M Zeine. El Abasse, Sid M'Hamed Ethmane, El Haj Ahmed NE, Ahmed Ebba (2023), Management of Coronary Artery Rupture During Transluminal Coronary Recanalization and Angioplasty in a Case of Chronic Coronary Syndrome. *J. Clinical Cardiology and Cardiovascular Interventions*, 6(7); DOI:10.31579/2641-0419/340

Copyright: © 2023, El Abasse Zeine. This is an open-access article distributed under the terms of the Creative Commons Attribution License, which permits unrestricted use, distribution, and reproduction in any medium, provided the original author and source are credited.

Abstract

Percutaneous transluminal coronary angioplasty (PTCA) is a widely performed and effective therapy for coronary artery disease. Evolution of the dilatation instruments during the last decade has led to an increased success rate of PTCA and to the development of newer techniques such as recanalization of totally occluded coronary arteries. We report a case of coronary artery recanalization complicated by fatal coronary artery rupture.

Case Report

A 55-year-old woman she presented with clinical symptoms suggestive of progressive angina was admitted to our hospital for the evaluation of exertional angina. High blood pressure being his sole cardiovascular risk factor. He was referred for coronary angiography and possible coronary revascularization. The patient had selective coronary angiography, which exhibited, 80% diameter stenosis of the mid-portion of the LAD. The patient was scheduled for angioplasty the following day with a loading dose of clopidogrel. Direct stenting of the mid LAD was performed with DES and after a control angiography, the stent was found to be under-expanded, a 3 mm balloon (Medtronic Euphora) was advanced over the guidewire in the LAD. The balloon was withdrawn and a control injection was made. This showed patency of the middle segment of the LAD, however with a "no flow" situation and an important extravasation of the contrast medium into the pericardium (Figure. 1). Immediately appreciated. The 2.0 mm balloon was moved 2 mm more proximal and inflated at 3 atm to seal the leak. This was confirmed by contrast injection. The clinical course deteriorated quickly and fatal cardiac arrest ensued, in immediate a filling with a 100ml puncture was performed. Despite resuscitation measures, the patient could not be retrieved.

Keywords: percutaneous transluminal coronary angioplasty; coronary artery perforation; coronary artery rupture

Introduction

In this case report, we expand upon this therapeutic approach for the management of balloon-induced coronary artery rupture with intrapericardial leak. Coronary artery rupture by balloon angioplasty is a relatively rare but often fatal complication during PTCA. This severe form of coronary rupture occurs predominantly with atherectomy or with PTCA of chronic total occlusions (CTO).

Case Report

A 55-year-old woman she presented with clinical symptoms suggestive of progressive angina for the past few months was admitted to our hospital for the evaluation of exertional angina. She had an unremarkable medical history, high blood pressure being his sole cardiovascular risk factor.

Clinical examination on admission revealed stable patient with an arterial pressure of 150/80. The electrocardiogram showed the presence of a negative

anterior T wave. After initial therapy with Aspirin 100 mg, bisoprolol 5 mg, statin and its treatment of hypertension, He was referred for coronary angiography and possible coronary revascularization. The patient had selective coronary angiography, which exhibited, 80% diameter stenosis of the mid-portion of the left anterior descending (LAD) coronary artery. After reviewing the patient's anatomy, it was felt that the LAD were the cause of the patient's clinical syndrome. Intervention was performed. Systemic heparin (5,000 IU) were administered. The patient was scheduled for angioplasty the following day with a loading dose of clopidogrel.

Direct stenting of the mid LAD was performed with a 2.75 mm diameter, 26 mm length Resolute Integrity stent, and after a control angiography, the stent was found to be under-expanded, a 3 mm balloon (Medtronic Euphora) was advanced over the guidewire in the LAD. After two inflations at a maximal pressure of 18 bar, the balloon was withdrawn and a control injection was

made. This showed patency of the middle segment of the LAD, however with a “no flow” situation and an important Extravasation of the contrast medium into the pericardium (Fig. 1). Immediately appreciated. The 2.0 mm balloon was moved 2 mm more proximal and inflated at 3 atm to seal the leak. This was confirmed by contrast injection. A trans-thoracic cardiac echo was performed emergently. The clinical course deteriorated quickly and fatal

cardiac arrest ensued, in immediate a filling with a 100ml puncture was performed. Despite resuscitation measures, the patient could not be retrieved

A total rupture of the vascular wall had occurred 2 cm more distally (Figure. 2).

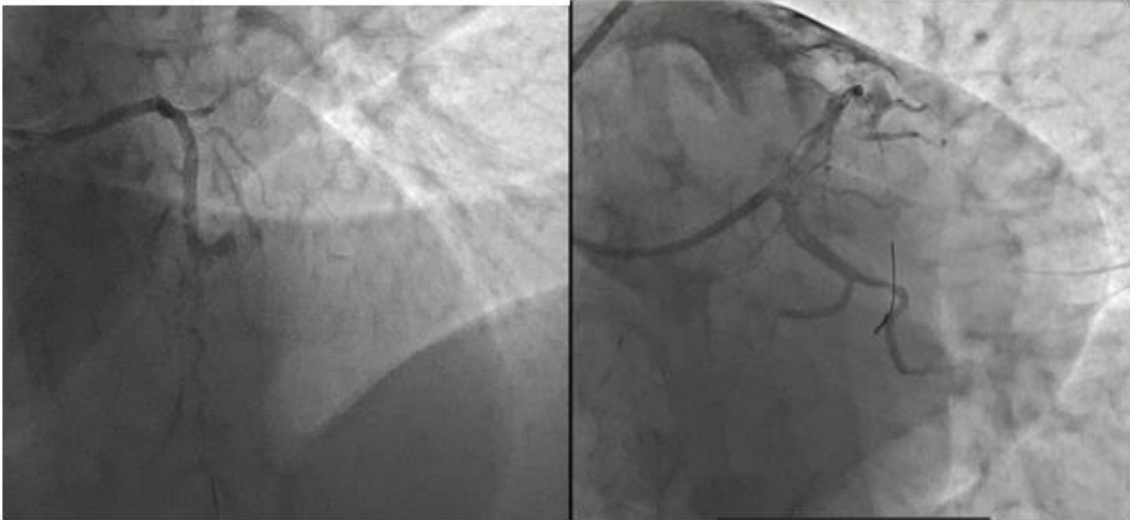


Figure 1: showing a rupture of the middle LAD

Figure 2: Extravasation of the contrast medium into the pericardium

Discussion:

Coronary artery rupture is a relatively uncommon but morbid complication of PCI. This complication can be particularly difficult to treat in the setting of combined anticoagulant (heparin) and antiplatelet therapy with glycoprotein IIb/IIIa inhibitors. Cardiac tamponade and death may result from this complication, even when it is recognized and treated in a timely fashion [1,2]. The key to treatment is the immediate recognition and sealing of the rupture by balloon inflation. If this is done in a timely fashion, in our case we tried to use a balloon but the rupture was wide but in some cases with balloon, the pericardial leak can be minimized, and tamponade can be avoided. Most often, immediate referral for open cardiac surgery is required to ligate the coronary rupture, with or without the need for coronary artery bypass grafting. There are very limited less-invasive solutions to try to deal with the problem of coronary rupture. If the ruptured vessel is large and supplies a substantial myocardial territory, it may be possible to seal the rupture using a covered stent. In addition, the use of covered stents has been associated with a relatively high risk of stent thrombosis and myocardial infarction. In vessels that are too small to be treated with a covered stent, surgery has been the mainstay for treatment of coronary artery rupture. Similarly, surgery is typically the treatment of choice if there is a rupture after a proximal opening of a CTO. For very small, distal perforations, there have been a number of approaches used to seal the coronary leak and avoid surgery. Thrombin [3], gelfoam [4], microcoil embolization [5], and organized thrombus, obtained from the patient's own blood, have all been used successfully to treat these small distal perforations [6]. With only 11 papers between 1982 and 1991 in the literature. The National Heart, Lung, and Blood Institute registry on PTCA reports two cases of perforation and one case of coronary artery rupture without further information. 2 A detailed case history of 14 patients is available?-" Coronary artery perforation and rupture were reported to occur in the LAD (5 patients), a diagonal branch (7 patients), and the RCA (2 patients).[6]

In the setting of rupture of a CTO, it may be possible to use this approach with minimal risk of myocardial necrosis.

Most auteurs do not clearly distinguish coronary artery perforation from rupture, although it seems appropriate to define perforation as a benign condition, mostly caused by subintimal penetration of the guidewire, not inducing hemodynamic changes, and treatable in a conservative way. Coronary artery rupture is a more serious condition caused by balloon rupture, a subintimal balloon inflation, or the use of balloon that is too large with respect to the diameter of the vessel (balloon-artery mismatch). Rupture leads to dramatic hemodynamic changes inducing coronary subocclusion; and tamponade and requires urgent surgical intervention.

Conclusion:

Coronary artery rupture is a rare but major complication. One should be aware of this potential complication as a greater number of recanalization's will no doubt be performed in the future. Leaving the balloon inflated at the site of the rupture, pericardiocentesis and coronary artery ligation or emergency CABG seem to be the therapies of choice.

References:

1. Ajluni SC, Glazier S, Blankenship L, et al. Perforation after percutaneous coronary interventions: Clinical, angiography therapeutic observations. *Catheter Cardiovasc Diagn* 1994;32:206–212.
2. Wong CM, Kwong Mak GY, Chung DT. Distal coronary artery perforation resulting from the use of hydrophilic coated guidewire in tortuous vessels. *Catheter Cardiovasc Diagn* 1998;44:93–96.
3. Fischell TA, Korban EH, Lauer MA. Successful treatment of distal coronary guidewire-induced perforation with balloon catheter delivery of intracoronary thrombin. *Catheter Cardiovasc Interv* 2003; 58:370–374.
4. Dixon SR, Webster MW, Ormiston JA, et al. Gelfoam embolization of a distal coronary artery guidewire perforation. *Catheter Cardiovasc Interv* 2000;49:214–217.

5. Gaxiola E, Browne KF. Coronary artery perforation repair using microcoil embolization. *Catheter Cardiovasc Diagn* 1998;43:474–476.
6. Fischell, T. A., Carter, A. J., Ashraf, K., Birdsall, J., & Smoker, S. (2006). Coronary artery rupture during balloon

angioplasty, rescued with localized thrombin injection and coil embolization. *Catheterization and Cardiovascular Interventions*, 68(2), 254–257. doi:10.1002/ccd.20714



This work is licensed under Creative Commons Attribution 4.0 License

To Submit Your Article Click Here:

Submit Manuscript

DOI:10.31579/2641-0419/340

Ready to submit your research? Choose Auctores and benefit from:

- fast, convenient online submission
- rigorous peer review by experienced research in your field
- rapid publication on acceptance
- authors retain copyrights
- unique DOI for all articles
- immediate, unrestricted online access

At Auctores, research is always in progress.

Learn more <https://auctoresonline.org/journals/clinical-cardiology-and-cardiovascular-interventions>