

A Complication in Gastric Bypass: Gastro-Jejunal Twist

Gianfranco Gioia *, Paolo Calo

Medical Doctor, Bariatric Surgery, Sandro Pertini Hospital, Rome, Italy.

*Corresponding Author: Gianfranco Gioia, Medical Doctor, Bariatric Surgery, Sandro Pertini Hospital, Rome, Italy.

Received Date: March 15, 2023 | Accepted Date: March 27, 2023 | Published Date: April 03, 2023

Citation: Gioia G., Calo P., (2023), A complication in gastric bypass: gastro-jejunal twist, *International Journal of Clinical Case Reports and Reviews*, 13(4); DOI: 10.31579/2690-4861/304

Copyright: © 2023, Gianfranco Gioia. This is an open-access article distributed under the terms of the Creative Commons Attribution License, which permits unrestricted use, distribution, and reproduction in any medium, provided the original author and source are credited.

Abstract:

The gastric bypass operation is an effective procedure to achieve weight loss in overweight patients. But long-term chronic complications after Roux-en-Y gastric bypass are possible, such as König's syndrome or candy cane syndrome.

Key words: gastric bypass; gastro-jejunal twist; surgical approach

Case Study

The gastric bypass operation is an effective procedure to achieve weight loss in overweight patients. But long-term chronic complications after Roux-en-Y gastric bypass (**Figure 1**) are possible, such as König's syndrome (i. e. abdominal pain related to meals with diarrhea,

constipation, meteorism, and abdominal distension) or candy cane syndrome (i. e. chronic abdominal pain, vomiting, dysphagia, and nausea).

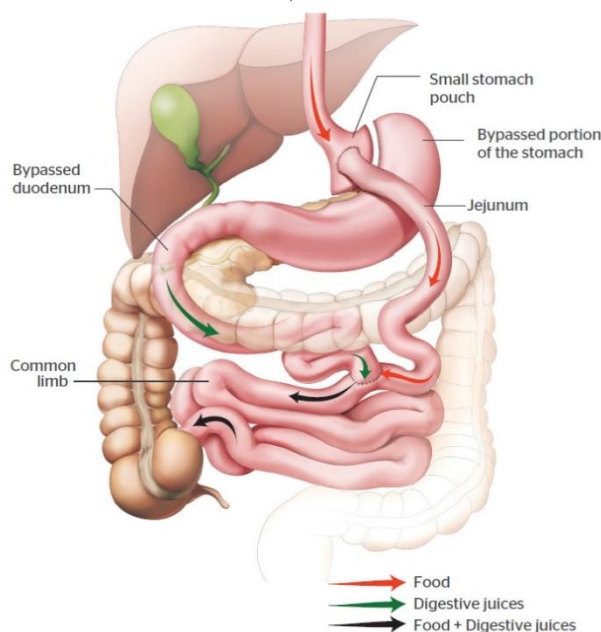


Figure 1: Bariatric surgery anatomy.

Best long-term follow-up diagnostic exams are barium swallow, oesophago-gastro-duodenoscopy, and, in our case, explorative

laparoscopy after computed tomography (CT) with oral contrast showing the presence of a blind and twisted afferent Roux limb at the gastrojejunostomy, i. e. candy cane syndrome (**Figure 2**).

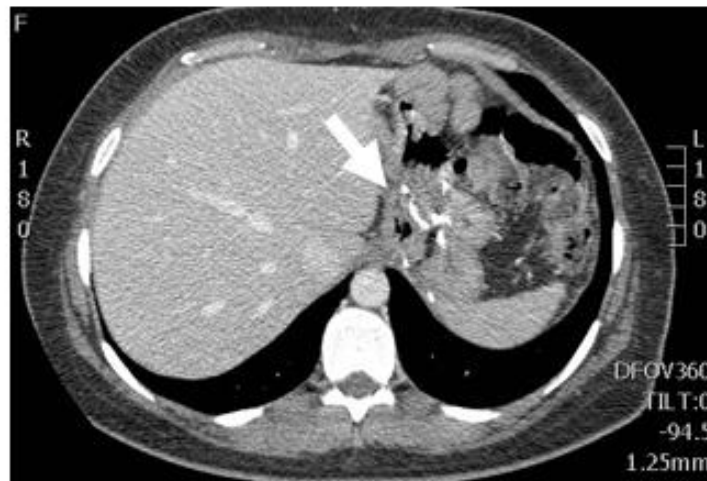

Figure 2: CT showing proximal gastro-jejunal lumen occlusion (indicated by the arrow).

There are little data about the efficacy of surgical revision (1, 2) that seems to be the best treatment with symptomatic relief. In our case study, a 40-year-old female patient with an initial body mass index (BMI) of 36.5 kg/m² was submitted for a Roux-en-Y gastric bypass. At the 3-year follow-up, BMI was 22.4 kg/m² with a significant weight loss. In the last 2 months, there was a further weight loss of 6 kg with the presence of chronic abdominal pain, dyspepsia, dysphagia, abdominal distension, and vasomotor problems (hot flushing, sweating, palpitations, and diarrhea). So, consequently to CT, the patient was submitted for:

- diagnostic laparoscopy showing the integrity of distal anastomosis (**Figure 3**), the presence of a 180 degrees twisted candy cane (**Figure 4**) and multiple adhesences between gastric reservoir (**Figure 5**), liver (**Figure 6**) and proximal anastomosis;
- identification and resection (**Figure 7**) of proximal anastomosis with isolation of gastric reservoir (**Figure 8**);
- untwisting, right repositioning, lifting and re-anastomosis of proximal bypass with gastric reservoir (**Figure 9**).

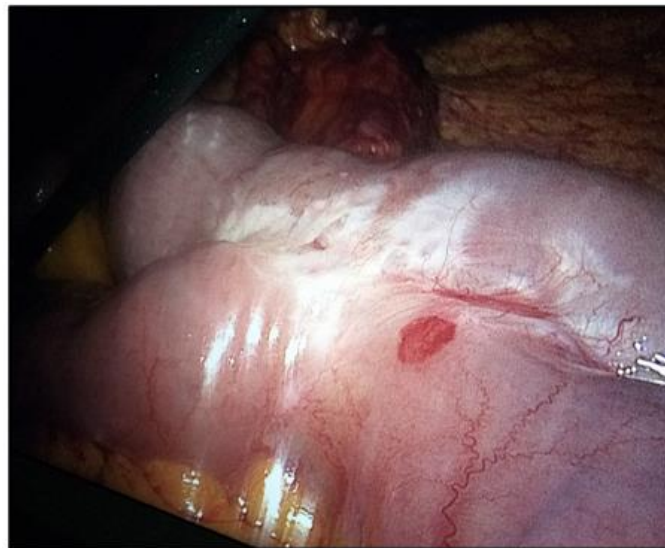


Figure 3. The integrity of the distal jejunum-jejunal anastomosis.

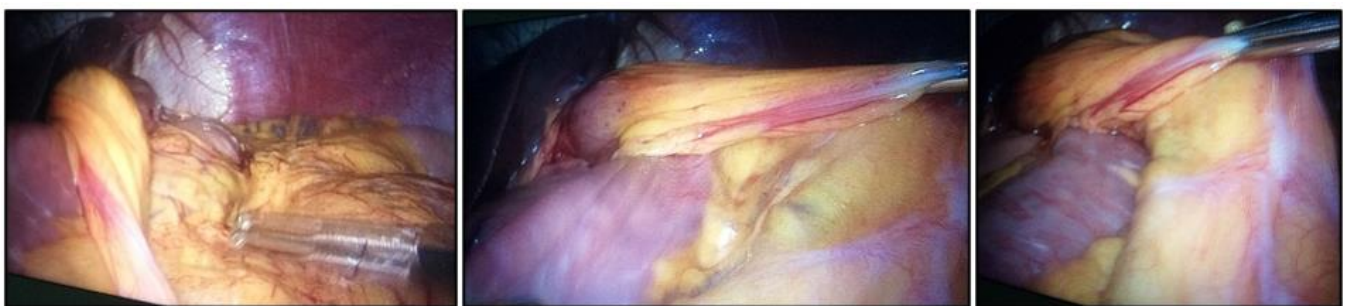


Figure 4. The 180 degrees twisted gastric-jejunal anastomosis.

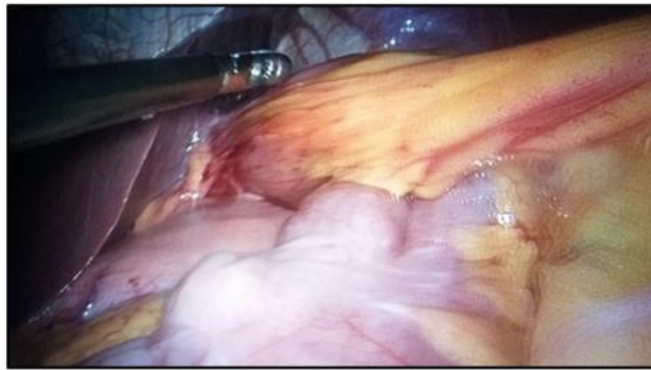


Figure 5. Gastric reservoir fibrotic adhesences with the proximal anastomosis.

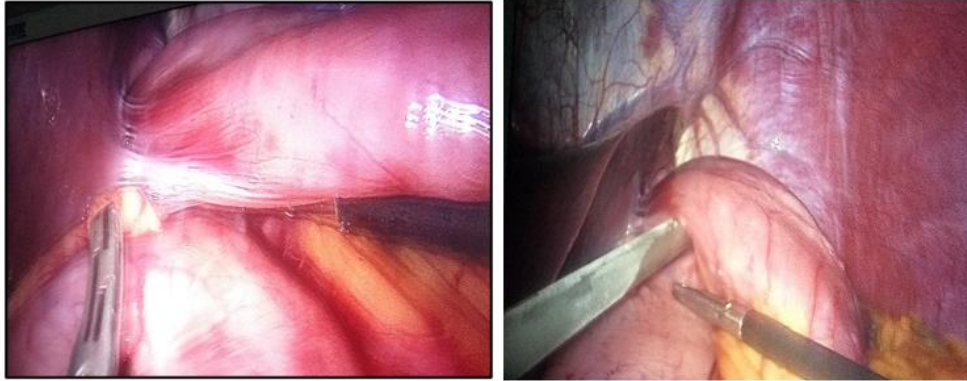


Figure 6. Hepatic fibrotic adhesences with the proximal anastomosis.

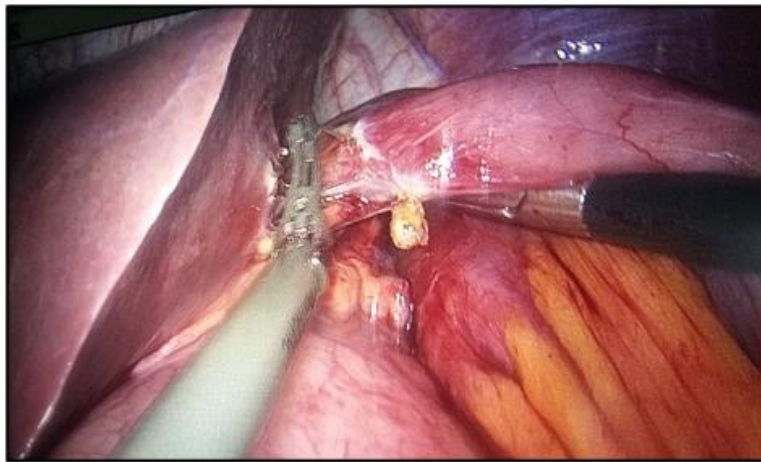


Figure 7. Resection of proximal anastomosis and hepatic fibrotic adhesences.

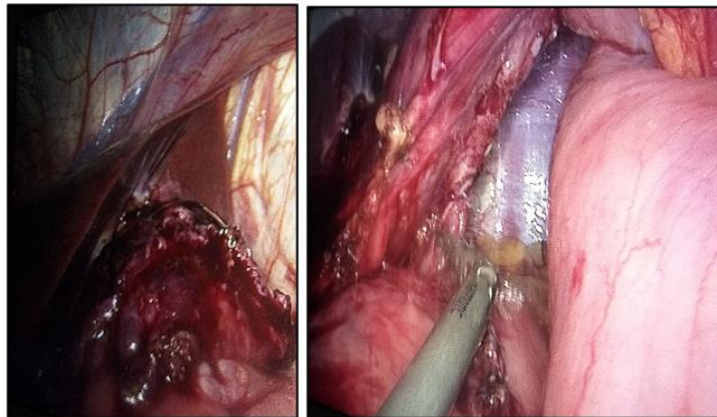


Figure 8. Gastric reservoir after resection of proximal anastomosis.

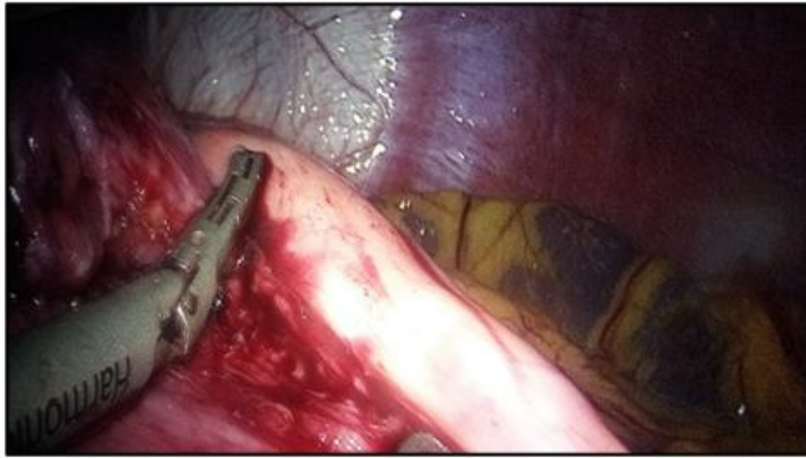

Figure 9: Right repositioning and re-anastomosis of proximal bypass with gastric reservoir.

The postoperative stages were uneventful and the patient was discharged on the third postoperative day. Finally, our lifting surgical approach led us to conclude that this complication could be avoided by not making such a long loop in gastric bypass surgery.

References

1. Cartillone M, Kassir R, Mis TC, Falsetti E, D'Alessandro A, et al. (2020). König's Syndrome After Roux-en-Y Gastric Bypass: Candy Cane Twist. *Obes Surg*; 30(8): 3251-3252.
2. Owens M, Shukla H, Szczepaniak J, Mahdavi A. (2013). Variations on bowel obstruction after gastric bypass and management of the twisted Roux limb. *Surg Obes Relat Dis*; 9(6): 1020-1021.
3. <https://macquarieweightloss.com.au/gastric-bypass-surgery/>



This work is licensed under Creative Commons Attribution 4.0 License

To Submit Your Article Click Here:

[Submit Manuscript](#)

DOI:10.31579/2690-4861/304

Ready to submit your research? Choose Auctores and benefit from:

- fast, convenient online submission
- rigorous peer review by experienced research in your field
- rapid publication on acceptance
- authors retain copyrights
- unique DOI for all articles
- immediate, unrestricted online access

At Auctores, research is always in progress.

Learn more <https://auctoresonline.org/journals/international-journal-of-clinical-case-reports-and-reviews>