

Bony and Soft Tissue Hand Tumors

Ahmad Almgidat ^{1*}, Mohammad Al-Alwan ¹, Yasmin AlSaidat ², Ali Al-Qudah ¹ and Yasmeen ALSoboh ²

¹ Department of Orthopedic, Royal Rehabilitation Center, King Hussein Medical Center, Amman, Jordan.

² Department of Pathology, Princess Iman Research Center, King Hussein Medical Center, Amman, Jordan.

*Corresponding Author: Ahmad Almgidat, Department of Orthopedic; Royal medical Services; Amman – Jordan.

Received Date: February 23, 2023; Accepted Date: March 08, 2023; Published Date: March 22, 2023

Citation: Ahmad Almgidat, Mohammad Al-Alwan, Yasmin AlSaidat, Ali Al-Qudah, and Yasmeen ALSoboh, (2023), Bony and Soft Tissue Hand Tumors, *J. Clinical Orthopedics and Trauma Care*, 5(2); DOI:10.31579/2694-0248/057

Copyright: © 2023 Ahmad Almgidat, This is an open access article distributed under the Creative Commons Attribution License, which permits unrestricted use, distribution, and reproduction in any medium, provided the original work is properly cited.

Abstract

Background: The hand is a common site of tumors and tumor-like pathology. This study aimed to evaluate hand tumors and their distribution regarding age, gender, and histopathological characteristics to promote better understanding and aid in diagnosis.

Material and Methods: A total of 261 incisional or excisional biopsies for hand tumors were reviewed retrospectively from January 2017 to December 2022 at Princess Iman Research Center. The tumor was assessed according to the tumor origin, and histopathological diagnosis was analyzed regarding age and gender to find the correlation. Biopsies with more than one possible diagnosis and excised hand tumors that were not sent to a pathologist were not included.

Results: Soft tissue tumors represented 93.5% and bone tumors 6.5% of all hand tumors. Malignant tumors were reported in 6.1%. Tendon sheath (19.2%) and synovial (17.6%) origin tumors were the most common types, followed by skin (13%) and vascular (12.6%) tumors. Giant cell tumor was the most common hand tumor type (18.8%), followed by Ganglion cyst (16.5%). Enchondroma was the most common bone tumor (3.1%), and squamous cell carcinoma was the most common malignant tumor in hand. There was no difference in the distribution of tumors between different gender and ages.

Conclusions: Although ganglion is the most common hand tumor in all reports, in our study, it was the second most common after the Giant cell tumor of tendon sheath because many surgeons depended on the clinical picture alone. Multicenter studies and other study designs, such as clinical and radiological evaluation, are required for a better understanding of the distribution of hand tumors.

Running Title: Hand Tumors

Keywords: hand tumor; biopsy; histopathology; bone; soft tissue; Jordan

Introduction

The hand represents 2% of total body surface area and 1.2% of total body weight [1]. However, it is a common site of tumors and tumor-like pathology, and soft tissue tumor of the hand represents 15% of body soft tissue tumors [2]. Hand tumors are recognized early due to superficial location and easy palpation. Therefore, hand tumors are more frequently surgically treated [3].

Hand tumors may originate from different embryological precursors and, therefore, can differentiate into different structures, including bone, cartilage, muscle, tendon, synovium, skin, vessels, and nerves [5]. According to the World Health Organization (WHO) classification, soft tissue and bone tumors, tumors are classified based on their resemblance to their normal counterpart. Tumor-like lesions or pseudotumors originated from different structures and are not true neoplasms [6].

Although diagnosis can be reached based on clinical and radiological features, a biopsy is a definitive test to confirm the diagnosis. On many occasions, it is difficult to differentiate benign and reactive lesions from malignant and aggressive tumors only on clinical presentation. Therefore, orthopedic clinicians should be familiar with hand tumors and refer suspicious tumors to specialized units for proper treatment because simple tumor excision may compromise the outcome.

Studies are limited in Jordan regarding hand tumors. Therefore, this study aimed to evaluate hand tumors and their distribution regarding age, gender, and histopathological characteristics to promote better understanding and aid in diagnosis.

Materials and Methods

In this retrospective, single-center study, we will include all patients who underwent incisional or excisional biopsies for hand tumors at Princess Iman Research Center (PIRC)/ King Hussein Medical City (KHMC) from January 2017 to December 2022. Sociodemographic data will be extracted from patients' records.

Princess Iman Research Center receives specimens from KHMC and all-district military hospitals in Jordan, which cover many Jordanian population insurances. Therefore, studies from the such center are representative. Each biopsy was evaluated by two histopathologists, first by a specialist for the diagnosis, then confirmed by a consultant.

The tumors were classified into soft tissue and bony origin. Tumors were further subdivided according to the tumor origin, such as skin, fat, muscle, nerve, vessels, synovium, bone and cartilage, and unknown origin. Histopathological diagnosis was analyzed regarding age and gender to find the correlation.

A total of 261 hand tumor specimens were evaluated. The study included all diagnostic or excisional biopsies confirming tumors and pseudotumors of the hand and a single diagnostic biopsy. Reports with more than one possible diagnosis were excluded, and excised hand tumors that were not sent to a pathologist were excluded.

Statistical Data Analysis

The mean and standard deviation were used to describe the continuously measured variables, and the frequency and percentages were used to describe

the categorically measured variables. The chi-squared test of independence was used to assess the correlations between categorically measured variables. The One-way ANOVA test was used to assess the statistical mean differences in metric variables across the levels of more than two categorical measured variables. The SPSS IBM V21 statistical data analysis program was used for the data analysis. The alpha significance level was considered at 0.050 level.

Results

Two hundred sixty-one hand tumor biopsy results were reviewed retrospectively. Table 1 summarizes findings for the patients' sociodemographic characteristics and histopathological origin. Females represented 52.5% of the study sample. More than half of the patients were aged 20 to 50, and their mean age was 37.86 (± 18.763). Soft tissue tumors represent the majority of hand tumors, with a percentage of 93.5. tendon sheath tumors were the most common tumor origin, and two-thirds of tumors formed by tendon and tendon sheath, synovial origin, skin, and vessels. However, osseous and cartilaginous origin tumors represented 6.5% of all tumor types. Malignant tumors were reported in 16 histopathological results, representing 6.1%; Soft tissue malignancies of the hand accounted for 5.3% secondary to the inclusion of skin cancers, while bone tumors of the hand accounted for 0.8% of all hand tumors.

	Number	%
Gender		
Male	124	47.5
Female	137	52.5
Age Group		
< 20 years	49	18.8
20 – 50 years	148	56.7
> 50 years	64	24.5
Extremity		
Right	147	56.3
Left	114	43.7
Tumor origin		
Soft tissue	244	93.5
Bone	17	6.5
Grade		
Benign	245	93.9
Malignant	16	6.1
Histopathological origin		
Tendon and tendon sheath	50	19.2
Synovial origin	46	17.6
Skin	34	13.0
Vessels	33	12.6
Nerve origin	22	8.4
Fibrous Producing	20	7.7
Inflammatory	19	7.3
Fat Producing	15	5.7
Chondroid producing	9	3.4
Osteoid producing	8	3.1
Muscle Origin	3	1.1
Mesenchymal cells	1	0.4
Unknown Origin	1	0.4

Table 1: Hand tumors descriptive analysis, N= 261.

Table 2 compares the mean age of patients with different tumor origins. Patients with soft tissue tumors are older than patients with bony tumors.

However, skin tumor patients had the highest mean age (50.09 ±23.253) followed by fat-origin tumors, while chondroid-origin tumors are younger. However, there was no statistical significance for other tumor origins.

	Mean age (SD)	P-value
Total patients	37.86 (±18.763)	0.04
Bone tumors	25.29 (±12.403)	
Soft tissue Tumor	38.74 (±18.834)	
Tendon and tendon sheath	38.08 (±16.552)	0.075
Synovial origin	37.07(±17.903)	0.106
Skin	50.09 (±23.253)	0.001
Vessels	36.67 (±18.508)	0.131
Nerve origin	32.18 (±13.588)	0.416
Fibrous Producing	34.80(±18.323)	0.246
Inflammatory	37.58 (±18.919)	0.127
Fat Producing	43.40 (±19.748)	0.026
Chondroid producing	26.33(±14.705)	0.026
Osteoid producing	24.13(±10.077)	0.802
Muscle Origin	23.33 (±11.150)	0.804
Mesenchymal cells	51.00	0.198

Table 2: Mean age of different tumor origins.

The giant cell tumor of the tendon sheath was the most common and accounted for 18.8%, followed by a ganglion cyst (16.5%). Granuloma, lipoma, and traumatic neuroma accounted for 6.1%, 5.4%, and 4.6%, respectively, see table 3. There was no difference in the distribution of the tumors between gender, Figure 1. Similarly, there was no difference in the

distribution of different tumors between different age groups except for skin and vessel-origin tumors, Figure 2. Skin tumors tend to occur in older patients, while vessel-origin tumors occur more frequently in patients between 20 and 50, table 4.

Tumor origin	Diagnosis	Total (%)	Male (%)	Female (%)	P-value
Soft Tissue tumors					
Fat	Lipoma	14 (5.4)	6 (42.9)	8 (57.1)	0.268
	Fat necrosis	1 (0.4)	1 (100)	0	
Fibrous	Fibroma	11 (4.2)	8 (72.7)	3 (27.3)	0.430
	Fibrosis	5 (1.9)	2 (40)	3 (60)	
	Dermatofibroma	2 (0.8)	1 (50)	1 (50)	
	Fibromatosis	1 (0.4)	0	1 (100)	
	Chondromyxoid fibroma	1 (0.4)	0	1 (100)	
Muscle	Myositis ossificans	3 (1.1)	1 (33.3)	2 (66.6)	0.137
Nerve	Neuroma	2 (0.8)	0	2 (100)	0.093
	Schwannoma	6 (2.3)	2 (33.3)	4 (66.6)	
	Traumatic neuroma	12 (4.6)	9 (75)	3 (25)	
	Plexiform neurofibroma	2 (0.8)	0	2 (100)	
Synovium	Ganglion cyst	43 (16.5)	18 (41.9)	25 (58.1)	0.356
	Synovial cyst	3 (1.1)	0	2 (100)	
Tendon and tendon sheath	GCT of the tendon sheath	49 (18.8)	17 (34.7)	32 (65.3)	0.178
	Calcifying aponeurotic fibroma	1 (0.4)	1 (100)	0	
Vessels	Arteriovenous Malformation	4 (1.5)	1 (25)	3 (75)	0.211
	Hemangioma	11 (4.2)	6 (54.5)	5 (45.5)	
	Cavernous hemangioma	3 (1.1)	1 (33.3)	2 (66.6)	
	Glomus tumor	3 (1.1)	3 (100)	0	
	Cherry angioma	1 (0.4)	1 (100)	0	
	Angiomyoma	1 (0.4)	1 (100)	0	
	Epithelioid hemangioendothelioma	1 (0.4)	0	1 (100)	
	Hemangiopericytoma	2 (0.8)	2 (100)	0	
	Masson Hemangioma	2 (0.8)	1 (50)	1 (50)	
	Vascular hamartomas	1 (0.4)	0	1 (100)	
Inflammatory	Granuloma	16 (6.1)	8 (50)	8 (50)	0.274
	Abscess	2 (0.8)	0	2 (100)	
	Rheumatoid nodule	1 (0.4)	0	1 (100)	
Mesenchymal cells	Ewing Sarcoma	1 (0.4)	0	1 (100)	0.159
Unknown origin	Epithelioid Sarcoma	1 (0.4)	0	1 (100)	0.467
Skin	Epidermal inclusion cyst	12 (4.6)	10 (83.3)	2 (16.7)	0.168
	Squamous cell carcinoma	10 (3.8)	5 (50)	5 (50)	
	Nevus	4 (1.5)	3 (75)	1 (25)	
	Malignant melanoma	1 (0.4)	0	1 (100)	
	Others	7 (2.7)	2 (28.6)	5 (71.4)	
Bone tumors					
Cartilage	Enchondroma	8 (3.1)	6 (75)	2 (25)	0.571
	Nora lesion	1 (0.4)	1 (100)	0	
Bone	Osteochondroma	3 (1.1)	2 (66.6)	1 (33.3)	0.255
	Osteomyelitis	2 (0.8)	2 (100)	0	
	Fibroblastic osteosarcoma	1 (0.4)	0	1 (100)	
	Osteoid osteoma	1 (0.4)	0	1 (100)	
	Simple bone cyst	1 (0.4)	0	1 (100)	
* Numbers within the brackets represent the percentage of all tumors in the "Total" column and the percentage within the same category in the other columns.					

Table 3: Bivariate analysis of different tumors with gender.

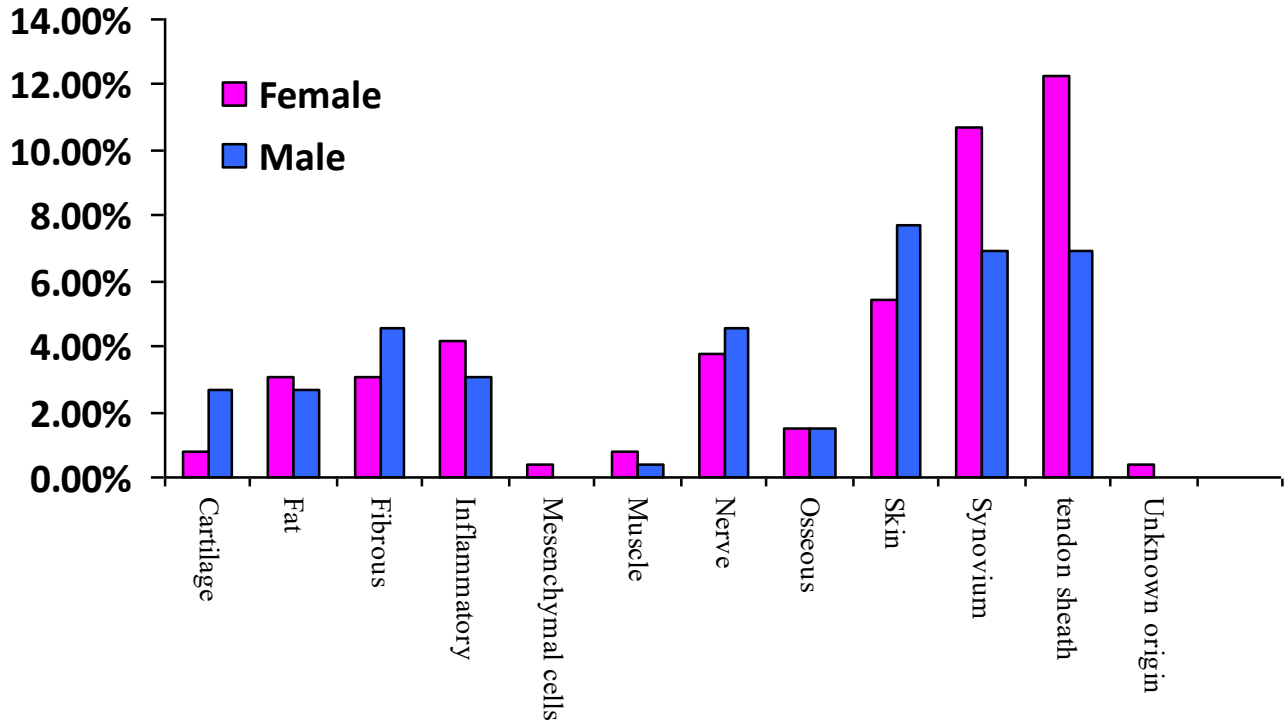


Figure 1: Distribution of different tumors based on their origin between different gender.

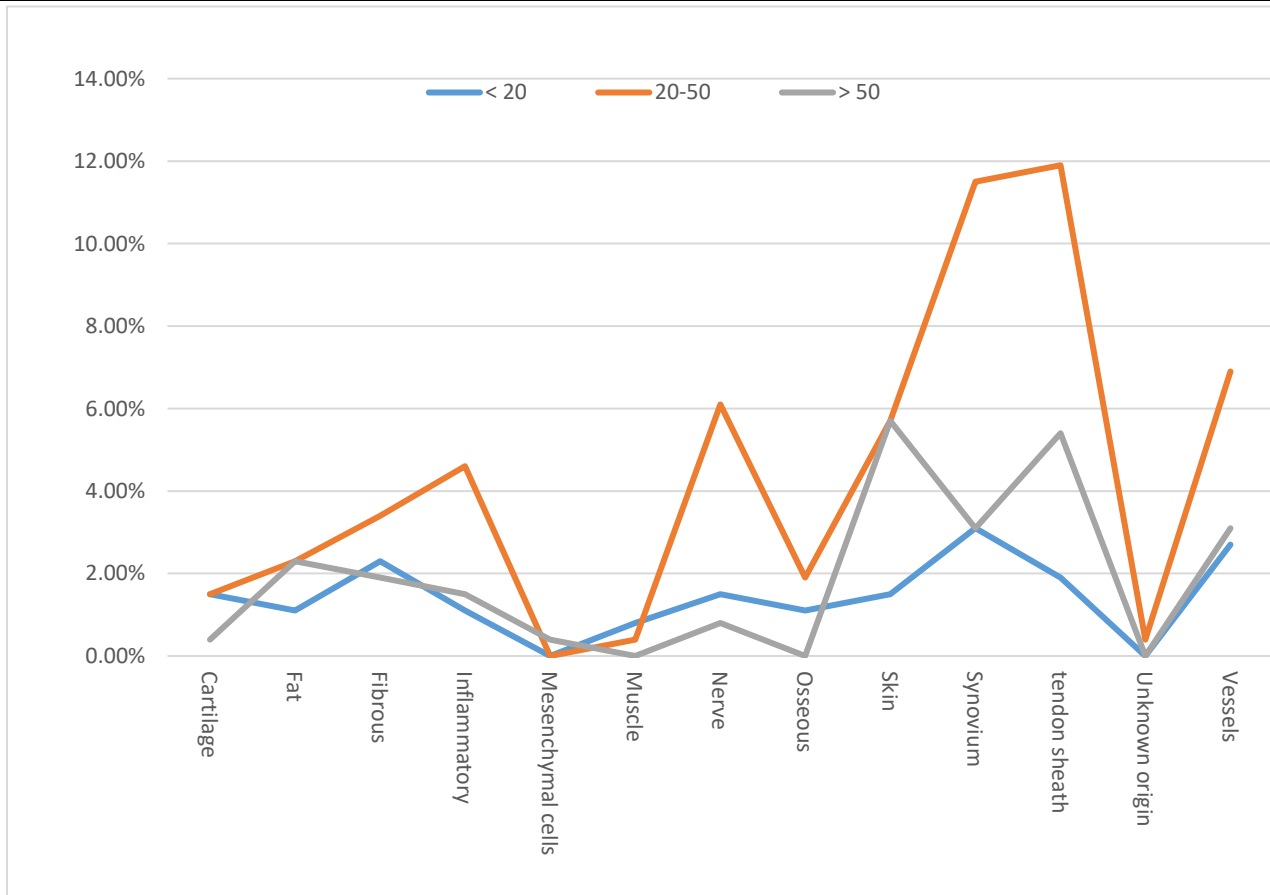


Figure 2: Distribution of different tumors based on their origin between different age groups.

Tumor origin	Diagnosis	< 20	20-50	> 50	P- value
Soft Tissue tumors					
Fat	Fat necrosis	0	0	1 (100)	0.448
	Lipoma	3 (21.4)	6(42.8)	5(35.8)	
Fibrous	Chondromyxoid fibroma	0	1 (100)	0	0.524
	Dermatofibroma	1 (50)	0	1(50)	
	Fibroma	2 (18.2)	6 (54.5)	3 (27.3)	
	Fibromatosis	0	1	0	
	Fibrosis	3 (60)	1 (20)	1 (20)	
Inflammatory	Abscess	0	2 (100)	0	0.721
	Granuloma	3 (18.7)	9 (56.3)	4 (25)	
	Rheumatoid nodule	0	1 (100)	0	
Mesenchymal cells	Ewing Sarcoma	0	0	1 (100)	
Muscle	Myositis ossificans	2 (66.7)	1 (33.3)		0.545
Nerve	Neuroma	1 (50)	1 (50)	0	0.614
	Plexiform neurofibroma	1 (50)	1 (50)	0	
	Schwannoma	0	5 (83.3)	1 (16.7)	
	Traumatic neuroma	2 (16.7)	9 (75)	1 (8.3)	
Skin	Epidermal inclusion cyst	1 (8.3)	7 (58.3)	4 (33.3)	0.034
	Malignant melanoma	0	0	1 (100)	
	Nevus	3 (75)	0	1 (25)	
	Squamous cell carcinoma	0	3 (30)	7 (70)	
	Others	0	5 (71.4)	2 (28.6)	
Synovium	Ganglion cyst	8 (18.6)	28 (65.1)	7 (16.2)	0.691
	synovial cyst	0	2 (66.7)	1 (33.3)	
Tendon and tendon sheath	Calcifying aponeurotic fibroma	0	0	1 (100)	0.269
	GCT of the tendon sheath	5 (10.2)	31 (63.3)	13 (26.5)	
Unknown origin	Epithelioid Sarcoma	0	1 (100)	0	
Vessels	Arteriovenous Malformation	4 (100)	0	0	0.025
	Cavernous hemangioma	1 (33.3)	2 (66.7)	0	
	Glomus tumor	0	1 (33.3)	2 (66.7)	
	Hemangioma	1 (9.1)	7 (63.6)	3 (27.3)	
	Others	1 (11.1)	5 (55.6)	3 (33.3)	
Bony tumors					
Cartilage	Enchondroma	4 (44.4)	3(33.3/0	1(11.1)	0.495
	Nora lesion	0	1 (100)	0	
Osseous	Fibroblastic osteosarcoma	1 (100)	0	0	0.272
	Osteochondroma	2 (66.7)	1 (33.3)	0	
	Osteoid osteoma	0	1 (50)	1 (50)	
	Osteomyelitis	0	2 (100)	0	
	Simple bone cyst	0	1 (100)	0	

* Numbers within brackets represent the percentage within the same age category.

Table 4: Bivariate analysis of different tumors with different age groups.

Discussion

In this study, we collected all hand tumor-biopsy results over five years from Princess Iman Research Center; As a consequence of this data collection design, tumors that were not treated surgically or evaluated by diagnostic or

excisional biopsies were omitted. In Jordan, no sufficient resources illustrate the distribution of hand tumors; regional resources are also limited. Therefore, this study aimed to understand the distribution of hand tumors and their histopathological subtypes to aid in diagnosis.

We reported in the previous two studies that soft tissue hand tumors accounted for 16% of all musculoskeletal soft tissue tumors, while bone hand tumors accounted for 9.9% of all musculoskeletal bone tumors. However, Enchondroma represented 69% of all hand bony tumors, which is compatible with published articles [7,8].

Most hand tumors arose from the soft tissue, while bone location tumors were uncommon [9]. In our review, tendon sheath and synovial origin tumors were the most common tissue origin. However, many tumors are found incidentally and do not usually require treatment or evaluation by biopsy. For example, many surgeons don't send the ganglion for histopathological confirmation, and although the frequency of such masses was high in our study, it is expected to be much higher if it was evaluated by histopathological study. On the other hand, Pseudotumors are counted as tumors because they have the same clinical and radiological features and are part of the differential diagnosis of tumors. Bone osteomyelitis can simulate bone tumors and should be considered in the differential diagnosis. Imaging studies may demonstrate lytic lesions and cortical destruction or a sclerotic area from an involucrum that looks like a blastic tumor [9]. Therefore, many pathologies are counted as tumors because of their clinical presentation, and many require histopathological confirmation.

Although ganglion is known to be the most common hand tumor, in our study, it is the second most common tumor and represented 16.5 % of hand tumors. The Giant cell tumors of the tendon sheath (GCT) were the most common and represented 18.8%; this is explained by the study's design and the fact that many orthopedic surgeons rely on the clinical picture of ganglion without histopathological study.

Ganglion cysts are the hand's most common soft tissue tumors; approximately 70% of the ganglion arise on the dorsum of the wrist and 20 % on the volar aspect of the wrist. Ganglions are three times more frequent in females. Reassurance, aspiration, or surgical excision are treatment options, with spontaneous disappearance occurring in 40% of adults and 75% of children [11-13].

GCT is the second most common tumor in hand; however, it was the most common in our study. They have a predilection for the female and are typically located on the palmar side of the hand, with a tendency to involve the three radial digits and the distal interphalangeal joints. GCTs can be distinguished from ganglions because they are less mobile and do not transilluminate like ganglia. GCT can affect the digital nerves and demonstrate pressure erosion on the radiograph of the underlying bone. Recurrences after marginal excision can reach 5 to 50% due to the presence of satellite lesions or incomplete excision [14-16].

Pyogenic granuloma, in our review, is the third most common hand tumor. It represents a chronically inflamed solitary red nodule that may be related to trauma developing in subclinical infection [17]. Lipoma is the most common tumor in the body, though it is rare in the upper extremity. They usually occur as a solitary mass in the subcutaneous fat but occasionally in deeper layers such as subfacial and intraosseous. However, 31% of lipoma had non-adipose components, contributing to different variations such as angiolipoma and myolipoma. Lipoma can cause compressive neuropathy if present in carpal tunnel and Guyon's canal [18,19]. Fat necrosis occurs due to fat trauma and surgery and causes hard lumps under the skin, resembling tumors [20].

Traumatic neuromas are common in our review, which is explained by the high frequency of hand injuries. It represents a non-neoplastic proliferation

of the (completely or partially) injured proximal nerve segment and occurs in two types; swelling around an intact nerve after chronic irritation causes spindle neuroma, and swelling at the end of a partially or completely severed nerve causes stub neuroma. A traumatic neuroma usually occurs 1 to 12 months after nerve injury and presents with intense neuralgia and as a mass if large enough [21,22].

On the other hand, Schwannomas or neurilemmomas are benign neoplastic proliferation of Schwann cells presented as a slow-growing, well-encapsulated, painless mass. Schwannomas have similar consistency of ganglion and are frequently misdiagnosed as a ganglion. Intraoperatively, Schwannomas are easily separated from the surrounding nerve, and postoperative neurological deficits and recurrences are rare [23,24].

The traumatic implantation of epidermal fragments causes epidermal inclusion cysts into the dermis during minor trauma, injection, or incision. Therefore, they are more common in male workers. Epidermal inclusion cyst is also described as an epidermal cyst, traumatic epithelial cyst, implantation cyst, sebaceous cyst, and squamous cyst. The epidermis can be inserted traumatically into the periosteum, producing a cyst, which appears as a lytic lesion on radiographs and may mimic a malignancy that requires histological confirmation [25-27].

Most authors did not include skin pathologies with hand tumors. However, the skin is part of the hand structures, and many skin pathologies are encountered by orthopedic surgeons at the first presentation. The design of our study is based on reviewing histopathological specimens, and many hand skin lesions were sent for histopathology. However, our study only included those with the mass presentation. Squamous cell carcinoma is the most common malignant tumor of the hand, and most occur on the dorsum of the hand. SCC may complicate chronic inflammation, such as burns, sinuses, and around nonhealing wounds [28,29]. Therefore, orthopedic surgeons should be familiar with such pathologies.

Bone tumors represented a minority of hand tumors. Enchondroma is the most common primary hand tumor and accounts for approximately 90% of bone tumors in hand, which are often diagnosed incidentally after pathological fractures. Most enchondromas are solitary but may be multiple as part of Ollier's disease and Maffucci's syndrome, which carries the risk of malignant transformation up to 25 and 100%, respectively [30,31].

The description of each tumor type is beyond the scope of this study. However, we aim to develop a better understanding of hand tumors. Generally, patients with bone tumors are younger than patients with soft tissue tumors, and there were no differences in tumor distribution between males and females. Patients with skin tumors are older due to the relatively high frequency of squamous cell carcinoma.

Our study has many limitations; the retrospective design and inclusion of only hand tumors that were surgically excised and sent for biopsy. Tumors not evaluated by pathologists were not included in the study. Therefore, the number of many tumors is suspected to be much higher, and, on the other hand, the frequency of certain tumors could be higher because they mandate surgical excision once diagnosed.

Conclusion

In our 261-sample, hand soft tissue tumors represented the majority of the tumors. Tendon sheath and synovial origin were the most common type. Although ganglion is the most common hand tumor in all reports, in our study, it was the second most common after the Giant cell tumor of tendon sheath because most excised masses were not evaluated by histopathological

study and, therefore, not counted. There were no significant differences in tumor distribution between genders and age groups. Multicenter studies and other study designs, such as clinical and radiological evaluation, are required for a better understanding of the distribution of hand tumors.

Ethical Approval

This study was approved by the Royal Medical Services Human Research Ethics Committee

Funding

The research did not receive any specific grant from funding agencies in the public, commercial or non-profit sectors.

Competing interests

The authors declare that they have no conflict of interest.

Availability of Data and Material

Available upon request.

References

- Nepal P, Songmen S, Alam SI, Gandhi D, Ghimire N, Ojili V. (2019), Common Soft Tissue Tumors Involving the Hand with Histopathological Correlation. *J Clin Imaging Sci.* 2019 May 24; 9:15.
- Garcia J, Bianchi S. (2001), Diagnostic imaging of tumors of the hand and wrist. *Eur Radiol*, 2001; 11:1470-1482.
- Sacks JM, Azari KK, Oates S, Chang DW (2013), Benign and malignant tumors of the hand. In: Neligan PC (ed) Plastic surgery, Saunders. *Elsevier, Philadelphia*, 6:311–332.
- Hsu CS, Hentz VR, Yao J (2007), Tumours of the hand. *Lancet Oncol* 8(2):157–166.
- Radomska KJ, Couplier F, Gresset A, Schmitt A, Debbiche A, Lemoine S, et al. (2019), Cellular Origin, Tumor Progression, and Pathogenic Mechanisms of Cutaneous Neurofibromas Revealed by Mice with *Nfl* Knockout in Boundary Cap Cells. *Cancer Discov.* 2019 Jan;9(1):130-147.
- Jo VY, Fletcher CD. (2014), WHO classification of soft tissue tumours: an update based on the 2013 (4th) edition. *Pathology*, 2014 Feb; 46(2):95-104.
- Almgidad AK, Dagher BZ, Alwaqfi OM, Ghabashneh MA, Alfqaha HA. (2021), Bone tumors distribution in diagnostic and excisional biopsies. *J Musculoskelet Surg Res* 2021; 5(3):159-168.
- Ahmad Almgidad, Noor Megdadi, Bara' Dagher., Ola M. Alwaqfi, Mutaz Ghabashneh. (2021), Distribution and evaluation of musculoskeletal soft tissue tumors in histopathological specimens. *European Journal of Pharmaceutical and Medical Research.* 2021; 8(2):150-157.
- Lans J, Yue KC, Castelein RM, Suster DI, Petur Nielsen G, Chen NC, et al. (2022), Benign Hand Tumors (Part II): Soft Tissue Tumors. *Hand (N Y)*. 2022 May;17(3):519-528.
- Honda H, McDonald JR. Current recommendations in the management of osteomyelitis of the hand and wrist. *J Hand Surg Am.* 2009;34(6):1135-1136.
- Murray P. Ganglions of the hand and wrist. In: Cooney WP III, ed. *The Wrist: Diagnosis and Operative Treatment*. 2nd edition. Philadelphia: *Lippincott Williams Wilkins*; 2010:1137-52.
- Athanasian EA (2011) Bone and soft tissue tumors. In: Wolfe SW (ed) *Green's operative hand surgery*, *Churchill Livingstone, London*; 2(6):2141–2195.
- Nahra ME, Bucchieri JS (2004), Ganglion cysts and other tumor related conditions of the hand and wrist. *Hand Clin*; 20(3):249–260.
- Gouin F, Noailles T. (2017); Localized and diffuse forms of tenosynovial giant cell tumor (formerly giant cell tumor of the tendon sheath and pigmented villonodular synovitis). *Orthop Traumatol Surg Res.* 2017 Feb; 103(1S):S91-S97.
- Wan JM, Magarelli N, Peh WC, Guglielmi G, Shek TW. (2010); Imaging of giant cell tumour of the tendon sheath. *Radiol Med.* 2010 Feb; 115(1):141-151.
- Koutserimpas C, Kastanis G, Ioannidis A, Filippou D, Balalis K. (2018), Giant cell tumors of the tendon sheath of the hand: an 11-year retrospective study. *J BUON.* 2018 Sep-Oct; 23(5):1546-1551.
- Lin RL, Janniger CK. (2004); Pyogenic granuloma. *Cutis.* 2004 Oct;74(4):229-233.
- Kransdorf MJ, Bancroft LW, Peterson JJ, et al. (2002); Imaging of fatty tumors: Distinction of lipoma and well-differentiated liposarcoma. *Radiology* 2002; 224:99-104.
- Mavrogenis AF, Panagopoulos GN, Angelini A, et al. (2017), Tumors of the hand. *Eur J Orthop Surg Traumatol* 2017; 27:747-762.
- Rao A, Saadeh PB. (2014), Defining fat necrosis in plastic surgery. *Plast Reconstr Surg.* 2014 Dec; 134(6):1202-1212.
- Woertler K. (2010), Tumors and tumor-like lesions of peripheral nerves. *Semin Musculoskelet Radiol.* 2010 Nov; 14(5):547-558.
- Oliveira KMC, Pindur L, Han Z, Bhavsar MB, Barker JH, Leppik L. (2018), Time course of traumatic neuroma development. *PLoS One.* 2018 Jul 16; 13(7):e0200548.
- Hilton DA, Hanemann CO. (2014), Schwannomas and their pathogenesis. *Brain Pathol.* 2014 Apr; 24(3):205-220.
- Strike SA, Puhaindran ME. (2019), Nerve Tumors of the Upper Extremity. *Clin Plast Surg.* 2019 Jul; 46(3):347-350.
- Pandya KA, Radke F. (2009), Benign skin lesions: lipomas, epidermal inclusion cysts, muscle and nerve biopsies. *Surg Clin North Am.* 2009 Jun; 89(3):677-687.
- Simon K, Leithner A, Bodo K, Windhager R. (2011), Intraosseous epidermoid cysts of the hand skeleton: a series of eight patients. *J Hand Surg Eur.* 2011; 36(5):376e378.
- Kim HK, Kim SM, Lee SH, Racadio JM, Shin MJ. (2011), Subcutaneous epidermal inclusion cysts: ultrasound (US) and MR imaging findings. *Skeletal Radiol.* 2011 Nov; 40(11):1415-1419.
- Waldman A, Schmults C. (2019), Cutaneous Squamous Cell Carcinoma. *Hematol Oncol Clin North Am.* 2019 Feb; 33(1):1-12.
- Mull JL, Phelan PS, Mull AB, Russell AJ, Hurst EA, Council ML. (2020), Squamous Cell Carcinoma of the Hand: A Retrospective Study in Immunosuppressed and Immunocompetent Individuals. *Dermatol Surg.* 2020 Aug; 46(8):1014-1020.

30. Lubahn JD, Bachoura A. (2016), Enchondroma of the Hand: Evaluation and Management. *J Am Acad Orthop Surg.* 2016 Sep; 24(9):625-633.
31. Tang C, Chan M, Fok M, Fung B. (2015), Current management of hand enchondroma: a review. *Hand Surg.* 2015; 20(1):191-195.



This work is licensed under Creative Commons Attribution 4.0 License

To Submit Your Article Click Here:

Submit Manuscript

DOI:10.31579/2694-0248/057

Ready to submit your research? Choose Auctores and benefit from:

- fast, convenient online submission
- rigorous peer review by experienced research in your field
- rapid publication on acceptance
- authors retain copyrights
- unique DOI for all articles
- immediate, unrestricted online access

At Auctores, research is always in progress.

Learn more <https://auctoresonline.org/journals/clinical-orthopaedics-and-trauma-care>