

A Comprehensive and Clinical Review of Distal Deletion Syndrome of Chromosome 5q14.3

Maryam Mountazeri ¹, Amir Shokri ², Mohadeseh Zoughi ³, Narjes Arshia ³, Shahin Asadi ^{4*}

¹ Midwifery department, Faculty of Nursing and Midwifery, Tabriz University of Medical Sciences, Iran

² Director of the Division of Medical Genetics and Molecular Optogenetic Research.

³ Division of Medical Genetics and Molecular Pathology Research, Harvard University, Boston Children's Hospital.

⁴ Medical Genetics-Harvard University.

*Corresponding Author: Shahin Asadi, Medical Genetics-Harvard University.

Received date: December 28, 2022; Accepted date: January 06, 2023; Published date: January 20, 2023

Citation: Maryam Mountazeri, Amir Shokri, Mohadeseh Zoughi, Narjes Arshia and Shahin Asadi, (2023) A Comprehensive and Clinical Review of Distal Deletion Syndrome of Chromosome 5q14.3. *Archives of Medical Case Reports and Case Study*, 7(1); DOI:10.31579/2692-9392/164

Copyright: © 2023, Shahin Asadi. This is an open access article distributed under the Creative Commons Attribution License, which permits unrestricted use, distribution, and reproduction in any medium, provided the original work is properly cited.

Abstract

Cardozo et al. (2009) reported 3 unrelated children, 2 boys and 1 girl, with severe mental retardation, epilepsy, and bilateral periventricular heterotopia limited to the subcutaneous region of the temporal bones and occipital lateral ventricles. Other features of this syndrome include hypotonia, delayed motor development, lack of speech, and minor facial deformities such as prominent forehead, depressed nasal bridge, and high blood pressure

Key words: distal chromosome 5q14.3 deletion syndrome; chromosomal disorders; child syndromes

Clinical Signs and Symptoms of Distal Chromosome 5q14.3 Deletion Syndrome

Cardozo et al. (2009) reported 3 unrelated children, 2 boys and 1 girl, with severe mental retardation, epilepsy, and bilateral periventricular

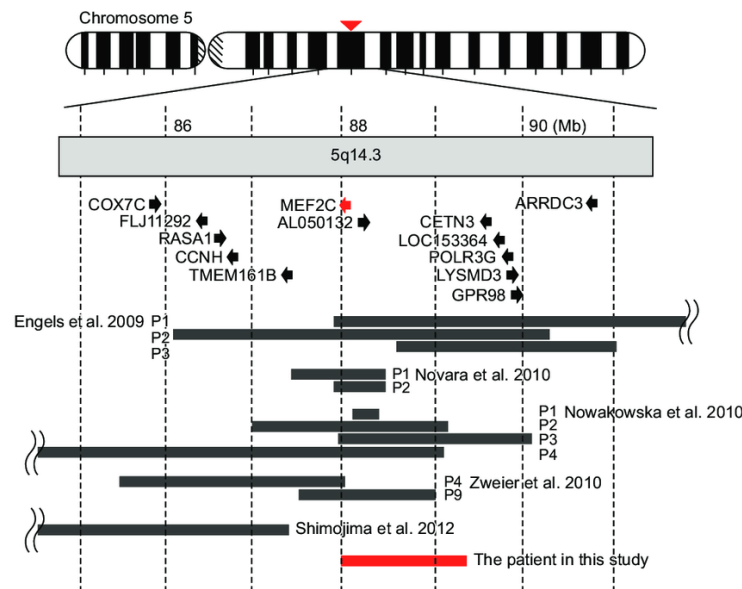
heterotopia limited to the subcutaneous region of the temporal bones and occipital lateral ventricles. Other features of this syndrome include hypotonia, delayed motor development, lack of speech, and minor facial deformities such as prominent forehead, depressed nasal bridge, and high blood pressure. Also, one of the patients showed polymicrogyria in brain MRI [1].

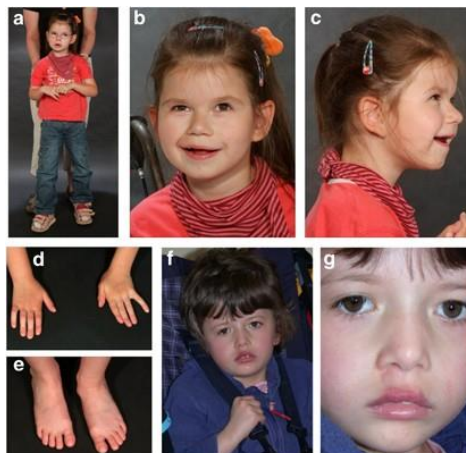

Figure 1: Illustration of children with distal deletion syndrome of chromosome 5q14.3 with distinctive facial features [1].**Etiology and Discussion of Distal Deletion Syndrome of Chromosome 5q14.3**

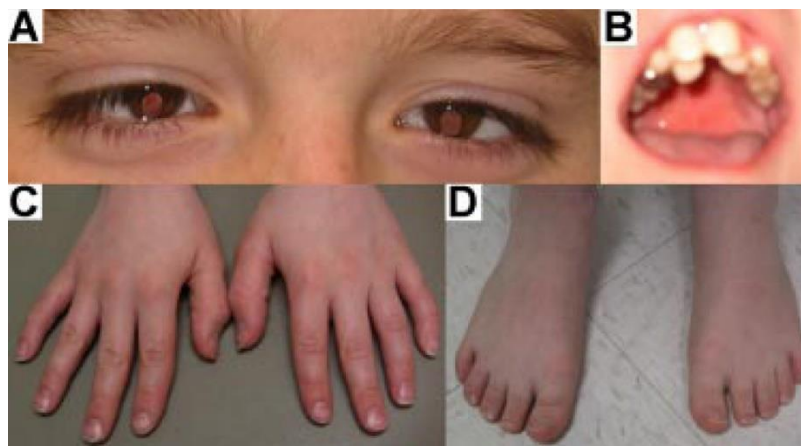
Using array CGH, Cardoso et al (2009) identified a deletion of chromosome 5q14.3q21 in 3 unrelated patients with periventricular heterotopia. These

deletions ranged in size from 6.3 to 17 Mb and included a common region of 5.8 Mb. Computational critical region analysis identified 14 candidate genes [1,2].

**Figure 2: Schematic of the distal deletion mutation of chromosome 5q14.3 [1].**

Sobreira et al (2009) identified a 7.4 Mb deletion of chromosome 5 at 5q14.3-q21 in an 11-year-old boy with mental retardation, bilateral iris coloboma, hearing loss, dental malformation, and facial deformity. features, but without periventricular heterotopia, which Sobreira et al. (2009) referred to the report by Cardoso et al., who identified a deletion region in the overlapping region

of 5q14 in patients with periventricular heterotopia. One of these patients had a unilateral coloboma and shared part of the deletion with the patient reported by Sobreira et al. Comparison of the shared deletion regions between the 2 patients revealed a 2.6 Mbp putative region for coloboma and a 1.84 Mbp putative region for periventricular heterotopia [1,3].

**Figure 3: Another view of a child with distal chromosome 5q14.3 deletion syndrome [1].**

Le Meur et al (2010) reported 5 unrelated children with severe mental retardation, absent speech and stereotyped movements, each with deletions between different regions of chromosome 5q14 ranging in size from 216 kb to 8.8 Mb. The minimal common deletion region contained only the MEF2C gene. Le Meur et al (2010) noted that the 5q14 region partially overlapped with that deleted in patients with periventricular heterotopia reported by Cardoso et al. But only 1 of those patients has deleted the MEF2C gene. Furthermore, none of the patients reported by Le Meur et al (2010) had periventricular heterotopia [1,4].

Al-Kateb et al. (2013) reported an 8-year-old boy with a de novo deletion of 582 kb on chromosome 5q15, involving 5 genes. They compared their patient's findings with those of 3 patients reported by Cardoso et al. All of them had a minimum overlapping region of about 230 kb including 2 genes: FLJ42709 and NR2F1. All 5 patients had growth delay and facial deformities, 4 had hypotonia and 3 had eye abnormalities. Urinary tract obstruction was observed only in their patient. Periventricular heterotopia was also present only in the patients reported by Cardoso et al. Al-Kateb et al. (2013) stated that NR2F1 is the strongest candidate gene for overlapping phenotypes. Heterozygous mutations in the NR2F1 gene have been

identified in patients with Bosch-Boostra-Schaaf optic atrophy syndrome, which is characterized by developmental delay, moderate mental retardation, and visual atrophy [1,5].

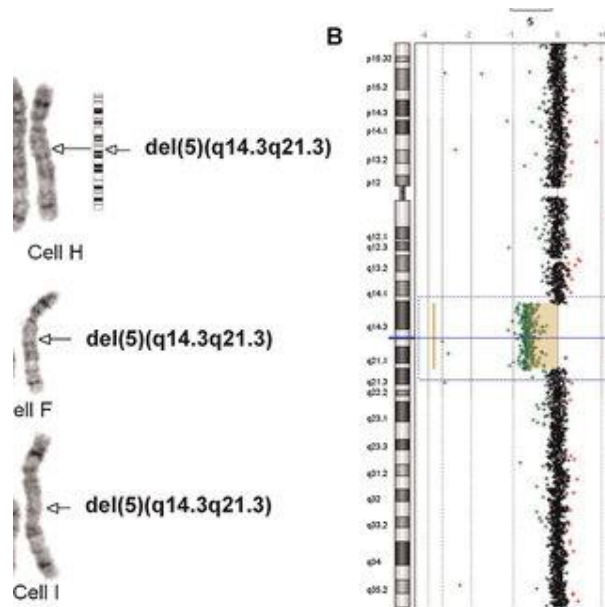


Figure 4: Schematic of the distal deletion mutation in the long arm of chromosome 5 [1].

References

1. Asadi S, The Book of Human Abnormality Chromosome, Amidid Publications, IRAN 2022.
2. Brown, K. K., Alkuraya, F. S., Matos, M., Robertson, R. L., Kimonis, V. E., Morton, C. C. (2009). NR2F1 deletion in a patient with a de novo paracentric inversion, inv(5)(q15q33.2), and syndromic deafness. *Am. J. Med. Genet.* 149A: 931-938.
3. Cardoso, C., Boys, A., Parrini, E., Mignon-Ravix, C., McMahon, J. M., Khantane, S., Bertini, E., Pallesi, E., Missirian, C., Zuffardi, O., Novara, F., Villard, L., Giglio, S., Chabrol, B., Slater, H. R., Moncla, A., Scheffer, I. E., Guerrini, R. (2009). Periventricular heterotopia, mental retardation, and epilepsy associated with 5q14.3-q15 deletion. *Neurology* 72: 784-792.
4. Le Meur, N., Holder-Espinasse, M., Jaillard, S., Goldenberg, A., Joriot, S., Amati-Bonneau, P., Guichet, A., Barth, M., Charollais, A., Journel, H., Auvin, S., Boucher, C., Kerckaert, J.-P., David, V., Manouvrier-Hanu, S., Saugier-veber, P., Frebourg, T., Dubourg, C., Andrieux, J., (2010). Bonneau, D. MEF2C haploinsufficiency caused by either microdeletion of the 5q14.3 region or mutation is responsible for severe mental retardation with stereotypic movements, epilepsy and/or cerebral malformations. *J. Med. Genet.* 47: 22-29.
5. Sobreira, N., Walsh, M. F., Batista, D., (2009). Wang, T. Interstitial deletion 5q14.3-q21 associated with iris coloboma, hearing loss, dental anomaly, moderate intellectual disability, and attention deficit and hyperactivity disorder. *Am. J. Med. Genet.* 149A: 2581-2583.



This work is licensed under Creative Commons Attribution 4.0 License

To Submit Your Article Click Here: [Submit Manuscript](#)

DOI:[10.31579/2692-9392/164](https://doi.org/10.31579/2692-9392/164)

Ready to submit your research? Choose Auctores and benefit from:

- ❖ fast, convenient online submission
- ❖ rigorous peer review by experienced research in your field
- ❖ rapid publication on acceptance
- ❖ authors retain copyrights
- ❖ unique DOI for all articles
- ❖ immediate, unrestricted online access

At Auctores, research is always in progress.

Learn more www.auctoresonline.org/journals/archives-of-medical-case-reports-and-case-study