

# Case Report of New Technique for the Repair of Iatrogenic Femoral Pseudoaneurysm

**Mohammed Habib \***

Head of Cardiology department, Alshifa Hospital, Gaza, Palestine, A.Professor, Faculty of Medicine, IU Gaza , Palsetine.

**\*Corresponding Author:** Mohammed Habib, Head of Cardiology department, Alshifa Hospital, Gaza, Palestine, A.Professor, Faculty of Medicine, IU Gaza , Palsetine.

**Received Date:** January 27, 2023 | **Accepted Date:** February 01, 2023 | **Published Date:** February 15, 2023

**Citation:** Mohammed Habib, (2023), Case Report of New Technique for the Repair of Iatrogenic Femoral Pseudoaneurysm. *International Journal of Clinical Case Reports and Reviews*. 13(2); DOI: 10.31579/2690-4861/292

**Copyright:** © 2023 Mohammed Habib, This is an open-access article distributed under the terms of the Creative Commons Attribution License, which permits unrestricted use, distribution, and reproduction in any medium, provided the original author and source are credited.

## Abstract:

Femoral artery Pseudoaneurysm was caused at the puncture site of the right groin after diagnostic coronary angiography. Manual compression for 48 hours was administrated but failed then balloon tamponade was attempted for hemostasis at the aneurysmal site but hemostasis was not achieved. Next, using contralateral antegrade approach was use to cross the wire from the neck of the pseudoaneurysm and ipsilateral retrograde approach by direct puncture of the pseudoaneurysm was tried. A 0.014-inch guidewire was crossed from the neck of the pseudoaneurysm to the external iliac artery. The wire was replaced with a 0.035-inch guidewire. A star close device was inserted and was deployed at the neck of the pseudoaneurysm. Final angiography revealed completion of hemostasis.

**Key words:** femoral artery pseudoaneurysm; star close

## Introduction

Femoral artery access is the most common approach for diagnostic and therapeutic coronary intervention. However, puncture site complications, such as Fistula, bleeding, hematoma and pseudoaneurysm may occur [1]. Pseudoaneurysm is the most common femoral access complication following coronary and peripheral angiography and/or angioplasty, incidence ranges from 0.2% to 8% [2]. Risk factors include antiplatelet agents, anticoagulants, larger sheath size, puncture site below common femoral artery, and emergency procedures.

Symptoms may include groin swelling, unusual pain, bruising, skin changes, neuropathy from femoral nerve compression, and, rarely, limb ischemia or claudication from embolization or arterial compression. Rupture can be associated with severe pain and hemodynamic instability. Hence, interventional cardiologists should be familiar with management. The most common nonsurgical treatment options are duplex ultrasound-guided compression, duplex ultrasound-guided Sealing pseudoaneurysms of the femoral artery with saline injection and duplex ultrasound-guided thrombin injection, which are widely used and fairly successful [3]. However, a novel approach with suture-based closure devices to treat pseudoaneurysms was recently reported.4 In this case report, we describe the off-label use and the long-term outcome of the Angio-Seal vascular closure device to repair a femoral pseudoaneurysm. We use new technique by using star close device with contralateral and ipsilateral approach to close the neck of the femoral pseudoaneurysm. obtained informed consent of the patient for publication of this case report.

## Case report

A 42-year-old male who underwent angiography with no obstructive disease found. he was discharged home on the same day but returned to the hospital for Symptoms include groin swelling, unusual pain, bruising, skin changes, neuropathy from femoral nerve compression and claudication from embolization or arterial compression. On examination pulsatile mass in his right groin with a bruit. Angio CT suggested large pseudoaneurysm 7x8 cm in right femoral artery (figure1). Angiography to his right common femoral artery revealed large pseudoaneurysm [2]. With a contralateral sheath placed in the left common femoral artery, the pseudoaneurysm was entered through the neck using 0.014-inch coronary wire. A micro introducer needle was then used to enter the pseudoaneurysm A 0.014-inch wire was then advanced through the neck of the pseudoaneurysm retrogradely into the external iliac artery. The micro introducer sheath was then advanced into the pseudoaneurysm over the wire and retrogradely into the external iliac artery. The 0.014-inch wire was exchanged with a 0.035-inch Whole wire. The star closure device was then deployed with the anchor against the pseudoaneurysm neck with subsequent thrombosis of the pseudoaneurysm (figure 3). Control Angiography through the contralateral sheath showed complete occlusion of the neck with no compromise to the common femoral artery.

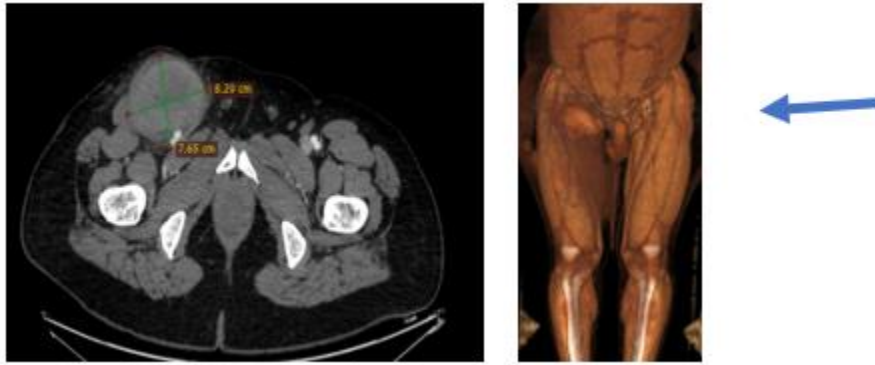


Figure 1: CT angiography: large pseudoaneurysm in right femoral artery

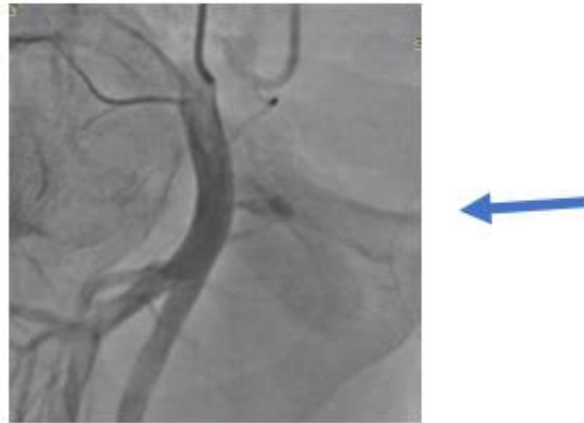

Figure 2 Selective angiography: pseudoaneurysm in right femoral artery

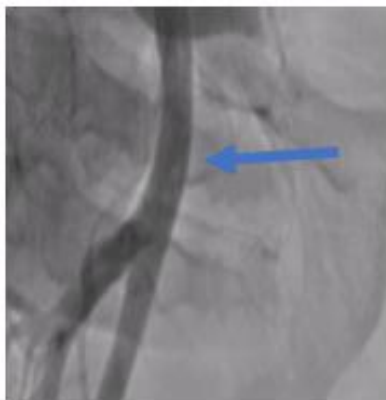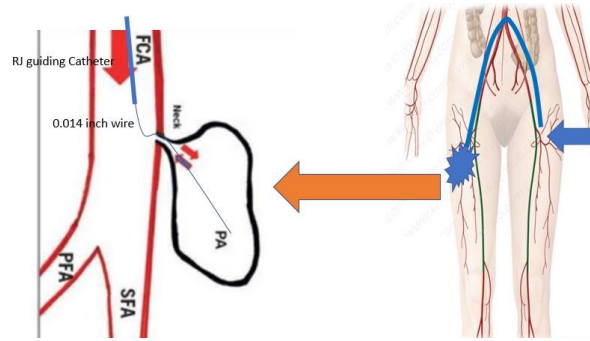


Figure 3: after star close deployment, totally occlusion in pseudoaneurysm neck

In this case, a novel approach to close an iatrogenic pseudoaneurysm using the star closure device. This alternative method is likely to be useful in the setting of a large pseudoaneurysm (> 3 mm) with a neck diameter less than 5 mm.

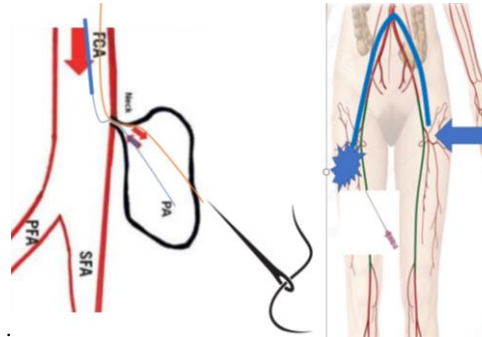
The Alshifa Hospital new technique of treatment for femoral artery pseudoaneurysm involved 4 steps to closure the neck of femoral artery pseudoaneurysm.

1. contralateral antegrade via 3.5,6 French right Judkins guiding catheter 0.014-inch wire insertion into the femoral artery pseudoaneurysm. (Figure 4)



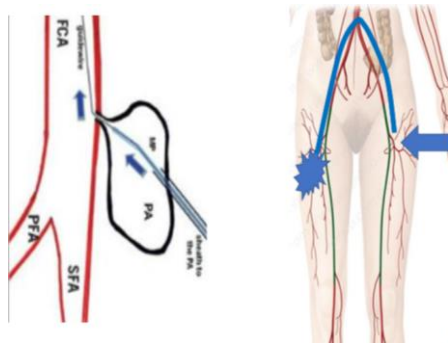
**Figure 4:** SFA: superficial femoral artery, PFA: deep femoral artery, FCA: Common femoral artery, PA: Pseudoaneurysm

2. ipsilateral retrograde via direct puncture 0.014-inch wire insertion into the external iliac artery through neck of pseudoaneurysm (figure 5)



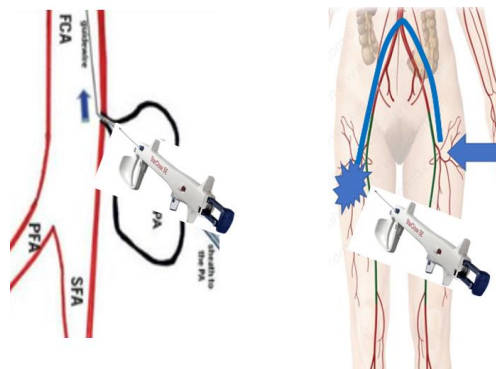
**Figure 5:** SFA: superficial femoral artery, PFA: deep femoral artery, FCA: Common femoral artery, PA: Pseudoaneurysm

3. The 0.014-inch wire was exchanged with a 0.035-inch Whole wire. The introducer sheath was then advanced into the pseudoaneurysm over the wire and retrogradely into the external iliac artery (figure 6)



**Figure 6:** SFA: superficial femoral artery, PFA: deep femoral artery, FCA: Common femoral artery, PA: Pseudoaneurysm

4. The (star close device/ or Angio cell device) was then deployed with the anchor against the pseudoaneurysm neck with subsequent thrombosis of the pseudoaneurysm (figure 7)



**Figure 7:** SFA: superficial femoral artery, PFA: deep femoral artery, FCA: Common femoral artery, PA: Pseudoaneurysm

## Discussion

Femoral artery pseudoaneurysm is the most common complication of coronary and peripheral intervention. the incidence of pseudoaneurysm at 0.2% to 0.5% following diagnostic procedures and up to 8% following procedures with an intervention [2]. Conservative management is an option for some patients with small femoral artery pseudoaneurysms.

ultrasound-guided compression was used to treat pseudoaneurysms, replacing surgical procedures for many pseudoaneurysms and reporting an early success rate of 63% to 88% [4]. Ultrasound-guided thrombin injection has replaced ultrasound-guided compression in most practices. Injection has a success rate of 93% to 97%, compared with 63% to 88% for ultrasound-guided compression. Complications of ultrasound-guided thrombin injection are rare (1.2%), with the most common being distal embolization (0.5%) [5].

Patients with large hematomas resulting in compressive symptoms such as neuropathy or ischemia and infected pseudoaneurysms are best treated with surgical repair. Surgical treatment carries a significant complication rate of 20% [6].

## Conclusion:

Our new technique has several advantages. high success rate and the most patients who are currently undergoing treatment with oral anticoagulants and antiplatelet agents can be successfully treated because the vascular closure device is effective independent of concomitant medications. However, we believe that this technique may be superior to thrombin injection because potential complications that might occur with thrombin

injection, such as peripheral embolism of thrombin or anaphylactic reactions, are avoided, and it is less invasive than open repair.

## Funding

This article's completion was not supported by any money.

## Conflicts of interest

The author has no financial or non-financial interests to report.

## References

1. Bhat FA, Changal KH, Raina H, Trambo NA, Rather HA. (2017). Transradial versus transfemoral approach for coronary angiography and angioplastyda prospective, randomized comparison. *BMC Cardiovasc Dis*, 17:23.
2. Schneider C, Malisius R, K uchler R, et al. (2009). A prospective study on ultrasound-guided percutaneous thrombin injection for treatment of iatrogenic post-catheterisation femoral pseudoaneurysms. *Int J Cardiol*. 131(3):356-361.
3. Morgan R, Belli AM. (2003). Current treatment methods for postcatheterization pseudoaneurysms. *J Vasc Interv Radiol*. 14(6):697-710.
4. Taylor BS, Rhee RY, Muluk S, et al. (1999). Thrombin injection versus compression of femoral artery pseudoaneurysms. *J Vasc Surg*. 30(6):1052-1059.
5. Webber GW, Jang J, Gustavson S, Olin JW. (2007). Contemporary management of postcatheterization pseudoaneurysms. *Circulation*. 115(20):2666-2674.



This work is licensed under Creative Commons Attribution 4.0 License

To Submit Your Article Click Here:

[Submit Manuscript](#)

DOI: [10.31579/2690-4861/292](https://doi.org/10.31579/2690-4861/292)

### Ready to submit your research? Choose Auctores and benefit from:

- fast, convenient online submission
- rigorous peer review by experienced research in your field
- rapid publication on acceptance
- authors retain copyrights
- unique DOI for all articles
- immediate, unrestricted online access

At Auctores, research is always in progress.

Learn more <https://auctoresonline.org/journals/international-journal-of-clinical-case-reports-and-reviews->