

Benign Mixed Tumor of Submandibular Salivary Gland: An Atypical Instance

Pankaj Goyal^{1*}, Kishan Kumawat¹

¹Apollo ENT Hospital, Tiwari Tower, Near passport office, Pal road, Jodhpur, Rajasthan, India.

***Corresponding Author:** Pankaj Goyal, Apollo ENT Hospital, Tiwari Tower, Near passport office, Pal road, Jodhpur, Rajasthan, India.

Received Date: January 23, 2023; **Accepted Date:** January 30, 2023; **Published Date:** February 07, 2023

Citation: Pankaj Goyal and Kishan Kumawat, (2023) Benign Mixed Tumor of Submandibular Salivary Gland: An Atypical Instance. *J. Journal of Clinical Otorhinolaryngology*. 5(3); DOI:10.31579/2692-9562/082

Copyright: © 2023 Pankaj Goyal, this is an open-access article distributed under the terms of the Creative Commons Attribution License, which permits unrestricted use, distribution, and reproduction in any medium, provided the original author and source are credited.

Abstract

Salivary gland neoplasm is rare entity in head and neck region, out of that pleomorphic adenoma is most common benign tumor. Submandibular gland is very unusual site for its occurrence while the parotid gland is the most prominent location. Here, we are presenting a case report of a twenty-eight-year-old female patient with a swelling at right submandibular region which was managed by surgical excision.

Key words: salivary gland neoplasm; pleomorphic adenoma; submandibular gland; benign

Introduction

Salivary gland neoplasm is uncommon. Most tumors that come from the parotid gland, are benign in comparison with the submandibular gland. Pleomorphic adenoma or benign mixed tumor is usually the most common. But not an ordinary presentation in the submandibular area. Once diagnosis is made, surgical excision will be the treatment of choice. There is a chance that it can turn into malignancy [1,2] and this requires a histopathological correlation.

Case Report:

A twenty-eight-year-old female patient who came to our hospital with a history of painless swelling on her right neck (figure 1) for about a year and a half. The swelling, has steadily increased during the period. There was no history of dysphagia, odynophagia, difficulty opening her mouth, fever, or trauma. She denied any substance abuse. There were no co-morbidities. She

took certain medications prescribed by her physician, but was not relieved. During the examination, the patient displayed approximately 4 x 2 cm swelling in the right submandibular area. It was soft, cystic, non-fluctuant, non-tender, slightly mobile. The skin over swelling is pinchable. There were no scars or sinuses in this area. There were no restrictions on neck movements. On bimanual palpation, there was no swelling present in the oral cavity. On Computed tomography scan (figure 2), it was revealed as well circumscribed rounded mass in the right submandibular region. Fine Needle Aspiration Cytology (F.N.A.C.) reported it as pleomorphic adenoma. After taking proper consent, patient is posted for surgical excision. The swelling was removed completely with preservation of marginal mandibular branch of facial nerve. Post operative uneventful. On histopathological report, it was concluded as pleomorphic adenoma. Patient was doing well during follow-up.

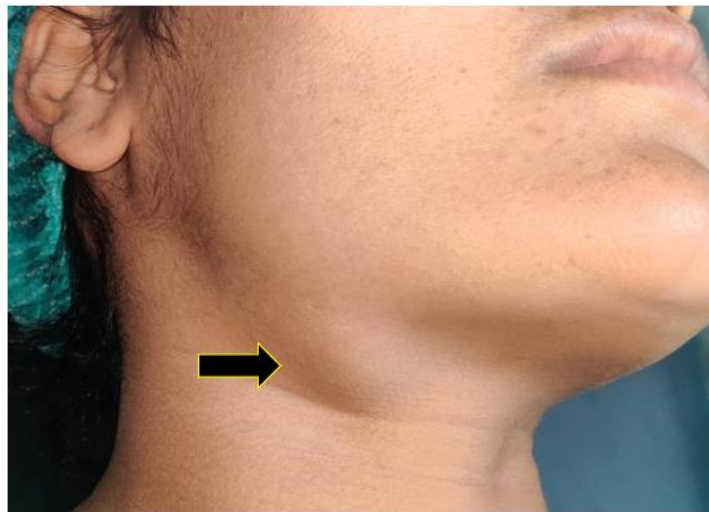


Figure 1: Clinical picture showing right submandibular swelling

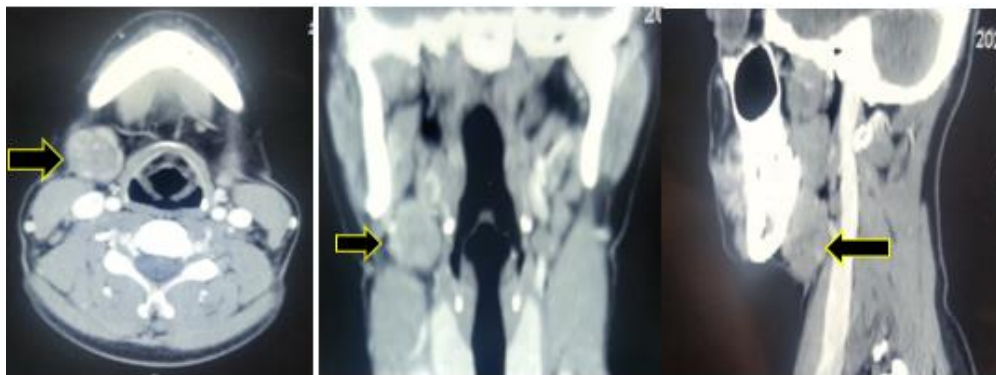


Figure 2: CT scan (axial, coronal and sagittal view) showing well defined round shaped mass at the right submandibular region without any invasion in surrounding structures.

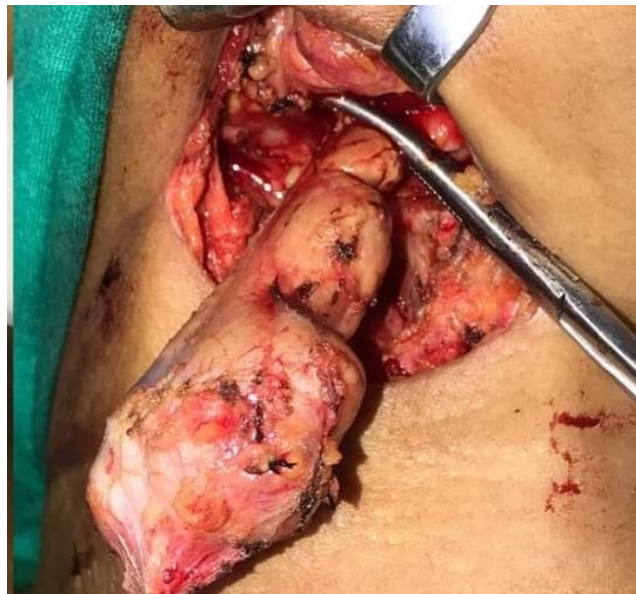

Figure 3: Intraoperative picture showing well defined cystic swelling of submandibular gland with pseudopodial extension.

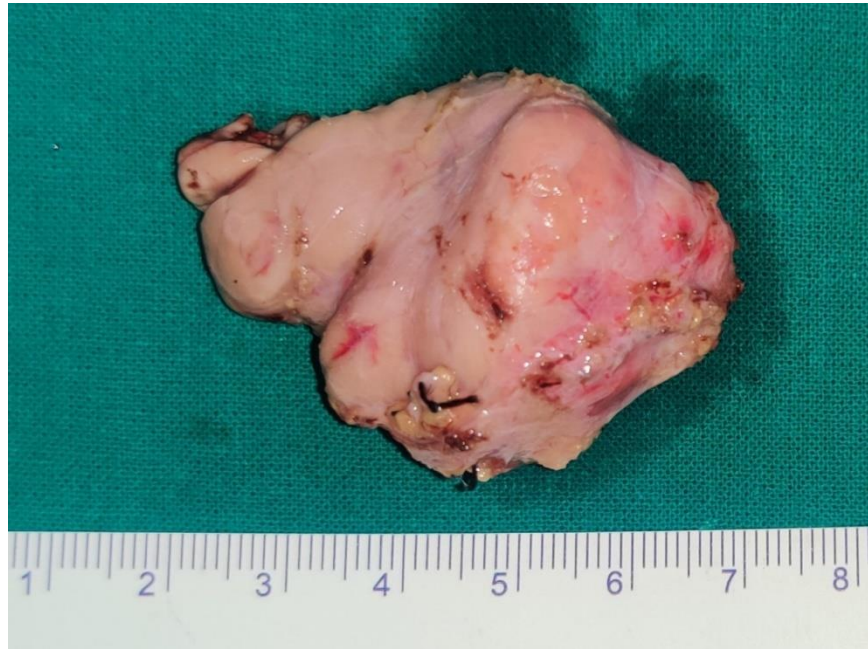

Figure 4: Surgical specimen

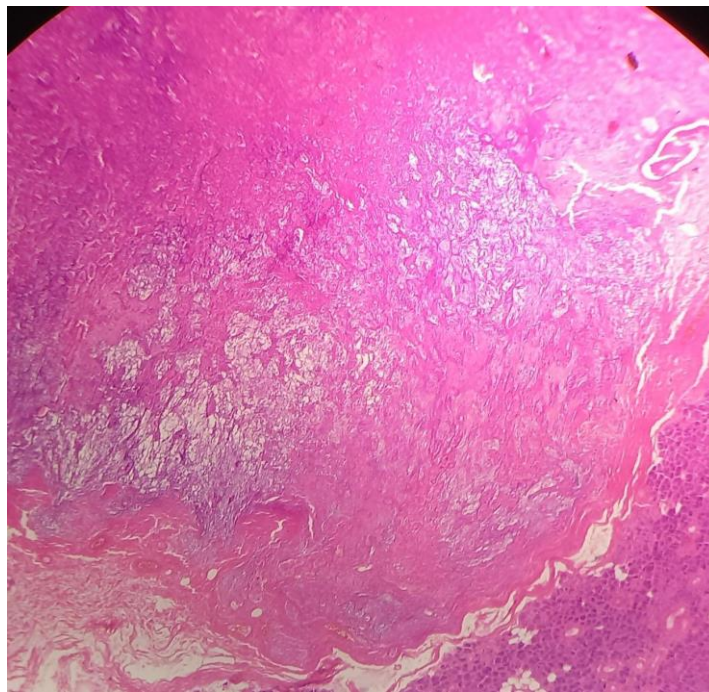


Figure 5: Histopathological slide

Discussion:

Neoplasms in the submandibular gland are rare. This results in the relative absence of reports of large series of patients in the literature. Benign tumors represent 85% of parotid lesions, while malignant tumors are more frequent in the submandibular gland (up to 80% of cases). [3] Tumor-related inflammatory conditions are more common in the submandibular gland than in the parotid gland. Pleomorphic adenomas must be carefully managed for their ability to reproduce and undergo malignant transformation. The primary risk factor for recurrence is the rupture of the capsule and the subsequent release of a tumour during excision. The potential for malignant

change was reported to be as high as 10%. Predictive characteristics of malignant change include age, tumor size, long history of swelling, submandibular location, and the presence of hyalinized stroma [4]. Surgery is the preferred method of treating benign submandibular gland neoplasm. It is always necessary to remove both the gland and the tumour [5-7].

Conclusion:

Due to their rarity and requirement for a complete examination by a multidisciplinary team of doctors, salivary gland tumours are best addressed

in specialised head and neck clinics. Since surgery can be used for both diagnostic and therapeutic objectives, it serves as the cornerstone of their management. The surgical planning and preoperative counselling are the most crucial steps. Careful preoperative evaluation and the cytopathologic diagnosis of the tumour are crucial for safe and effective treatment because of the similarities in the symptomatology and clinical presentation of benign and malignant tumours [8].

Compliance with Ethical Standards:

The procedure performed in this case report was in accordance with the ethical standards of the institutional and/or national research committee and with the 1964 Helsinki declaration and its later amendments or comparable ethical standards.

Funding:

This study is not funded by any resources.

Conflict of Interest:

The author (s) declares no potential conflicts of interest with respect to the research, authorship, and/or publication of this paper.

Ethical Approval:

The study was published with the written consent of the patient.

References:

1. Civelek S, Ercan B, Cakir B, Basak T, Turgut S. Malignant Myoepithelial Carcinoma Arising in A Pleomorphic Adenoma of The Submandibular Gland. KBB-Forum. 2006; 5(4).
2. Mubeen K, Vijayalakshmi K, Abhisek R, Girish B, Singh C. Benign Pleomorphic Adenoma of Minor Salivary Gland of Palate. Journal of Dentistry and Oral Hygiene. 2011; 3(6):82-88.
3. Weber RS, Byers RM, Petit B, et al: Submandibular gland tumors. Adverse histologic factors and therapeutic implications. Arch Otolaryngol Head Neck Surg 116:1055, 1990
4. R. J. Zarbo, "Salivary gland neoplasia: a review for the practicing pathologist," Modern Pathology, vol. 15, no. 3, pp. 298-323, 2002.
5. Sykes AJ, Slevin NJ, Birzgalis AR, et al: Submandibular gland carcinoma; an audit of local control and survival following adjuvant radiotherapy. Oral Oncol 35:187, 1999
6. Laskawi R, Ellies M, Arglebe C, et al: Surgical management of benign tumors of the submandibular gland: A follow-up study. J Oral Maxillofac Surg 53:506, 1995
7. Yasumoto M, Shibuya H, Suzuki S, et al: Computed tomography and ultrasonography in submandibular tumors. Clin Radiol 46: 114, 1992
8. Daskalopoulou D, Rapidis AD, Maounis N, et al: Fine-needle aspiration cytology in tumors and tumor-like conditions of the oral and maxillofacial region. Diagnostic reliability and limitations. Cancer 81:238, 1997



This work is licensed under Creative Commons Attribution 4.0 License

To Submit Your Article Click Here:

Submit Manuscript

DOI: [10.31579/2692-9562/082](https://doi.org/10.31579/2692-9562/082)

Ready to submit your research? Choose Auctores and benefit from:

- fast, convenient online submission
- rigorous peer review by experienced research in your field
- rapid publication on acceptance
- authors retain copyrights
- unique DOI for all articles
- immediate, unrestricted online access

At Auctores, research is always in progress.

Learn more <https://www.auctoresonline.org/journals/biomedical-research-and-clinical-reviews->