

Ovarian Torsion no Age Is Exempt Conservative Management Should Always Be the Rule Case Series

Kariman Ghazal ^{1,2,3*}, Charlotte El Hajjar ^{2,3}, Jihad Al Hasan ^{1,3,5}, Zaynab Kalach ^{2,4}, Georges Yared ^{6,7}

¹ Assistant Professor Obstetrics and Gynaecology Department, Lebanese University, Beirut, Lebanon.

² Obstetrics and Gynaecology Department, Al Zahraa Hospital University Medical Centre, Beirut, Lebanon.

³ Obstetrics and Gynaecology Department, Rafik Hariri Hospital University Medical Center, Beirut, Lebanon.

⁴ Obstetrics and Gynaecology Department, Lebanese University, Lebanon Al Zahraa Hospital University Medical Centre, Beirut, Lebanon.

⁵ Obstetrics and Gynaecology Department, Arabic University, Beirut, Lebanon.

⁶ Head of Obstetrics and Gynaecology Department, Al Zahraa Hospital University Medical Centre, Beirut, Lebanon

***Corresponding Author:** Kariman Ghazal, Assistant Professor Obstetrics and Gynaecology Department, Lebanese University, Beirut, Lebanon.

Received date: November 11, 2022; **Accepted date:** December 12, 2022; **Published date:** January 03, 2023

Citation: Kariman Ghazal, Charlotte El Hajjar, Zaynab Kalach, Jihad Al Hasan. (2023) Ovarian Torsion no Age Is Exempt Conservative Management Should Always Be the Rule Case Series. *J. Women Health Care and Issues*. 5(6); DOI:10.31579/2642-9756/134

Copyright: © 2023 Kariman Ghazal, This is an open access article distributed under the Creative Commons Attribution License, which permits unrestricted use, distribution, and reproduction in any medium, provided the original work is properly cited.

Abstract

Women of all ages can experience ovarian torsion, which is a common gynecological emergency with a peak occurrence around the age of 30. Ovulation induction, ovarian hyperstimulation syndrome, larger ovaries brought on by ovarian cysts, and pregnancy are all risk factors. The majority of diagnoses are made through clinical means, with laboratory and imaging tests adding to the evidence. Although there is a tendency toward preserving ovarian tissue with a mix of detorsion, ovarian cystectomy, and oophoropexy, the mainstay of current care is oophorectomy. There is mounting proof that ovaries with a necrotic appearance that do not appear to heal right away after detorsion may nonetheless be functional in the long run. Additionally, it appears that a policy of ovarian conservation for all premenopausal women with ovarian torsion yields excellent results and low incidence of problems, indicating that post-menopausal women should be the main candidates for oophorectomy.

Key words: ovarian torsion; oophoropexy; conservative management; detorsion; oophorectomy

Introduction

Adnexal torsion is a gynecologic condition that can involve partial or complete rotation of the ovary and fallopian tube. It frequently affects the infundibulo-pelvic and utero-ovarian ligaments.

Adnexal torsion is one of the most frequent gynecologic crises. Age has no immunity to this condition, which can be detected at any age, and is thought to be the sixth most common gynecologic emergency. [1, 2]. Only 16% of occurrences of neonatal ovarian torsion occur in girls under the age of one [3, 4] are the most usually diagnosed prenatally and identified during the neonatal phase. [3] In the pediatric and teenage population, adnexal torsion makes up about 15% of all occurrences of torsion. 3 Children between the ages of 9 and 14 account for up to 52% of occurrences of torsion, having an 11-year-old median age [1, 4] Ovarian torsion appears to occur most frequently in women who are around 30 years old and are of reproductive age. [5, 6, 7]

Pain, nausea, and vomiting are the most typical presenting symptoms [1, 2]. A palpable abdominal mass will be present in between 60 and 80 percent of individuals. There may be leucocytosis and low-grade fever. [3, 4]. Although adnexal torsion is more frequently diagnosed correctly in pregnant women than in non-pregnant ones, clinical diagnosis accuracy is poor [2, 3]. Torsion diagnosis is typically aided by ultrasound imaging. Doppler sonography can also be used to show anomalies in ovarian perfusion [5, 6]. Torsion is not excluded from normal blood flow, and other ovarian disorders can also cause a lack of flow. Magnetic resonance imaging (MRI) can be used to evaluate ovarian viability in torsion instances. [7, 8]. Right-side adnexal torsion is more frequent [1, 4]. Torsion can happen in an adnexa that appears to be normal, especially in youngsters, despite the fact that an ovarian tumor is generally thought to be the triggering factor. Para-ovarian and para-tubal masses are most frequently found when an adnexal abnormality is present. [7, 8]. Adnexal torsion has traditionally been treated by surgically removing the afflicted component, typically during a laparotomy In pediatric situations, a

more cautious surgical method of unwinding the torsion has been extensively described. Despite reports of torsion therapy using this method being successful in the adult population, many surgeons are still hesitant to try ovarian preserving surgery, especially when done laparoscopically [1].

The aim of our study to describe the clinical presentation, diagnosis, and treatment of adnexal torsion in the context of this manuscript, the authors present a review of the literature and a collection of 13 cases. This management strategy's benefits and drawbacks are examined.

Objective

To describe the clinical presentation, diagnosis, and treatment of adnexal torsion in the context of this manuscript, the authors present a review of the literature and a collection of 13 cases. This management strategy's benefits and drawbacks are examined.

Case 1

A 35-year-old lady G2P1 had a healthy pregnancy examination. The patient was referred for evaluation of a fetal intra-abdominal cyst at 32 weeks of gestation. During an ultrasound, a sizable (5 cm) cyst was seen in the fetus' lower abdomen. The cyst had a liquid and solid component and was hemorrhagic in nature (Figure 1). There were no anomalies, such as ascites or

pleural effusion. The external genitalia were normal. A 5-cm cystic mass on the right side of the upper fetal pelvis was visible on T2-weighted magnetic resonance imaging (MRI), just as it had been on ultrasonography. High signal strength was visible inside the bulk on both T1- and T2-weighted pictures. Hemorrhagic cyst was identified by the dorsal side of the cyst's thickness, which indicated a twist of the pedicle and an ovarian cyst. A female child was delivered via cesarean section at 37 weeks and 4 days of gestation (repeated cesarean section). Apgar score was 9 first minute, and the birth weight was 3208 g. The second day after birth, the baby's general health was excellent. Nevertheless, a newborn T2-weighted MRI revealed a probable right ovarian cyst with pedicle torsion. It was decided to perform surgery to release the torsion in order to protect the child's ovarian function. The next day, laparoscopic surgery was carried out while the patient was under general anesthesia. An ovarian cyst in the right had torsion of the pedicle, according to intraoperative observations. It was challenging to free the left fallopian tubal fimbria from its adhesion to the right ovarian cyst's torsion location. Right ovary that was twisted appeared to be ischemic-haemorrhagic. The left fallopian tube underwent adhesiolysis, while the right ovarian cyst had partial resection. Torsion was let go of. Pathologically, it was determined that the right ovarian cyst was hemorrhagic. The child's recent checkup revealed no ultrasound evidence of an ovarian cyst.

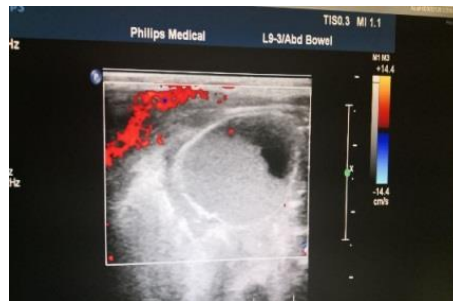


Figure 1. Fetal ultrasound image at 34 weeks of gestation.

The cyst measured 50 mm × 42 mm had solid fluid formation.

Case 2

A 7-year-old girl who is healthy and without any medical history was admitted to the emergency room with right lower quadrant pain that radiates to the groin and is accompanied by nausea. The pain is made worse by movement. She wasn't losing her appetite, and the pain wasn't constant. The patient had a left oophorectomy eight months prior for total necrosis of the torn left ovary. A right ovary with several tiny functioning follicles was seen to be enlarged during

transabdominal ultrasonography using Doppler. Ovarian vessel Doppler results were normal. When the patient had surgery, a Pfannentisel incision was made, and one loose torsion of the right ovary was discovered. Ovarian ligament to round ligament fixation with Vicryl 2/0 and manual detorsion of the right, orchepepsy were effective. (figure 2) The recovery process in the hospital was easy, and the patient's family and the patient received instructions for additional follow-up.

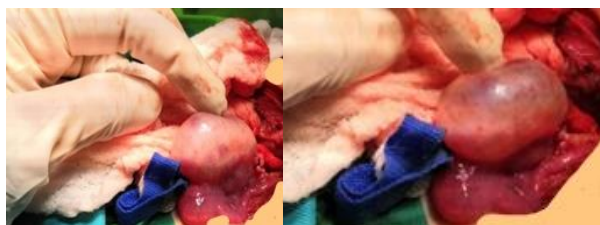

Figure 2: Right orchepepsy and manual detorsion, with the ovarian ligament, fixed to the round ligament.

Case 3

10-year-old girl presented with severe lower right abdominal pain started 1 months ago treated with pain killers not associated with genital or urinary

symptoms, no nausea, and vomiting, difficulty in walking. Doppler imaging showed outer flow with a negative core, and pelvic ultrasound revealed an enlarged, septated, right ovarian cyst with echogenic contents measuring 6.5

cm (Figure 3). The right adnexa's torsion was one of the laparotomic results. On physical examination the lower abdomen was soft with, with slight tenderness of the right adnexa. Ultrasound examination revealed an enlarged, septated, right

ovarian cyst 6,5 with echogenic contents, and Doppler imaging showing outside flow with negative center (Figure 3). Laparotomic findings included torsion of the right adnexa detorsion was done and right ovarian cystectomy was done (serous content) with hemostasis. Histology results confirmed the diagnosis cystoadenoma.

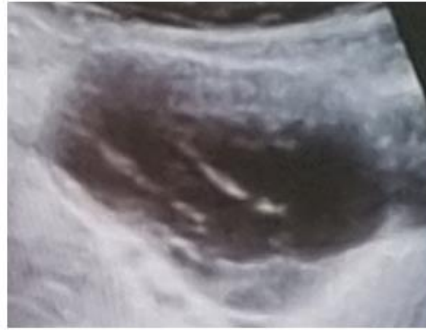


Figure 3: Pelvic ultrasound examination revealed an enlarged pelvic mass 6,5cm, septated, right ovarian cyst with echogenic contents.

Case 4

A 17-year-old girl presented with severe lower right abdominal pain associated with nausea, difficulty in walking, and irregular menstruation. On physical examination the lower abdomen was not soft, with slight tenderness of the right adnexa. Ultrasound examination revealed an enlarged,

hemorrhagic, torted right ovary and Doppler imaging showing outside flow with negative center (Figure 3). Laparotomic findings included torsion of the right adnexa with teratoma. The teratoma was removed and hemostasis was done (Figure 4). Histology results confirmed the diagnosis.

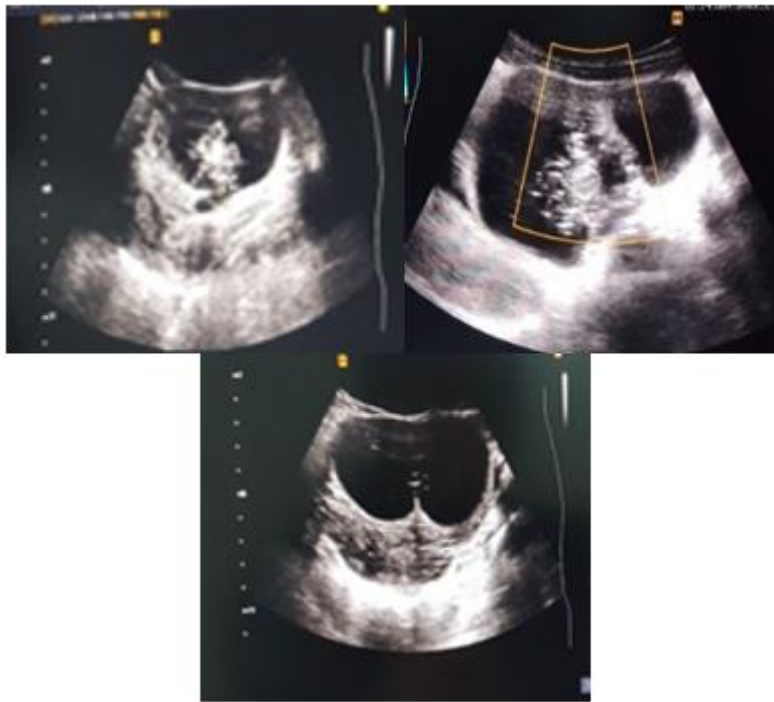


Figure 4: Ultrasound examination revealed large, heavy cysts (the string of pearls sign) and cystic teratomas. An enlarged, hemorrhagic, torted right ovary and Doppler imaging showing outside flow with negative center.

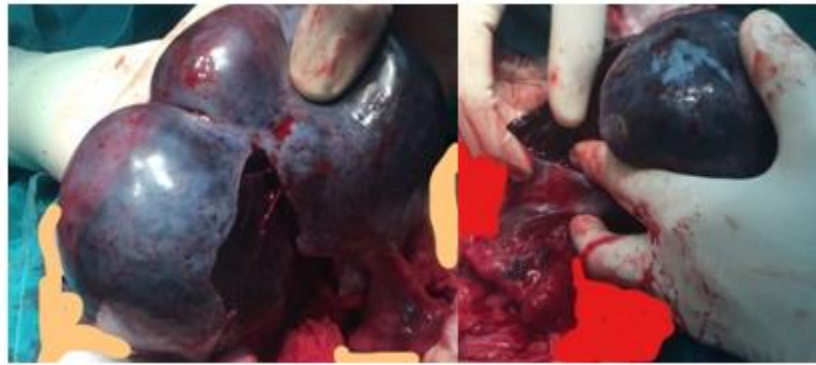


Figure 5: An enlarged, hemorrhagic, torsed right ovary (the string of pearls sign) can be seen with solid component confirmed histologically benign immature cystic teratomas; the cysts are unilateral in ovarian torsion with abnormal morphology of the ovary.

Case 5

A 18-year-old girl presented with severe lower right abdominal pain associated with nausea, difficulty in walking, and irregular menstruation. Physical examination revealed that the right adnexa was slightly painful but the lower abdomen was not soft. The right ovary was found to be swollen torn during ultrasound examination, and Doppler imaging showed outer flow with a negative core. On physical examination the lower abdomen was not

soft, with slight tenderness of the right adnexa. Ultrasound examination revealed an enlarged, torsed right ovary and Doppler imaging showing outside flow with negative center. Laparotomic findings included torsion of the right adnexa large teratoma covered completely the right ovary. The mass was removed oophorectomy and hemostasis was done (Figure 6). Histology results confirmed the diagnosis of teratoma.

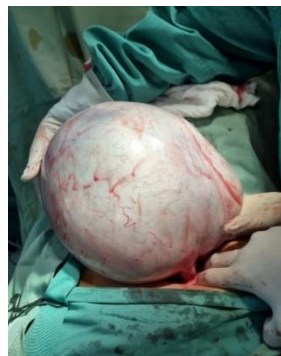

Figure 6: The right ovary was entirely covered by a large teratoma.

Case 6

A 23-year-old patient presented with severe lower right abdominal pain associated with nausea and vomiting, difficulty in walking. On physical examination the lower abdomen was not soft, with slight tenderness of the left mass. Pelvic ultrasound examination revealed an enlarged pelvic mass edema and Doppler imaging showed flow in the wall with negative intra-

cyst. Solid mass (3 cm) was found in the right ovary and another mass (3 cm) was found in the left ovary (Figure 7). Laparotomic findings included torsion of the right ovarian mass endometrioma multiple cyst endometriosises on the left and right ovary were removed, and hemostasis was done (Figure 8). Histology confirmed the diagnosis.

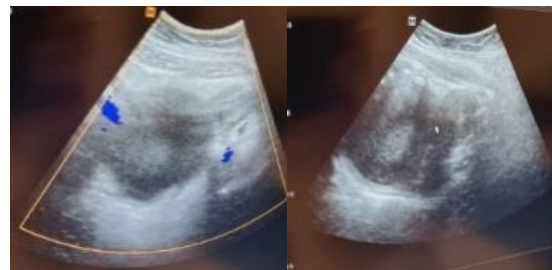


Figure 7: Pelvic ultrasound examination revealed an enlarged pelvic mass 6cm and Doppler imaging showed flow in the wall with negative intra-cyst. Solid mass (3 cm) was found in the right ovary and another mass (3 cm) was found in the left ovary.

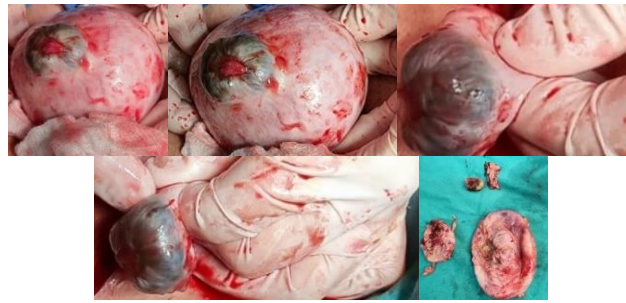


Figure 8. Laparoscopic findings included torsion of the ovarian mass endometrioma multiple cyst endometriomas were removed. Multiple cystectomy bilateral.

Case 7

A 24-year-old patient presented with severe lower right abdominal pain associated with nausea and vomiting, difficulty in walking, and irregular menstruation. A pelvic ultrasound indicated pelvic mass edema, and a flow in the wall with a negative intra-cyst on Doppler imaging. In the right ovary, a solid mass measuring 6 cm and in the left ovary, a mass measuring 3 cm, were discovered (Figure 9). Physical examination revealed that the right adnexa was painful. During ultrasound examination, the right ovary was found to be increase in volume torn and Doppler imaging showed outer flow

with a negative core. On physical examination the lower abdomen was not soft, with slight tenderness of the left mass. Pelvic ultrasound examination revealed an enlarged pelvic mass edema and Doppler imaging showed flow in the wall with negative intra-cyst. Solid mass (6 cm) was found in the right ovary and another mass (3 cm) was found in the left ovary (Figure 9). Laparoscopic findings included torsion of the paraovarian mass with teratoma and hemorrhagic cyst. The teratoma and hemorrhagic cyst were removed, and hemostasis was done (Figure 10). Histology confirmed the diagnosis.

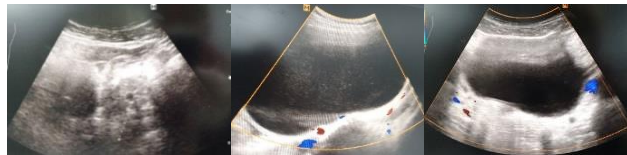


Figure 9. Pelvic ultrasound examination revealed an enlarged pelvic mass edema and Doppler imaging showed flow in the wall with negative intra-cyst. Solid mass (6 cm) was found in the right ovary and another mass (3 cm) was found in the left ovary.

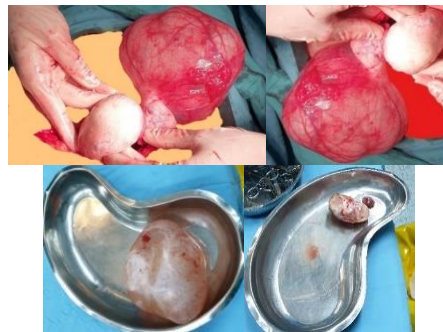

Figure 10: Large, heavy cystic neoplasms and torsioned paraovarian mass around tube with negative Doppler negative and unclear content teratoma and hemorrhagic cyst in the left.

Case 8

A 30-year-old woman nullipare, previously well, presented with lower abdominal pain of one day's duration with vomiting. She was not on medication at the time of presentation. An examination revealed an acute abdomen, localized peritonism in her lower abdomen and tachycardia of 100 beats per minute. Hematological investigations revealed a normal full blood count and normal serum amylase. A chest radiograph excluded free intraperitoneal gas. An ultrasound scan of her abdomen showed a thick-walled cyst in her pelvis of uncertain origin and a plain computed

tomography showed that the cyst, with calcified structures, originated from her right ovary. On laparoscopic examination under general anesthesia, we found a cyst attached to her right ovary, which had twisted 3 torsions (Figure 11). After clipping and disconnecting its pedicle from her ovary the cyst wall showed that it contained 200mL of thick, offensive milky brown fluid, hair and rudimentary teeth (Figure 12). Histological analysis of the cyst wall revealed that it was a benign teratoma. Our patient recovered well after surgery and was discharged home on the first postoperative day.

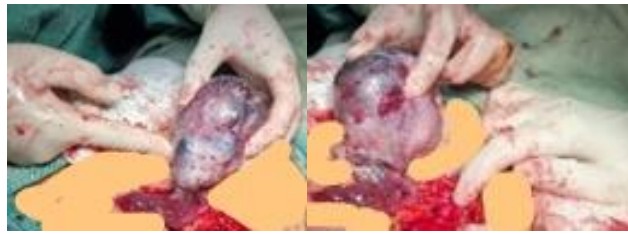

Figure 11: Acyst attached to her right ovary, which had twisted 3 torsions.

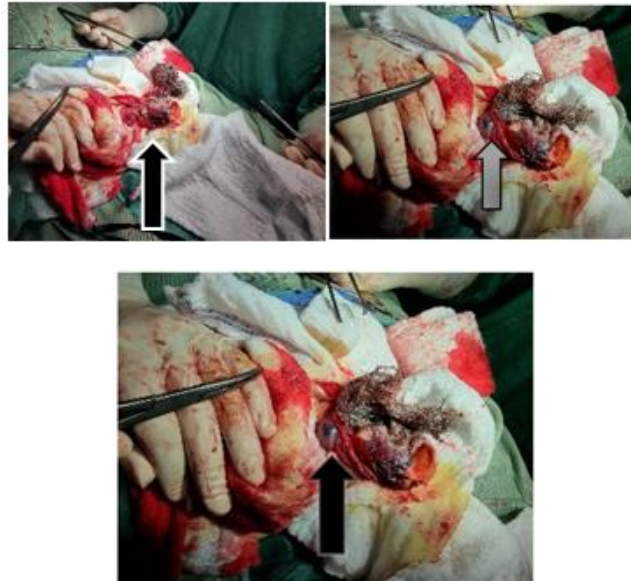
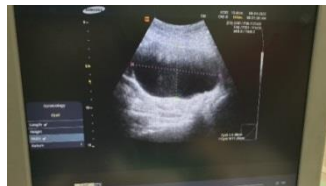

Figure 12: The contents of the removed cyst revealed rudimentary calcific teeth (solid black arrow), hair (solid white arrow) and sebaceous content (white outlined arrow).

Case 9

A 40-year-old patient G2P1A1 presented to the ER with severe lower right abdominal pain associated with nausea and vomiting, she mentioned on off pain of 8 days duration. Examining the lower abdomen revealed that it was not soft, albeit the left mass was slightly painful. A right-sided hydrosalpinx and a solid right ovarian lesion with a possible torsion sign were seen on the CT scan, which revealed no symptoms of appendicitis. On physical examination the lower abdomen was not soft, with slight tenderness of the

left mass. CT scan showed no signs of appendicitis, right sided hydrosalpinx with solid right ovarian lesion with suspect sign of torsion. Pelvic ultrasound examination revealed an enlarged pelvic mass edema and Doppler imaging showed flow in the wall with negative intra-cyst. Solid mass (6 cm) was found in the right ovary with torsion (Figure 13). Laparotomic findings included torsion of the mass with necrosis oophorectomy. Histology confirmed the diagnosis. of endometrioma (Figure 14).



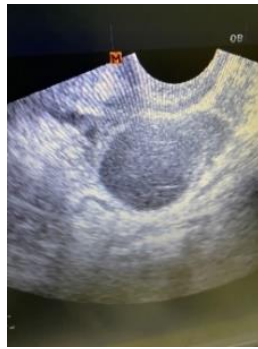

Figure 13: Pelvic ultrasound examination revealed an enlarged pelvic mass edema and Doppler imaging showed flow in the wall with negative intra-cyst.

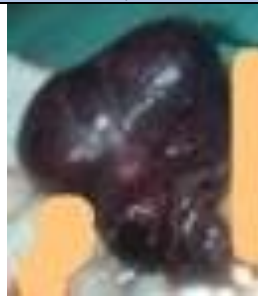

Figure 14: Torsion mass with necrosis.

Case 10

A 45-year-old woman G5P3 abortions 2) presented with severe lower right abdominal pain associated with nausea and difficulty in walking. On physical examination the lower abdomen was soft, with slight tenderness of the right adnexa. Ultrasound examination revealed an enlarged right ovary edema and Doppler imaging showed flow in the wall and negative center, and adnexal

torsion associated with simple ovarian cysts. Contralateral ovary was normal. Torted ovary was enlarged, edematous and less well defined (Figure 15). Laparotomic findings included torsion of the right adnexa with ovarian cyst. Hysterectomy and bilateral salpingectomy were done (Figure 16). Histology results showed endometrial hyperplasia with torted ovary.

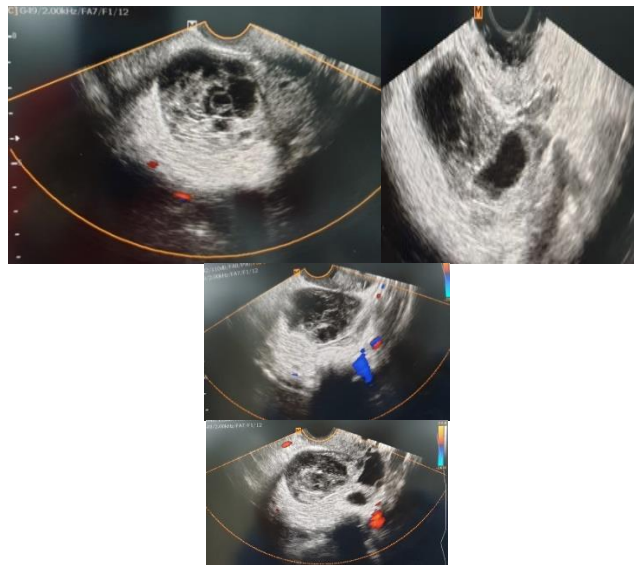


Figure 15: Pelvic and vaginal ultrasound images showing peripheral large heavy cysts (the string of pearls sign). The cysts are unilateral in ovarian torsion with abnormal morphology of the ovary (congested ovarian stroma). The “whirlpool” sign is visible as a clockwise or counter clockwise wrapping of the hypoechoic vessels around the central axis >

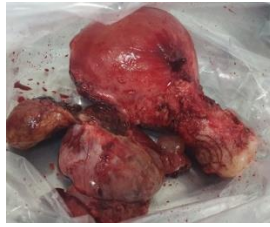

Figure 16. Histology results showed endometrial hyperplasia with torted ovary.

Case 11

A 50-year-old woman (gravida 3, para 3, abortions 0) menopause at 45 presented with severe lower right abdominal pain associated with nausea and difficulties moving forward. Upon physical examination, the right adnexa was painful and the abdomen was mushy. Ultrasound examination revealed

an enlarged right ovary edema and Doppler imaging showed flow in the wall and negative center, and adnexal torsion associated with ovarian cyst 9 cm. Contralateral ovary was normal. Tumor marker negative, 35 Torted ovary was enlarged, edematous and less well defined. Laparotomic findings included torsion of the right adnexa with ovarian cyst right oophorectomy. (Figure 17)

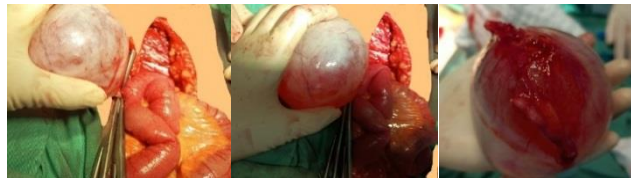

Figure 17. Laparotomic findings included torsion of the right adnexa with ovarian cyst right oophorectomy.

Case 12

The patient is a 40-year-old female who was admitted for left ovarian torsion at age 16 orchepepsy was performed for the left ovary, diabetes mellitus presented at 23 weeks for left ovarian torsion de novo, and the patient had

three bouts of ovarian torsion and detorsion in one month. admittance decision; during surgery, visualization of the uterus and the left necrotic adnexa; substantial adhesiolysis; left adnexectomy; and after waiting a set amount of time, the adnexa was still necrotic. (Figure 18)

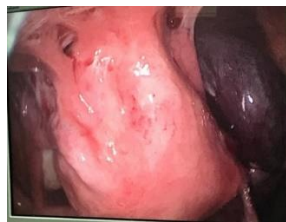
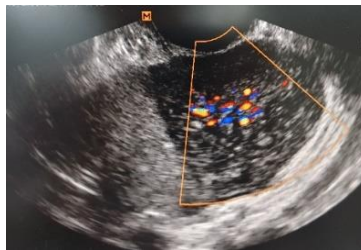
Figure 18. Left adnexectomy done after wait and the adnexa was still necrotic after a certain time.

Case 13

A 67-year-old woman (gravida 5, para 3, abortions 2) presented with lower right abdominal pain associated with nausea. On physical examination the lower abdomen was soft, with slight tenderness of the right adnexa. Ultrasound examination revealed a slightly enlarged right ovary with normal

appearance and Doppler imaging showed inside flow with echogenic side and presence of echogenic cyst. Laparotomic findings included torsion of the right adnexa with ovarian cyst. Hysterectomy and bilateral salpingectomy were done (Figure 19). Histology results were torted ovarian serous cystadenoma with atrophic endometrium. (Figure 20).



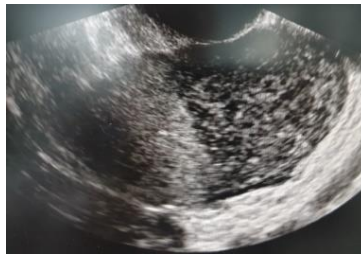


Figure 19. Vaginal ultrasound images showing large ovary (> 4 cm) torted with edema and positive Doppler intra-ovary.

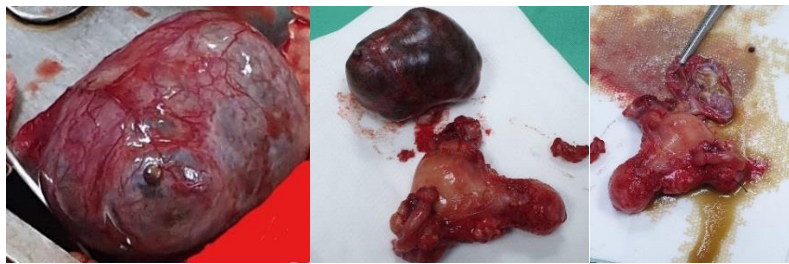


Figure 20: Surgery revealed ovarian serous cystadenoma torted with atrophic endometrium conformed histologically.

Discussion

Ovarian torsion can occur at any age. Fetal ovarian cysts (FOCs) detected in pregnancy have increased in frequency over the past ten years as a result of ultrasonography's accessibility and broad use. [9]. In comparison to the postnatal period, gestation and childbirth are the times when ovarian torsion occurs most commonly. Fetal ovarian cysts are the most prevalent abdominal tumors in fetuses and infants. [10]. Most of them are benign and go away a few months after birth. [10]. It affects 4.9 children out of every 100,000, according to reports. [10]. By Matthew F. Ryan et al. [11], ovarian torsion in a 5-year-old child was reported Naveen Poonai and colleagues evaluated cases of juvenile ovarian torsion retrospectively [12]. The preponderance of occurrences were, respectively, premenarchal or perimenarchal in age.

Young women between the ages of 20 and 30 are the most commonly affected with ovarian torsion. White M. et al. [13] carried out a retrospective investigation over a decade and discovered. With an interquartile range of 28.7 to 39.3 years, the mean age at presentation was 33.5 years. Similarly, Sahlou Z et al. [14].

In particular, postmenopausal women with ovarian masses are more prone to ovarian torsion. In a cross-sectional study by Zohreh Yousefi et al. [15] in 2015, the incidence was reported to be 22.6%, with a mean age of presentation of 59.8 years.

Here, we have described the ovarian torsion presentation in a variety of age groups, including 2 days, 7, 10, 11, 17, 18, 23, 24, 30, 40, 45, 50, and 65 years of age.

Torsion occurs unilaterally and on the right side in 70% of cases. The reasons for the more common occurrence on the right side include the longer utero-ovarian ligament on the right side and the restricted space on the left side due to the sigmoid colon. [15, 16]

Ten cases of torsion on the right side and two cases on the left were observed in our investigation.

Adnexa that are pathologically swollen are frequently associated with ovarian torsion. The abnormally inflated adnexa, which acts as a fulcrum around which the ovaries and duct revolve, causes ovarian torsion or, more frequently, impacts both the tubes and the ovaries, causing adnexal torsion.

Most people are in excruciating agony when they first come.

Analgesics are often unable to relieve this type of pain, which typically appears quickly, forcefully, or stabbingly and radiates to the back. gastrointestinal symptoms including nausea and vomiting. Low-grade fever may also be present. Abdominal discomfort is frequently felt on palpation. Most blood tests come back normal. However, at more advanced stages of inflammation, necrosis can lead to leukocytosis, an increase erythrocyte sedimentation rate, or an increase in C-reactive protein. [17] All of the individuals in our study also reported having severe abdominal pain. Leukocytosis and vomiting.

When abdominal discomfort is severe, ultrasound is typically the first imaging technique used. Heterogeneous ovarian stroma, the "string of pearls" sign, and free fluid in the cul de sac are ultrasonography symptoms of ovarian torsion, ovarian enlargement greater than 4 cm. Doppler examination of the ovarian arterial and venous waveforms. has a wide range of potential variations, including minimal or nonexistent intraovarian venous flow, absence of arterial flow, and absence or reversal of diastolic flow the existence of color flow Doppler imaging reveals that the ovary may be viable even though it does not allow the exclusion of torsion, particularly if the flow is centralized. The twisted vascular pedicle's lack of flow could be a sign that the ovary is not viable. [17-20]

Traditionally, salpingo-oophorectomy was recommended as the standard treatment for adnexal torsion due to fear of thromboembolism. But now, conservative treatment that consists of untwisting the adnexa followed by cystectomy or cyst aspiration is the management of choice. [21]

In a retrospective study conducted by Aziz D. et al. and Ziv Tsafir et al. [22, 23, 24] to compare the results of conservative surgery and oophorectomy in the management of ovarian torsion, it was determined that detorsion should be the preferred treatment for the majority of cases of ovarian torsion in children. The best course of treatment for ovarian torsion in premenarchal children is specifically detorsion, followed by cystectomy and orchepexia. In our instance, a premenstrual girl underwent surgery for a right ovarian torsion with an oophorectomy after undergoing a detorsion oophoropexy left ovary for recurrence prevention.

Torsion is most frequently seen in the first trimester of pregnancy, but laparoscopic conservative therapy of torsion has been documented [25].

However, the increased hazards should not be understated, especially when preventing uterine damage during the first port insertion, and consequences like pneumonia and fetal death have been documented [26]. The patient in our situation experienced sporadic and intermittent pain. The diagnosis was confirmed by ultrasound and CT scan, however we removed the ovary to rule any recurrence (orchepexy at age 16) and a necrotic pattern on the left ovary.

Conclusion

Several articles have previously discussed conservative management of ovarian torsion. The care of suspected ovarian torsion, which can happen at any age, from prepubertal to postmenopausal, is surgical, according to Novak's textbook of gynecology [27]. According to earlier research, ovarian torsion necessitates oophorectomy because untwisting the ovarian pedicle could result in emboli. Recent research has suggested that detorsion combined with ovarian cystectomy should be the first line of treatment. If a cyst is present, normal ovarian function often follows, even in ovaries that do not first appear to be viable. This management is crucial for young ladies and prepubescent girls. Oophorectomy might be useful for avoiding recurrent torsion. [28]. [29].

References

- Ashwal E., Krissi H., Hirsch L., Less S., Eitan R., Peled Y. Presentation, diagnosis, and treatment of ovarian torsion in premenarchal girls. *J Pediatr Adolesc Gynecol.* 2015; 28: 526-529
- Nur Azurah A.G., Zainol Z.W., Lim A.A., Zainuddin P.S., Sulaiman A.S., Ng B.K., Update on the management of ovarian torsion in children and adolescents. *World J Pediatr.* 2014; 11: 35-40
- Dasgupta R., Renaud E., Goldin A.B. et al. Ovarian torsion in pediatric and adolescent patients: A systematic review. *J of Ped Surg.* 2018; 53: 1387-1391
- Ashwal E, Hirsch L, Krissi H, et al. Characteristics and management of ovarian torsion in premenarchal compared with postmenarchal patients. *Obstet Gynecol.* 2015;126(3):514-20.
- Sintim-Damoa A, Majmudar AS, Cohen HL, et al. Pediatric ovarian torsion: spectrum of imaging findings. *Radiographics.* 2017;37(6):1892-1908..
- Skappak C, Thurston JL, Kam AJ. Ovarian torsion in a pediatric patient: the importance of repeat imaging. *Pediatr Emerg Care.* 2019;35(8):e154-5
- American College of Obstetrics and Gynecologists' Committee on Adolescent Health Care. *Adnexal Torsion in Adolescents.* 2019. Available at: <https://www.acog.org/clinical/clinical-guidance/committee-opinion/articles/2019/08/adnexal-torsion-in-adolescents>. Accessed June 22, 2020..
- Bronstein ME, Pandya S, Snyder CW, et al. A meta-analysis of B-mode ultrasound, Doppler ultrasound, and computed tomography to diagnose pediatric ovarian torsion. *Eur J Pediatr Surg.* 2015;25(1):82-6.
- Huang C, Hong MK, Ding DC (2017) A review of ovarian torsion. *Tzu Chi Medical Journal* 29(3):143-147
- HayaseNittaTadatsuguKinjoYoshinoKinjyoHisakoYamadaHito shiMasamotoYoichiAoki Fetal ovarian cyst with prenatal torsion of the pedicle diagnosed in the third trimester: A case report *Case Reports in Women's Health* Volume 36, October 20.
- Ryan MF, Desai BK. Ovarian torsion in a 5-Year old: a case report and review. *Case reports in emergency medicine.* 2012; 2012 (5): 679121.
- Poonai N, Poonai C, Lim R, Lynch T. Pediatric ovarian torsion: case series and review of the literature. *Can J Surg.* 2013; 56 (2): 103-8
- White M, Stella J. Ovarian torsion: 10-year perspective. *Emerg Med Australas.* 2005;17:231-7
- Sahlu Z, Negash S, Yusuf L. Adnexal torsion a five years retrospective review in two hospitals. *Ethiop Med J.* 2014; 52 (4): 155-64.
- Yousefi Z, Farazestanian M, Mottaghi M, Pourmoghadam N. Ovarian torsion in postmenopausal women and risk of malignancy. *Journal of midwifery and reproductive health.* 2015; 3 (4): 479-82.
- Melcer Y, Sarig-Meth T, Maymon R, Pansky M, Vaknin Z, Smorgick N. Similar but different: a comparison of adnexal torsion in pediatric, adolescent, and pregnant and reproductive-age women. *J Womens Health (Larchmt).* 2016; 25 (4): 391-6.
- Shadinger LL, Andreotti RF, Kurian RL. Preoperative sonographic and clinical characteristics as predictors of ovarian torsion. *J Ultrasound Med.* 2008; 27: 7-13.
- Liangcheng Wang,Emi Shimizu,Taro Ikeda,Aya Ishiguro,Yuko Irie,Hiro Yoshi Ko,Isao Horiuchi,Kenro Chikazawa, Ken Imai,Tomoyuki Kuwata,Kenjiro Takag Huge fetal ovarian cyst 2020 - Wiley Online Library
- HayaseNittaTadatsuguKinjoYoshinoKinjyoHisakoYamadaHito shiMasamotoYoichiAoki Fetal ovarian cyst with prenatal torsion of the pedicle diagnosed in the third trimester: A case report *Case Reports in Women's Health* Volume 36, October 20.
- Ci Huang, Mun-Kun Hong, and Dah-Ching Ding A review of ovary torsion *Tzu Chi Med J.* 2017 Jul-Sep; 29(3): 143-147. doi: 10.4103/tcmj.tcmj_55_17
- Yildiz A, Erginel B, Akin M, et al. A retrospective review of the adnexal outcome after detorsion in premenarchal girls. *Afr J Paediatr Surg* 2014; 11: 304-7.
- Aziz D, Davis V, Allen L, Langer JC. Ovarian torsion in children: is oophorectomy necessary? *J Pediatr Surg.* 2004; 39 (5): 750-3.
- Shezaf B, Ohana E, Weintraub AY. "Habitual adnexal torsions"—recurrence after two oophorectomies in a prepubertal girl: a case report and review of the literature. *J Pediatr Adolesc Gynecol* 2013; 26: e81-4. 4.
- Tsafir Z, Foad Azem, Hasson J, Solomon E, Almog B, Nagar H, et al. Risk factors, symptoms, and treatment of ovarian torsion in children: the twelve year experience of one center. *J Minimal Invasive Gynaecol.* 2012; 19: 29-33.
- Lasso Betancor CE, Garrido Pérez JI, Murcia Pascual FJ, Granero Cendón R, Vargas Cruz V, Paredes Esteban RM. Ovarian torsion: long-term follow-up of the black-bluish ovary after laparoscopic detorsion. *Cir Pediatr.* 2014; 27 (1): 26-30.
- Bassil S, Steinhart U, Donnez J (1999) Successful laparoscopic management of adnexal torsion during week 25 of a twin pregnancy. *Hum Reprod* 14 (3): 855-857.
- Friedman JD, Ramsey PS, Ramin KD, Berry C (2002) Pneumoamnion and pregnancy loss after second trimester laparoscopic surgery. *Obstet Gynecol* 99: 512-513.
- Novak's Gynecology 2002, 13th Edition. In: Berek JS (ed) Published by Lippincott, Williams and Wilkins, Page 397.
- Gelbaya TA, Nardo LG, Fitzgerald CT, Horne G, Brison DR, Lieberman BA (2006) Ovarian response to gonadotrophins after laparoscopic salpingectomy or the division of fallopian tubes for hydrosalpinges. *Fertil Steril* 85 (5): 1464-1468.



This work is licensed under Creative Commons Attribution 4.0 License

To Submit Your Article Click Here:

Submit Manuscript

DOI: [10.31579/2642-9756/134](https://doi.org/10.31579/2642-9756/134)

Ready to submit your research? Choose Auctores and benefit from:

- fast, convenient online submission
- rigorous peer review by experienced research in your field
- rapid publication on acceptance
- authors retain copyrights
- unique DOI for all articles
- immediate, unrestricted online access

At Auctores, research is always in progress.

Learn more <https://www.auctoresonline.org/journals/women-health-care-and-issues>