

# Delayed Subarachnoid Hemorrhage in A Patient on Warfarin with Blunt Head Trauma

Douglas Rappaport\*, Kartik Mangipudi, Thomas M. Polveroni, Wayne Martini

Department of Emergency Medicine, Mayo Clinic Arizona, Phoenix, AZ, USA

\*Corresponding Author: Douglas Rappaport. Department of Emergency Medicine, Mayo Clinic Arizona, Phoenix, AZ, USA.

Received date: October 27, 2022; Accepted date: November 10, 2022; Published date: November 23, 2022.

Citation: Douglas Rappaport, Kartik Mangipudi, Thomas M. Polveroni, Wayne Martini. (2022). Delayed Subarachnoid Hemorrhage in A Patient on Warfarin with Blunt Head Trauma, J. Journal of Clinical Research and Reports, 12(2) DOI: [10.31579/2690-1919/280](https://doi.org/10.31579/2690-1919/280)

Copyright: © 2022 Douglas Rappaport. This is an open-access article distributed under the terms of The Creative Commons Attribution License, which permits unrestricted use, distribution, and reproduction in any medium, provided the original author and source are credited.

## Abstract:

Closed head trauma in anticoagulated patients is an increasing common presentation to Emergency Department (ED). Within this population, there is a subset of patients who present with delayed intracranial haemorrhage, typically resulting in subdural or parenchymal bleeds, with negative initial non-contrast head CT.

**Keywords:** subarachnoid hemorrhage; blunt head trauma; emergency department

## Introduction:

Closed head trauma in anticoagulated patients is an increasing common presentation to Emergency Department (ED).[1] Within this population, there is a subset of patients who present with delayed intracranial haemorrhage, typically resulting in subdural or parenchymal bleeds, with negative initial non-contrast head CT. [1,2,3] This paper presents a rare case of delayed traumatic pontine perimesencephalic sub-arachnoid haemorrhage in a patient on warfarin.

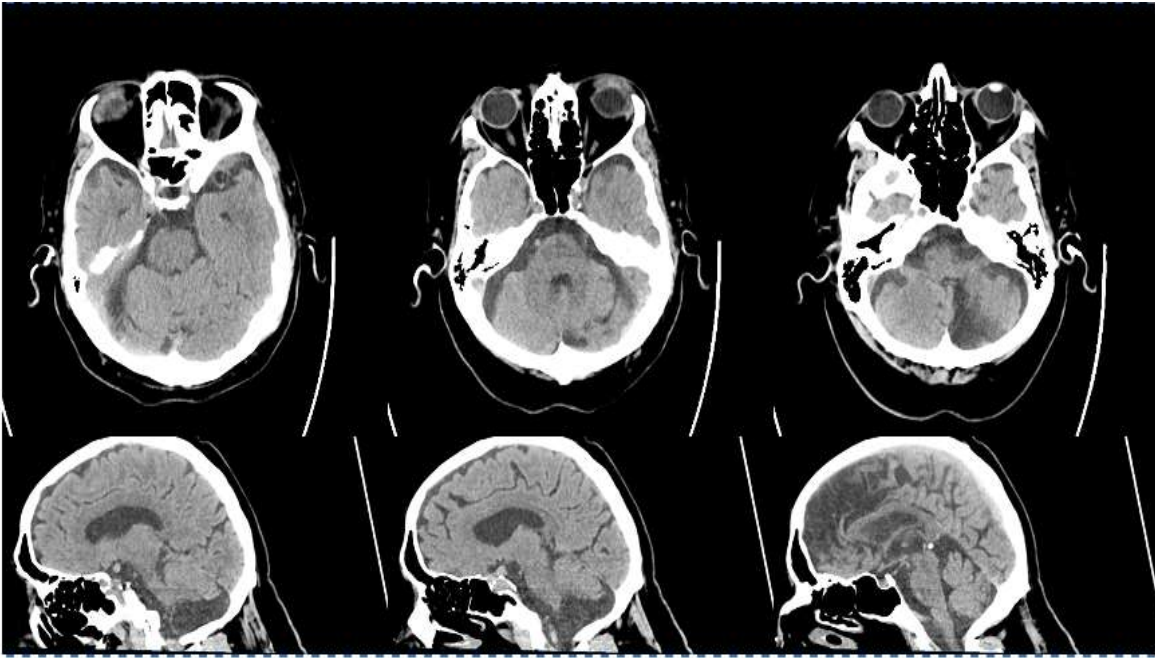
## Case Description:

A 76-year-old gentleman on therapeutic warfarin for atrial fibrillation presented to the ED following a witnessed ground level fall with trauma to the occiput. Initial non-contrast head CT performed within 6 hours of initial injury was negative for any acute pathology, and the patient was subsequently discharged home from the ED. The patient had a progressively worsening headache and represented with new focal neurological deficits including polycranial neuropathy, 3 days after onset

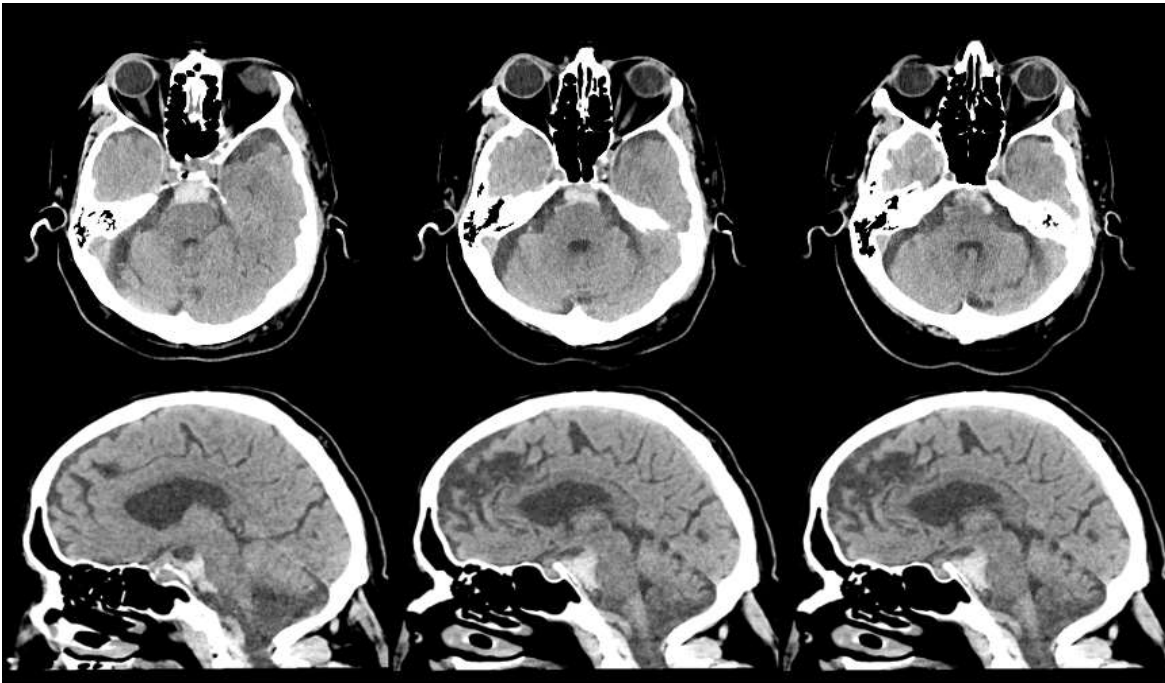
of trauma. Repeat non-contrast CT scan was notable for a pontine perimesencephalic subarachnoid haemorrhage with no evidence of aneurysm on cerebral angiogram.

## Discussion:

There is variability in opinion with regard to optimal management of anticoagulated patients who sustain closed head trauma with initial negative non-contrast head CT. [4,5] It is well documented in the literature that a small fraction of these patients develops delayed intracranial haemorrhage with some requiring Neurosurgical intervention. [2,3,4] There is minimal literature documenting delayed traumatic sub-arachnoid haemorrhages, making this case unique. Based on this case, we advocate for consideration of limited MRI scan in high risk patients with suspected posterior fossa pathology and or extended periods of observation and provider follow up within 24 hours to assess need for repeat imaging.[5,6,7] Certainly more research is required in this area to illuminate new management options.



**Figure 1:** Non-contrast CT head axial and sagittal views upon first presentation to the Emergency Department demonstrating no evidence of parenchymal or extra-axial haemorrhage



**Figure 2:** Non-Contrast CT head axial and sagittal views upon second presentation to the Emergency Department 3 days after head trauma demonstrating new perimesencephalic pontine sub-arachnoid haemorrhage with trace intraventricular extension

### References:

1. Mason S, Evans R, Kuczawski M. (2018) Understanding the management of patients with head injury taking warfarin: who should we scan and when? Lessons from the AHEAD study. *Emergency Medicine Journal*. emermed-2018-207621.
2. Peck K, Sise C, Shackford S et al. (2011) Delayed Intracranial Hemorrhage After Blunt Trauma: Are Patients on Preinjury Anticoagulants and Prescription Antiplatelet Agents at Risk?. *The Journal of Trauma: Injury, Infection, and Critical Care*. 71(6):1600-1604.
3. Nishijima D, Offerman S, Ballard D et al. (2012) Immediate and Delayed Traumatic Intracranial Hemorrhage in Patients With Head Trauma and Preinjury Warfarin or Clopidogrel Use. *Ann Emerg Med*. 59(6):460-468.e7.
4. Kaen A, Jimenez-Roldan L, Arrese I et al. (2009) The Value of Sequential Computed Tomography Scanning in Anticoagulated

- Patients Suffering From Minor Head Injury. *The Journal of Trauma: Injury, Infection, and Critical Care*. 1.
5. Menditto V, Lucci M, Polonara S, Pomponio G, Gabrielli A. (2012) Management of Minor Head Injury in Patients Receiving Oral Anticoagulant Therapy: A Prospective Study of a 24-Hour Observation Protocol. *Ann Emerg Med*. 59(6):451-455.
  6. Li J. (2012) Admit All Anticoagulated Head-Injured Patients? A Million Dollars Versus Your Dime. You Make the Call. *Ann Emerg Med*. 59(6):457-459.
  7. Gentry L, Godersky J, Thompson B, Dunn V. (1988) Prospective comparative study of intermediate-field MR and CT in the evaluation of closed head trauma. *American Journal of Roentgenology*. 150(3):673-682.



This work is licensed under Creative Commons Attribution 4.0 License

To Submit Your Article Click Here:

**Submit Manuscript**

DOI: [10.31579/2690-1919/280](https://doi.org/10.31579/2690-1919/280)

**Ready to submit your research? Choose Auctores and benefit from:**

- fast, convenient online submission
- rigorous peer review by experienced research in your field
- rapid publication on acceptance
- authors retain copyrights
- unique DOI for all articles
- immediate, unrestricted online access

At Auctores, research is always in progress.

Learn more <https://auctoresonline.org/journals/journal-of-clinical-research-and-reports>