

Relationship Between COVID-19 Virus, RAS System and Dysarthria: A Single Case Report

Nayana Narayanan ^{1*}, Abhisha S. B Baslp ²

¹Assistant Professor Department of Audiology and Speech Language Pathology, AWH Special College, Calicut – 673003 Kerala University of Health sciences.

²Department of Audiology and Speech Language Pathology, AWH Special College, Calicut-673003 Kerala University of Health sciences

*Corresponding Author: Nayana Narayanan, AWH Special College Kallai Calicut Kerala – 673003.

Received Date: September 14, 2022; Accepted Date: September 30, 2022; Published Date: October 10, 2022

Citation: Nayana Narayanan, Abhisha S. B Baslp. (2022). Relationship Between COVID-19 Virus, RAS System and Dysarthria: A Single Case Report. *J. Clinical Cardiology and Cardiovascular Interventions*, 5(9); DOI:10.31579/2641-0419/279

Copyright: © 2022 Nayana Narayanan, This is an open-access article distributed under the terms of the Creative Commons Attribution License, which permits unrestricted use, distribution, and reproduction in any medium, provided the original author and source are credited.

Abstract

The seventh human coronavirus, severe acute respiratory syndrome coronavirus 2 (SARS-CoV-2), was detected in Wuhan, China, during a recent pneumonia outbreak in January 2020. The virus has since spread all across the world. Fever, fatigue, and respiratory problems, which can progress to pneumonia, are some of the symptoms. Symptoms usually emerge between 2 and 14 days.

Keywords: Electroglottography; COVID-19

Introduction

The seventh human coronavirus, severe acute respiratory syndrome coronavirus 2 (SARS-CoV-2), was detected in Wuhan, China, during a recent pneumonia outbreak in January 2020. The virus has since spread all across the world. Fever, fatigue, and respiratory problems, which can progress to pneumonia, are some of the symptoms. Symptoms usually emerge between 2 and 14 days.

Since being exposed to said virus, patients develop new, persistent or recurrent chronic health problems known as post-COVID diseases. Even Patients who did not suffer COVID-19 symptoms in the days or weeks following their infection may also develop post-covid issues. These conditions, also known as Long Covid, long-haul covid, post-acute COVID-19, might manifest themselves as various combinations of health issues throughout days or weeks. Long term complications of these conditions include issues of cardiovascular system, respiratory system, neurologic system, psychiatric conditions etc.

Dysarthria is one of the reported post COVID condition. ASHA refers to Dysarthria as “ a group of neurogenic speech disorders characterized by "abnormalities in the strength, speed, range, steadiness, tone, or accuracy of movements required for breathing, phonatory, resonatory, articulatory, or prosodic aspects of speech production" (Duffy, 2013). These abnormalities are due to one or more sensorimotor problems—including weakness or paralysis, incoordination, involuntary movements, or excessive, reduced, or variable muscle tone (Duffy, 2013).

Typically dysarthria is caused due to any pathophysiological alterations in the nervous system like cerebrovascular incidents, neural infection, and degenerative conditions etc. Dysarthria following COVID-19 infection is predominantly caused either due to stroke (Mahboob et.al,2020; Bhagat et.al, 2020; Beyrouti et.al,2020) or due to infections of nervous systems like meningitis and encephalitis (Mukherji et.al, 2021; Huo et.al, 2021; Katal, Balakrishnan, & Gholamrezanezhad, 2021). However, very rarely COVID-19 virus by itself directly damages the speech musculature thus causing dysarthria. Even though some authors have reported skeletal muscle pain and weakness in cases post COVID-19 (Ali, & Kunugi, 2021; Silva et.al, 2021), it is seldom reflected in the speech and language functions. In this report, we present such a case that did not have marked motoric weakness but had significant dysarthric component post COVID.

Objectives

- Report the in depth evaluation of case with Dysarthria Post COVID-19 infection
- Detail the relationship between post-COVID condition and dysarthria.

Method

A 52-year-old male with a history of COVID-19 came to our department after 8 months of post-infection. The client reported progressive slurring of speech, left-sided tongue deviations, and swallowing difficulty following

COVID-19 infection. The client underwent objective as well as subjective evaluation for all the speech and language parameters.

Screening MRI of brain was done followed by nerve conduction study. The client underwent detailed subjective evaluation of all the speech subsystem during which each speech subsystems namely; respiratory, phonatory, articulatory, resonatory and prosodic, were assessed using various task. Respiratory subsystem was assessed by observing the client’s breathing at rest as well as during speech. To assess the patient’s respiration, he was instructed to take a deep breath in via the mouth and let it out slowly. The patient was instructed to count to 20 as rapidly as possible on one breath to assess respiration in speech. During this the client’s breathing pattern, effort, capacity etc during expiration and inspiration was recorded. Phonatory subsystem was assessed by asking the client to produce /a/, /i/, /u/ sound at length as well as during conversation with the client. The duration to which the client can prolong the vowel is jotted together with the pitch, loudness and quality of client’s voice. Pitch and loudness scaling was carried out to assess pitch and loudness range. The first task for assessing articulatory subsystem included conversing with the client while the second task included picture/topic description. During the course of these tasks, the errors in production of various consonant and vowel sounds are recorded with comment on overall intelligibility of speech. Resonatory system was assessed by asking the client to produce /mae/ and /pae/ alternatively. The perceptible difference between both the sounds was scrutinized. Also, the nasality during phonation of /a/ was noted. Prosodic system assessment included the reading of contrastive stress words and informal assessment of rhythm and intonation during various conversation instances (questions, narratives, statements etc)

Objective evaluation conducted included Dr. Speech (Tiger DRS, Inc) for phonatory-respiratory system, Electrolottography (Tiger DRS, Inc) for phonatory system. Fundamental frequency, jitter, shimmer, amplitude tremor, of the sounds /a/, /e/ and /u/ were recorded using Dr Speech software. Frenchay Dysarthria Assessment (Enderby & Palmer, 2008) was administered for rating the overall severity of dysarthria.

Dysphagia evaluation was carried out subjectively. The client was asked whether he cough or choke while eating. He was also asked whether he had difficulty in clearing throat following which the client was observed while drinking ½ cup of cold water and then while eating a cookie. The client was questioned whether he had any difficulties swallowing, eating quickly, or having limits on the sorts of things he could consume.

Oromotor examination was carried out subjectively to chart the weakness at the level of articulators. Structural abnormality of lips at rest was observed. The patient was asked to give an exaggerated smile to check lip spreading. Lip seal was assessed by blowing air into cheeks and by maintain for 15seconds. And then the patient was asked to say /P/...../P/ crisply and clearly for 10 times. Lips articulatory movements were tested by repeating “oo ee” for 10 segments in 10 seconds. The movements of lips in conversation were observed. Palatal maintenance was assessed by asking the patient to say-“ah-ah-ah” for. Tongue at rest was assessed by asking the patient to open his mouth. Tongue functions like protrusion, elevation, lateral movements were assessed. Alternate movements of tongue were assessed by asking the patient to say “ka la” for 10 times as quickly as possible. Intelligibility of words was also assessed.

Results

Table 1 reveals the objective evaluation done and their respective results. The client’s imaging reports reveal Mild diffuse neuroparenchymal atrophy. Nerve conduction study report shows, Axonal motor neuropathy involving bilateral peroneal nerves. Electrolottography results show normal glottal wave morphology with all the quotients within normal limits, however, voice evaluation through Dr Speech reveals hoarse voice with predominantly breathy voice quality. Results of the standardized test, Frenchay Dysarthria Assessment (Enderby & Palmer,2008), used to evaluate severity of dysarthria reveals mild dysarthria.

Objective evaluation	Impression	
Nerve conduction study	Predominantly dominant axonal motor neuropathy involving bilateral peroneal nerves	
MRI	Flair hyperintensities noted in bilateral frontoparietal white matter.	
EGG	Mild to moderately deviated vocal fold morphology with mild hypoadduction	
Dr. Speech	Hoarse voice with predominantly breathy voice quality	
Frenchay Dysarthria Assessment (FDA)	Reflex	Mildly affected
	Respiration	Mildly affected
	Lips	Normal
	Palate	Maintenance is mildly affected
	Laryngeal	Time & pitch moderately affected
	Tongue	Severely affected
	Intelligibility	Moderately affected

Table 1

The results of Dr. Speech and EGG are depicted in table 2 and table 3 respectively. Correspondingly, the voice quality and glottal wave pattern obtained from each is represented as figure 1 and 2. The Dr. Speech values

depicts the client to be having moderate hoarse voice as EGG results reveal the glottal wave to be mildly affected with normal quotients.

	/a/	/i/	/u/
Habitual F0 (Hz)	118.15	121.67	127.47
Jitter (%)	0.43	0.94	0.23
Shimmer (%)	5.12*	1.82	1.72
F0 Tremor (Hz)	2.00*	12.25*	6.39*
Mean F0 (Hz)	117.99	122.48	127.78
SD F0 (Hz)	1.36	1.94	0.79
Max. F0 (Hz)	120.49	128.20	129.33
Min. F0 (Hz)	114.25	119.19	126.36
NNE (dB)	-1.85	-6.46	-0.63
HNR (dB)	14.78*	15.26*	27.12
SNR (dB)	13.94*	14.22*	26.04
Amp. Tremor (Hz)	1.47	3.40	1.25
Ratio (%)	30.00	55.00	20.00

Table 2: Voice Data

Note: This table depicts the acoustic analysis of voice of client. The acoustic correlates of pitch, intensity and quality is analyzed through the instrument Dr Speech. The values depict the results of the analysis. The parameters analyzed include F0: Fundamental Frequency, Jitter: cycle to cycle variation in frequency, Shimmer: cycle to cycle variation in intensity, SD: standard deviation, NNE: Normalized noise energy, HNR: Harmonic to Noise ratio, SNR: Signal to Noise energy, Amp: Amplitude.

* Values are not within normal limits

Parameter	Result
CQ (%)	33.40
CI	-0.33
OR (%)	66.59
CR (%)	33.31
CQP (%)	6.35
CIP (%)	13.75

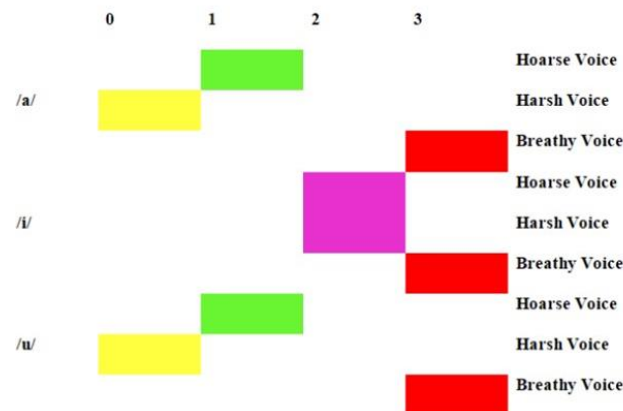
Table 3: EGG Evaluation Data

Note: The table shows the results of electroglottography (EGG) done on the patient. EGG represents the glottal wave during phonation of vowels. The parameters analyzed using EGG include CQ: Contact quotient, CI: Contact Index, OR: Open ratio, CR; Close ratio, CQP: Contact quotient percentage, CIP: Contact index percentage

All the parameters are within normal limits.

Fig 1:

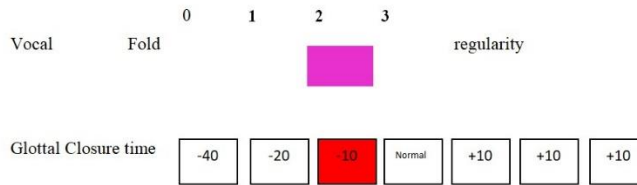
Voice quality estimates



Note: Figure shows the acoustic quality of the vowel /a/, /i/ and /u/. The qualities include normal, hoarse, harsh and breathy and is rated on a 4 points scales with 0 as normal and 3 as severe. The results show that client has severe breathiness during the production of all the three vowels.

Figure 2

Vocal wave regularity



Note: The figure shows the rating on regularity of glottal wave as obtained from EGG instrument. The morphology of wave is rated on 4 point scale with 0 as normal and 3 as severely deviated. According to the figure there is mild to moderate irregularity of glottal wave with mild hypoadduction of vocal fold in our client.

OPME evaluation; all articulators were structurally and functionally normal except for tongue and lips. Lips are structurally normal but the rate of motion is reduced. Tongue is Symmetrical at rest, and atrophy is present at center portion. Fasciculation / fibrillations is also evident with mild limitation in range and rate of motion.

Detailed evaluation of all the speech subsystem is shown in Table 4. As shown in the Table 4, Results of subjective evaluation of all subsystems of speech with swallowing assessment convey the patient to be mildly dysarthric.

SUBJECTIVE EVALUATION		RESULTS
Evaluation of subsystem	Articulation	Distorted lingual sounds with reduced intelligibility of speech
	Phonation	/a:/- 6.05s /i:/- 5.98s /u:/- 5.77s s/z- 0.77s
	Respiration	Abdominal breathing present with inadequate respiratory support
	Resonation	Hyponasal sound with reduced nasal emission.
	Prosody	Inadequate stress
Swallowing Assessment		Chewing difficulty for solids and occasionally choking is observed after drinking liquids. Signs of aspiration present.

Table 4: Impressions of Subjective Evaluation

Discussion

Through an in depth evaluation, our client was provisionally diagnosed with mild Dysarthria. The client possessed weakness in the speech musculature. Surprisingly, the weakness commenced after the recovery from COVID-19 infection. However, the client did not have any conventional positive aetiology for his dysarthric component albeit having hypertension. The hypertension as well originated as a post COVID-19 condition. The diffuse parenchymal atrophy reported in the imaging can be attributed to age related neurophysiological alterations. It cannot account for the speech deficits portrayed by the client, as it developed acutely post COVID-19 as opposed to progressive slurring typically reported in age-related speech deteriorations. Furthermore, the peroneal neuropathy reported in the client, would not directly affect speech. Hence, considering all of these facts, we can establish that hypertension was the direct cause of dysarthria. Even though hypertension has been a long-established risk factor for Dysarthria by virtue of its role in cardiovascular incidences, it in itself is rarely considered as the causative agent. Our case report substantiate the finding

that hypertension alone can lead to weakness in muscles thereby leading to dysarthria.

The pathophysiology behind these sequelae can stem from the degrading effect of hypertension on the body. As most of the muscles involved in speech are highly vascular in nature, they are immensely vulnerable to the adverse effect of hypertension. The prolonged contraction in these muscles as a response to increased blood pressure can bring about generalized soreness in them, which would result in overall fatigue with mild dysarthric speech. Another major reason that dominates the previous could be that COVID-19 virus interacts with the Angiotensin Converting Enzyme and Angiotensin receptors located in the endothelium thereby altering the pathophysiological functioning of Renin-Angiotensin system (RAS) that regulates the blood pressure. (Wiese, et al., 2020; South et.al, 2020; Amraei & Rahimi, 2020; Lanza et.al, 2020). The altered neurochemical changes in RAS system can bring about atrophy and weakness of muscles, as the RAS axis catalyses major functions like contractile activity and damage control through the regulation of sodium balance, fluids volume, and some other

hemodynamic features, of the muscles. (Sukhanov et.al, 2011; Cabello-Verrugio, et al., 2012; Cabello-Verrugio et.al., 2015). These alterations in the physicality of muscles, could be reflected in diminished functions of the speech subsystems too, because of its motoric nature.

Adding onto this, is the age related changes occurring in the neuromotor system. As age progress the muscles tends to show morphological changes like loss of fibre, loss of mass, reduced tonicity etc. with functional difficulties including reduced rate and range of movement. (Larsson, et al., 1979; Lindle et al., 1997; Jakobi & Rice, 2002; Wilkinson, et al., 2018). As our client is just beginning the fifth decade of his life, these degenerations would not have been severe. Nevertheless, as the neuromotor compensatory skills lessen with increasing age, the COVID-19 infection attack would have made the motoric system more vulnerable, henceforth adding to the already existing weakness.

Hence, compiling all the points of discussion we can effectively point out COVID-19 and post COVID hypertension as causative agent of dysarthria in our client.

Conclusion

Apart from the debilitating and life threatening results of COVID-19 infection, it can also cause secondary conditions like Hypertension, Dysarthria etc. through alteration of systems like RAS. This can hinder the quality of life in the infected patient post recovery. Therefore, it is necessary for us to understand and report these effects and help in rehabilitating these conditions with success.

Ethical Consideration

The study followed the ethical rules and regulation of Kerala University of Health Sciences and was accepted by ethical committee of AWH Special College, Kozhikode. The client was informed and consent was obtained. The study was conducted by maintain proper respect and anonymity towards the client.

Acknowledgement

We wish to thank our Principal Dr P K Abdul Kader and our Head of the Department Mrs. Girija P C for allowing us to conduct this study. We also appreciate the support of staff and students of AWH Special College that helped us to achieve the completion of this study.

Conflict of Interest

There is no conflict of interest between the authors and the authors as well the client.

Reference

1. Ali, A. M., & Kunugi, H. (2021). Skeletal muscle damage in COVID-19: a call for action. *Medicina*, 57(4), 372.
2. Amraei, R., & Rahimi, N. (2020). COVID-19, Renin-Angiotensin System and Endothelial Dysfunction. *Cells*, 9(7), 1652. MDPI AG. <http://dx.doi.org/10.3390/cells9071652>
3. Beyrouti, R., Adams, M. E., Benjamin, L., Cohen, H., Farmer, S. F., Goh, Y. Y., ... & Werring, D. J. (2020). Characteristics of ischaemic stroke associated with COVID-19. *Journal of Neurology, Neurosurgery & Psychiatry*, 91(8), 889-891.
4. Bhagat, S., Yadav, N., Shah, J., Dave, H., Swaraj, S., Tripathi, S., & Singh, S. (2020). Novel corona virus (COVID-19) pandemic: current status and possible strategies for detection and treatment of the disease. *Expert Review of Anti-infective Therapy*, 1-24.
5. Cabello-Verrugio, Claudio & Morales, Maria & Rivera, Juan & Cabrera, Daniel & Simon, Felipe. (2015). Renin-Angiotensin System: An Old Player with Novel Functions in Skeletal Muscle. <https://doi.org/10.1002/med.21343>
6. Cabello-Verrugio, C., Córdova, G., & Salas, J. D. (2012). Angiotensin II: Role in skeletal muscle atrophy. *Current Protein and Peptide Science*, 13(6), 560-569. <https://doi.org/10.2174/138920312803582933>
7. Duffy, J. R. (2019). *Motor speech disorders e-book: Substrates, differential diagnosis, and management*. Elsevier Health Sciences.
8. Enderby, P. M., & Palmer, R. (2008). *Frenchay dysarthria assessment*. Pro-ed.
9. Huo, L., Xu, K. L., & Wang, H. (2021). Clinical features of SARS-CoV-2-associated encephalitis and meningitis amid COVID-19 pandemic. *World Journal of Clinical Cases*, 9(5), 1058.
10. Jakobi, J. M., & Rice, C. L. (2002). Voluntary muscle activation varies with age and muscle group. *Journal of applied physiology*, 93(2), 457-462.
11. Katal, S., Balakrishnan, S., & Gholamrezanezhad, A. (2021). Neuroimaging and neurologic findings in COVID-19 and other coronavirus infections: a systematic review in 116 patients. *Journal of Neuroradiology*, 48(1), 43-50.
12. Lanza, K., Perez, L. G., Costa, L. B., Cordeiro, T. M., Palmeira, V. A., Ribeiro, V. T., & Simões e Silva, A. C. (2020). Covid-19: the renin-angiotensin system imbalance hypothesis. *Clinical Science*, 134(11), 1259-1264.
13. Larsson L, Grimby G, Karlsson J. Muscle strength and speed of movement in relation to age and muscle morphology. *J Appl Physiol Respir Environ Exerc Physiol*. 1979 Mar;46(3):451-6. doi: 10.1152/jappl.1979.46.3.451. PMID: 438011.
14. Lindle RS, Metter EJ, Lynch NA, Fleg JL, Fozard JL, Tobin J, Roy TA, Hurley BF. Age and gender comparisons of muscle strength in 654 women and men aged 20-93 yr. *J Appl Physiol* (1985). 1997 Nov;83(5):1581-7. doi:
15. Mahboob, S., Boppana, S. H., Rose, N. B., Beutler, B. D., & Tabaac, B. J. (2020). Large vessel stroke and COVID-19: case report and literature review. *Eneurologicalsci*, 20, 100250.
16. Mukerji, Shibani S., and Isaac H. Solomon. "What can we learn from brain autopsies in COVID-19?" *Neuroscience letters* 742 (2021): 135528.
17. Silva, R. N., Goulart, C. D. L., Oliveira, M. R., Tacao, G. Y., Back, G. D., Severin, R., ... & Borghi-Silva, A. (2021). Cardiorespiratory and skeletal muscle damage due to COVID-19: making the urgent case for rehabilitation. *Expert review of respiratory medicine*, 15(9), 1107-1120.
18. South, A. M., Diz, D. I., & Chappell, M. C. (2020). COVID-19, ACE2, and the cardiovascular consequences. *American Journal of Physiology-Heart and Circulatory Physiology*.
19. Sukhanov, S., Yoshida, T., Tabony, A. M., Higashi, Y., Galvez, S., Delafontaine, P., Semprun-Prieto, L.(2020). Angiotensin II, Oxidative Stress and Skeletal Muscle Wasting. *The American Journal of the Medical Sciences* 342(2), 143-147. <https://doi.org/10.1097/MAJ.0b013e318222e620>.
20. Wiese, O. J., Allwood, B. W., & Zemlin, A. E. (2020). COVID-19 and the renin-angiotensin system (RAS): A spark that sets the forest alight?. *Medical hypotheses*, 144, 110231.
21. Wilkinson, D. J., Piasecki, M., & Atherton, P. J. (2018). The age-related loss of skeletal muscle mass and function: Measurement

and physiology of muscle fibre atrophy and muscle fibre loss in humans. Ageing research reviews, 47, 123-132.

Appendix 1

FDA RATING FORM

Time										L Pharyngeal
Pitch										
Volume										
In Speech										Tongue
At rest										
Protrusion										
Elevation										
Lateral										
Alternate										Intelligibility
In speech										
Words										
Sentence										
Conversation										



This work is licensed under Creative Commons Attribution 4.0 License

To Submit Your Article Click Here:

Submit Manuscript

DOI: [10.31579/2641-0419/279](https://doi.org/10.31579/2641-0419/279)

Ready to submit your research? Choose Auctores and benefit from:

- fast, convenient online submission
- rigorous peer review by experienced research in your field
- rapid publication on acceptance
- authors retain copyrights
- unique DOI for all articles
- immediate, unrestricted online access

At Auctores, research is always in progress.

Learn more <https://auctoresonline.org/journals/clinical-cardiology-and-cardiovascular-interventions>